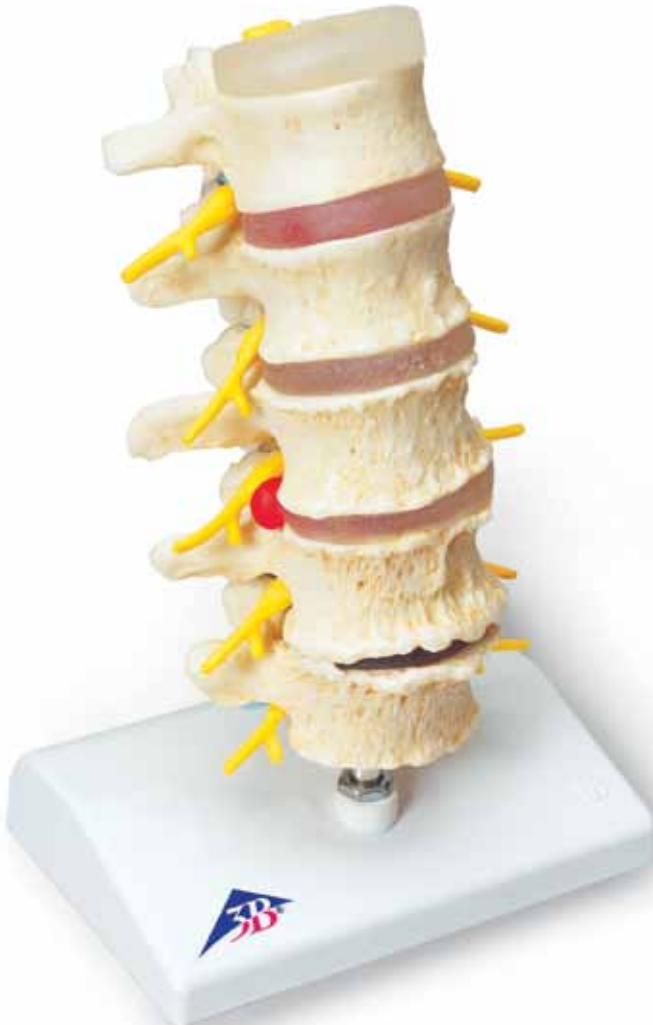



*...going one step further*




**A795**

(1000158)

**Latin**

- 1 Discus intervertebralis
- 2 Vertebra lumbalis I
- 3 Vertebra lumbalis II
- 4 Spondylophyt
- 5 Vertebra lumbalis III
- 6 Vertebra lumbalis IV
- 7 Vertebra lumbalis V
- 8 N. spinalis L5
- 9 N. spinalis L4
- 10 N. spinalis L3
- 11 N. spinalis L2
- 12 N. spinalis L1
- 13 Medulla spinalis
- 14 Articulatio zygapophysialis
- 15 Discus intervertebralis (salubris)
- 16 Protrusio disci
- 17 Prolapsus disci dorsomedialis
- 18 Prolapsus disci dorsolateralis
- 19 Chondrosis intervertebralis



# Stages of disc prolapse and vertebral degeneration

English

This model provides a very graphic comparative illustration of lumbar vertebrae with intervertebral discs in a healthy vs. a degenerated condition. Intervertebral disc degenerations are shown both in the form of protrusion and prolapse and of changes to the vertebra itself.

- 1 Intervertebral disc
- 2 Lumbar vertebra I
- 3 Lumbar vertebra II
- 4 Spondylophyte (bony outgrowth)
- 5 Lumbar vertebra III
- 6 Lumbar vertebra IV
- 7 Lumbar vertebra V
- 8 Spinal nerve L5
- 9 Spinal nerve L4
- 10 Spinal nerve L3
- 11 Spinal nerve L2
- 12 Spinal nerve L1
- 13 Spinal cord
- 14 Zygapophysial (facet) joint (between articular processes)
- 15 Healthy intervertebral disc
- 16 Disc protrusion
- 17 Dorso-medial disc prolapse (into the spinal canal)
- 18 Dorso-lateral disc prolapse
- 19 Degenerative intervertebral disc

