MG35590 | DIDACTIC FLEXIBLE HUMAN SPINE MODEL WITH FEMUR HEADS

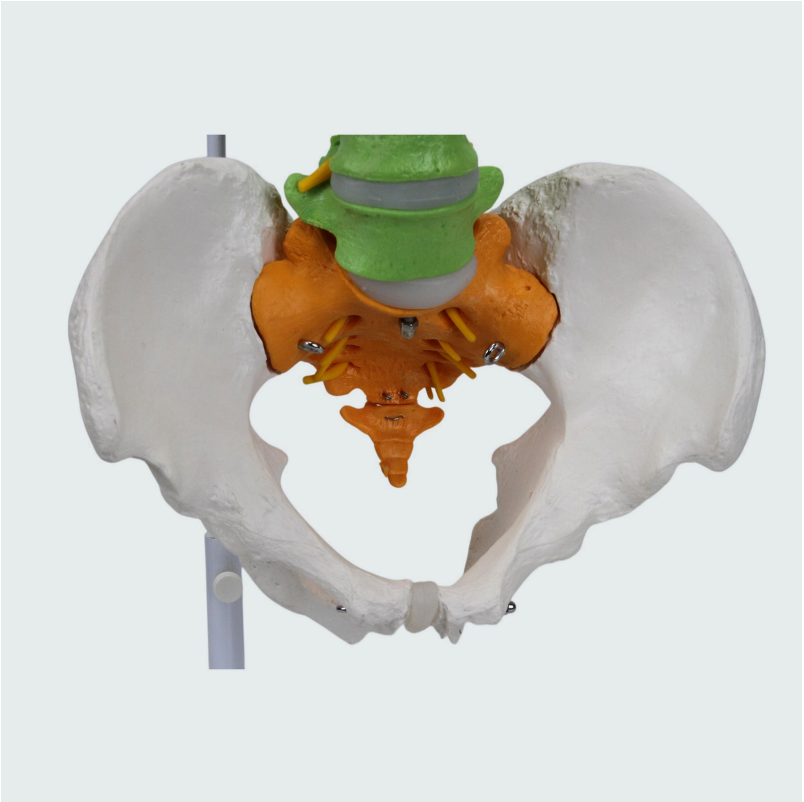

Nasco HEALTHCARE



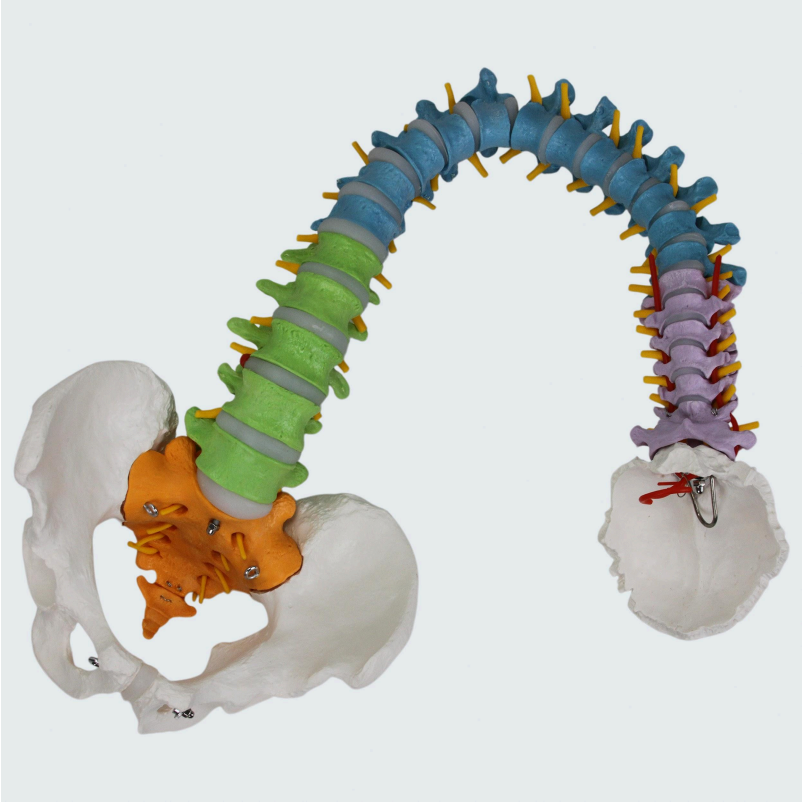



Nasco HEALTHCARE





Flexible Didactic Spine Column: a life-size anatomical model representing the complete vertebral column, including occipital plate, cervical, thoracic and lumbar regions, sacrum, coccyx and pelvis. It features vertebral arteries, spinal nerves and an L3-L4 intervertebral disc with prolapse (herniated disc). Vertebral regions are color-coded for easy identification. The model is mounted on a metal stand.

Applications:

* Study of human anatomy in schools and universities.
* Professional training.
* Patient explanations.
* Medical and scientific information.
* Study of the anatomy and flexibility of the vertebral column, highlighting important points of the human skeleton, muscles, joints and related diseases.

Technical Differentiators:

* Flexible, made with special materials that facilitate movement.
* Color coding to facilitate study and learning.
* High fidelity to anatomical details.
* Precise molding.
* Made of resistant synthetic material.
* Anatomical replicas.
* Flexible internal metal structure.
* Resin approved in toxicological tests.

3D Technology and Augmented Reality:

Our anatomical models offer a visual complement through informative cards that activate 3D models viewable in augmented reality (AR). This interactive platform stimulates learning, allowing comparative analysis of anatomical structures and offering resources for continuing education in anatomy, physiology and pathophysiology.

Technical Specifications:

* Scale: Life-size.
* Material: Synthetic resin.
* Includes metal stand and rod.

Main Structures:

occipital bone: Flat bone, located in the posterior and inferior part of the skull, forming the base of the skull. It articulates with the atlas (C1) and contributes to the protection of the brainstem.

atlas: First cervical vertebra (C1), characterized by the absence of a vertebral body and spinous process. It has a bony ring with lateral masses and articulates with the occipital bone and the axis (C2).

axis: Second cervical vertebra (C2), has a vertical bony process called the dens (odontoid process), which articulates with the atlas, allowing rotation of the head.

pubis: Paired bone, located in the anterior part of the pelvis, which forms the pubic symphysis. It contributes to the support of body weight and the protection of the pelvic organs.

pubic symphysis: Cartilaginous joint between the two pubic bones, allowing slight mobility during pregnancy and childbirth.

ischium: Paired bone, located in the inferior part of the pelvis, forming most of the acetabulum (hip joint cavity). It contributes to the support of body weight in a sitting position.

coccyx: Bone formed by the fusion of 3 to 5 rudimentary coccygeal vertebrae. It represents the vestige of the embryonic tail.

sacrum: Bone formed by the fusion of five sacral vertebrae. It articulates with the ilium (hip bone) and the coccyx. It forms the posterior part of the pelvis.

ilium: Paired bone, constituting most of the hip bone. Its superior, expanded portion forms the wing of the ilium. It articulates with the sacrum.

iliac crest: Thick superior border of the ilium, easily palpable on the surface of the pelvis. It serves as an anatomical landmark and muscle insertion point.

herniated disc: Protrusion of the nucleus pulposus (gelatinous inner part) of an intervertebral disc through the annulus fibrosus (fibrous outer part), compressing nerve roots or the spinal cord. In the model, it is represented in the L3-L4 disc.

intervertebral discs: Fibrocartilaginous structures located between the vertebral bodies,

acting as shock absorbers and allowing flexibility of the spine.

Other structures can be verified directly on the physical piece or on the interactive 3D model.

About the Anatomical Models:

They are developed with resin replication technology, meeting the need for anatomical pieces for teaching and research. They present the essential morphological characteristics with excellent cost-benefit, good resistance, hand painting and numbering for precise identification of structures.

List of all visible structures:

- occipital bone
- atlas
- axis
- pubis
- pubic symphysis
- ischium
- coccyx
- sacrum
- ilium
- iliac crest
- herniated disc
- intervertebral discs
- transverse processes
- spinal nerves
- median sacral crest
- lesser sciatic notch
- greater sciatic notch