MG22306 | DIDATIC HUMAN SKULL WITH MUSCLE SOURCES ON CERVICAL SPINE



Nasco
HEALTHCARE



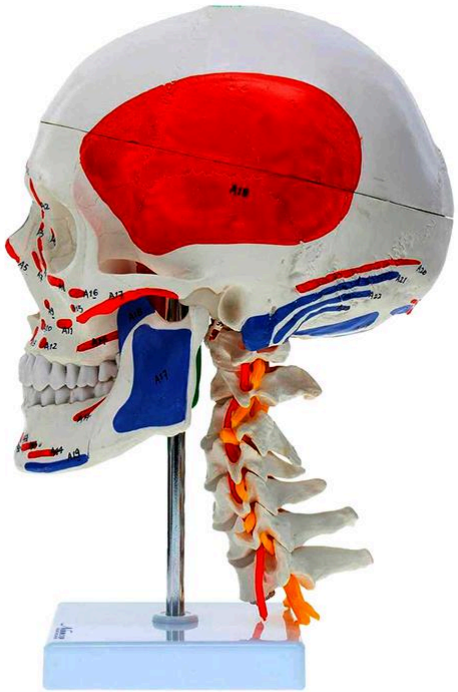

Nasco
HEALTHCARE



Nasco
HEALTHCARE





Colorful Didactic Skull with Muscle Insertion is a life-size anatomical model accurately representing the human skull and cervical spine. The skullcap is removable, revealing details of the internal structure, and the mandible is articulated and removable for ease of study. The left side shows the muscle origin and insertion points, while the right side presents the structures in didactic colors for better understanding.

Applications:

* Anatomy study in schools and universities.
* Training in orthopedics and general medicine.
* Educational tool for patients.
* Use in offices, examination rooms, and waiting rooms.
* Medical and scientific information.

Technical Features:

* Detailed representation of anatomical structures.
* Numbering of structures for easy identification.
* Didactic colors for bone and muscle differentiation.
* High-fidelity molding.
* Made of resistant and durable synthetic material.
* Life-size replicas.
* Includes base and metal rod for support.
* Includes an information card with related structures.
* Resin approved in toxicological tests.

3D Technology and Augmented Reality:

Our anatomical models offer a visual complement through information cards that activate 3D models viewable in augmented reality (AR). This interactive platform assists learning, allowing comparative analysis of anatomical structures and offering resources for continuing education in anatomy, physiology, and pathophysiology.

Technical Specifications:

* Material: Resin.
* Scale: Life-size.
* Model with base and metal rod.

* Model with references and bony landmarks.

Main Structures:

Occipital bone: Bone located in the posterior and inferior part of the skull, forming the base of the skull. It presents the foramen magnum, through which the spinal cord passes.

Parietal bone: One of the two bones that form the sides and roof of the skull. It articulates with the frontal bone, temporal bone, occipital bone, and sphenoid bone.

Frontal bone: Bone that forms the forehead and the upper part of the eye sockets. Contains the frontal sinuses.

Temporal bone: Paired bone, located in the lateral and inferior region of the skull, housing important structures such as the middle and inner ear.

Mandible: Movable bone of the face, responsible for mastication. It articulates with the temporal bones.

Maxilla: Paired bone that forms most of the superior skeleton of the face, forming the hard palate and part of the orbits.

Vertebra C1 (Atlas): First cervical vertebra, which articulates with the skull and vertebra C2 (axis). Its peculiar shape allows head movement.

Vertebra C2 (Axis): Second cervical vertebra, which has the odontoid process (dens), allowing the rotation of the head around the atlas.

Masseter muscle: Muscle of mastication, located in the cheek region, responsible for elevating the mandible.

Temporal muscle: Muscle of mastication, located in the temporal fossa, responsible for elevating and retracting the mandible.

Other structures can be verified directly on the physical piece or on the interactive 3D model.

About the Anatomical Models:

They are developed with resin replication technology, offering an alternative to natural anatomical models for teaching and research. They present the main morphological

characteristics with good cost-benefit, resistance, hand painting, and numbering for precise identification of structures.

List of all visible structures:

- Occipital bone
- Parietal bone
- Frontal bone
- Temporal bone
- C1 vertebra
- C2 vertebra
- C3 vertebra
- C4 vertebra
- C5 vertebra
- C6 vertebra
- C7 vertebra
- Spinal nerve
- Vertebral artery
- Semispinalis capitis muscle
- Trapezius muscle
- Rectus capitis posterior minor muscle
- Rectus capitis posterior major muscle
- Obliquus capitis superior muscle
- Longissimus capitis muscle
- Splenius capitis muscle
- Sternocleidomastoid muscle
- Occipital muscle
- Rectus capitis lateralis muscle
- Posterior belly of digastric muscle
- Stylohyoid muscle
- Stylopharyngeus muscle
- Styloglossus muscle
- Rectus capitis anterior muscle
- Longus capitis muscle
- Levator veli palatini muscle
- Tensor veli palatini muscle
- Sternocleidomastoid muscle
- Medial pterygoid muscle
- Superior constrictor muscle
- Lateral pterygoid muscle
- Medial pterygoid muscle
- Mylohyoid muscle
- Genioglossus muscle

- Geniohyoid muscle
- Anterior belly of digastric muscle
- Lateral pterygoid muscle
- Temporalis muscle
- Masseter muscle
- Masseter muscle
- Buccinator muscle
- Buccinator muscle
- Platysma
- Depressor anguli oris muscle
- Depressor labii inferioris muscle
- Incisivus labii inferioris muscle
- Mentalis muscle
- Temporalis muscle
- Zygomaticus major muscle
- Zygomaticus minor muscle
- Levator labii superioris muscle
- Levator anguli oris muscle
- Depressor septi nasi muscle
- Incisivus labii superioris muscle
- Nasalis muscle - alar part
- Transverse part of nasalis muscle
- Procerus muscle
- Levator labii superioris alaeque nasi muscle
- Orbicularis oculi muscle - inferior orbital part
- Orbicularis oculi muscle - lacrimal part
- Orbicularis oculi muscle - palpebral part
- Orbicularis oculi muscle - superior orbital part
- Depressor supercilii muscle
- Mandible
- Maxilla
- Zygomatic bone
- Sphenoid bone
- Lacrimal bone
- Nasal bone
- Vomer
- Inferior nasal concha
- Palatine bone
- Parietal bone
- Temporal bone
- Occipital bone
- Vertebra C1
- Vertebra C2

- Vertebra C3
- Vertebra C4
- Vertebra C5
- Vertebra C6
- Vertebra C7
- Palatine bone
- Sphenoid bone
- Lacrimal bone
- Vomer bone
- Nasal bone
- Inferior nasal concha
- Maxilla
- Mandible
- Anterior belly of digastric muscle
- Geniohyoid muscle
- Genioglossus muscle
- Mylohyoid muscle
- Medial pterygoid muscle
- Superior constrictor muscle
- Lateral pterygoid muscle
- Medial pterygoid muscle
- Sternocleidomastoid muscle
- Tensor veli palatini muscle
- Levator veli palatini muscle
- Stylohyoid muscle
- Stylopharyngeus muscle
- Styloglossus muscle
- Lateral rectus muscle of head
- Posterior belly of digastric muscle
- Posterior cerebral artery
- Basilar artery
- Pontine arteries
- Sphenoid bone
- Inferior oblique muscle of head
- Superior oblique muscle of head
- Semispinalis capitis muscle
- Trapezius muscle
- Occipitalis muscle
- Sternocleidomastoid muscle
- Splenius capitis muscle
- Longissimus capitis muscle
- Temporalis muscle
- Temporalis muscle

- Masseter muscle
- Zygomaticus major muscle
- Zygomaticus minor muscle
- Levator labii superioris muscle
- Buccinator muscle
- Levator anguli oris muscle
- Depressor septi nasi muscle
- Incisivus labii superioris muscle
- Nasalis muscle - alar part
- Transverse part of nasalis muscle
- Procerus muscle
- Levator labii superioris alaeque nasi muscle
- Orbicularis oculi muscle - inferior orbital part
- Orbicularis oculi muscle - lacrimal part
- Orbicularis oculi muscle - palpebral part
- Orbicularis oculi muscle - superior orbital part
- Depressor supercilii muscle
- Masseter muscle
- Buccinator muscle
- Platysma
- Depressor anguli oris muscle
- Depressor labii inferioris muscle
- Incisivus labii inferioris muscle
- Mentalis muscle
- M�sculo mentual