MG22303 | CLASSIC HUMAN SKULL WITH BLOOD VESSELS, 3 PARTS

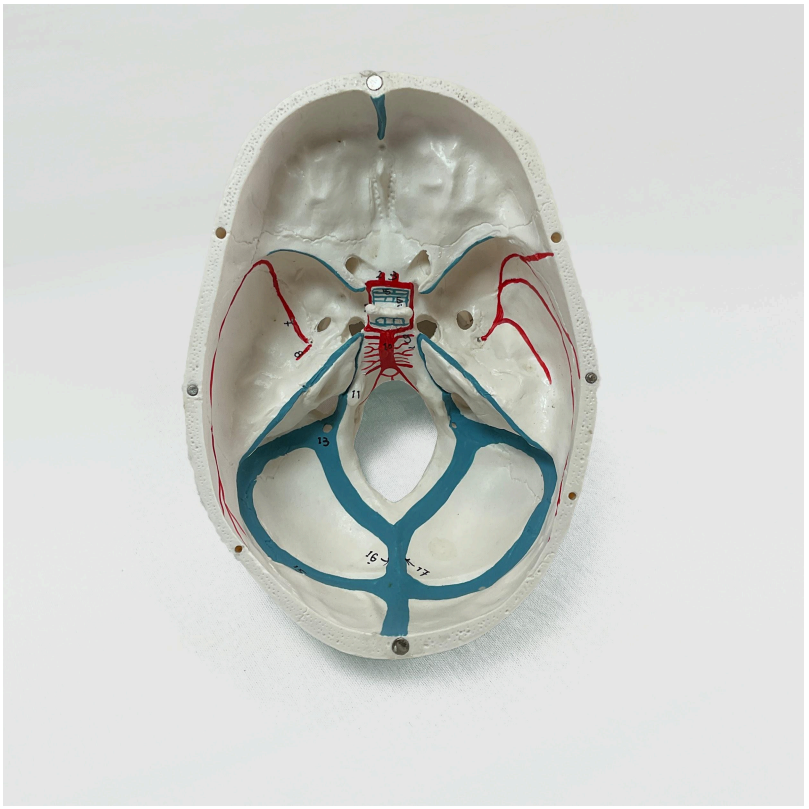

Nasco HEALTHCARE





Nasco
HEALTHCARE





Luxury Skull with Blood Vessels 3 Parts is a life-size anatomical model that accurately reproduces the structural details of the human skull, including meningeal vascularization and venous sinuses. The skullcap is removable, allowing for internal visualization, and the mandible is articulated and removable. All joints, sutures, fissures, foramina, and processes are represented with high fidelity. The model is numbered and hand-painted, facilitating learning.

Applications:

The model is ideal for the study of the skeletal system in schools and universities, surgical dissection training, classrooms, patient education, and medical procedure demonstration. It is also indicated for medical and scientific information purposes.

Technical Advantages:

* Detailed representation of bone and vascular structures.
* Numbered and hand-painted model in didactic colors.
* High fidelity in the representation of joints, sutures, fissures, foramina, and processes.
* Produced with high-quality resin, approved in toxicological tests.

* Natural molding.
* Manufactured from stable synthetic material.
* Precise replicas.

3D Technology and Augmented Reality:

Our anatomical models offer a visual complement through informative cards that activate 3D models viewable in augmented reality (AR). This interactive platform assists learning, allowing for comparative analysis of anatomical structures and offering resources for continuing education in anatomy, physiology, and pathophysiology.

Technical Specifications:

* Scale: Life-size
* Material: Synthetic resin
* Numbering: Yes
* Painting: Manual

Main Structures:

Superior sagittal sinus: A large venous sinus located in the midline of the cranial vault, between the two layers of the falx cerebri. Drains blood from the upper part of the brain to the confluence of sinuses.

Anterior cerebral artery: Branch of the internal carotid artery, supplies the medial surface of the frontal lobe and part of the parietal lobe of the brain.

Anterior communicating artery: Small artery that connects the anterior cerebral arteries, forming part of the cerebral arterial circle (Circle of Willis).

Internal carotid artery: Main artery supplying the brain, branching into several cerebral arteries.

Anterior intercavernous sinuses: Small venous sinuses connecting the cavernous sinuses, located in the sella turcica.

Posterior intercavernous sinuses: Similar to the anterior ones, but located in the posterior part of the cavernous sinuses.

Middle meningeal artery (frontal branch): Branch of the maxillary artery, irrigates the

frontal part of the dura mater.

Middle meningeal artery (parietal branch): Branch of the maxillary artery, irrigates the parietal part of the dura mater.

Posterior cerebral artery: Branch of the basilar artery, supplies the inferior and medial surfaces of the temporal and occipital lobes of the brain.

Basilar artery: Formed by the union of the vertebral arteries, contributes to the irrigation of the brainstem and cerebellum.

Other structures can be verified directly on the physical piece or on the interactive 3D model.

About Anatomical Models:

They are developed with resin replication technology, meeting the demand for anatomical parts for teaching and research. They present the main morphological characteristics with excellent cost-benefit, good resistance, manual painting, and numbering for precise identification of structures.

List of all visible structures:

- Superior sagittal sinus
- Anterior cerebral artery
- Anterior communicating artery
- Internal carotid artery
- Anterior intercavernous sinuses
- Posterior intercavernous sinuses
- Middle meningeal artery (frontal branch)
- Middle meningeal artery (parietal branch)
- Posterior cerebral artery
- Basilar artery
- Inferior petrosal sinus
- Sigmoid sinus
- Confluence of sinuses
- Occipital sinus
- Marginal sinus