MG22294 | CLASSIC HUMAN SKULL WITH REMOVABLE FACIAL MUSCLES



Nasco
HEALTHCARE



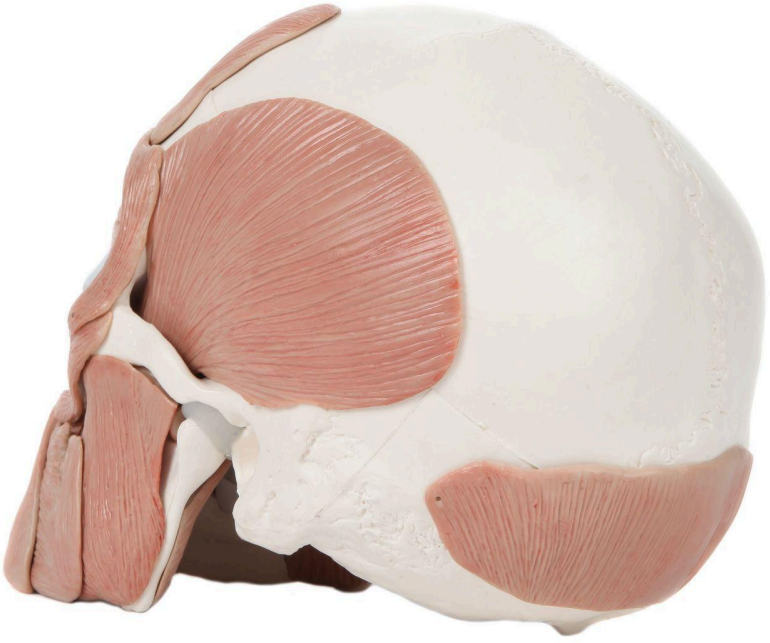

Nasco
HEALTHCARE

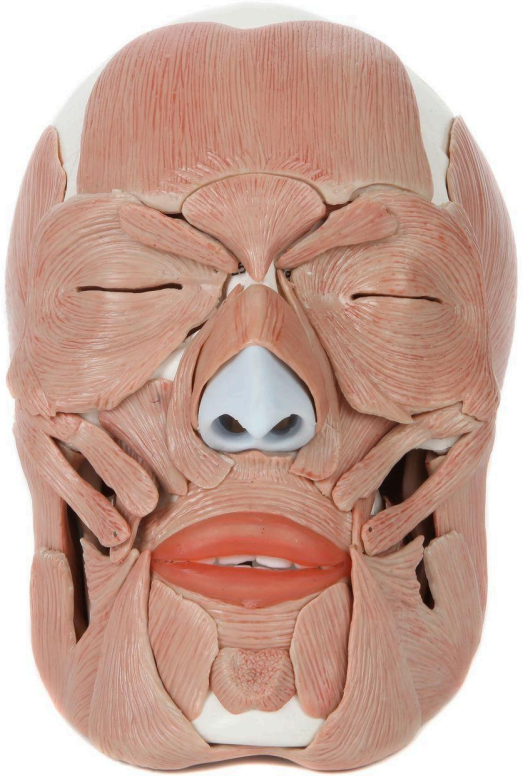



Skull with Facial Muscles: A detailed, life-size anatomical model with a removable skullcap secured by magnets and small pins, allowing easy access to the interior. It features realistic bone texture and 40 removable, numbered, and hand-painted facial muscles for in-depth study of facial expression and mastication musculature. The model includes permanent teeth and wisdom teeth, as well as detailed texture of the palatine bones.

Applications:

Ideal for schools, universities, professional training, medical and scientific information, anatomical study, surgical dissection training, classrooms, patient education, and procedure demonstration.

Technical Advantages:

* Detailed representation of facial and cranial bone musculature.
* 40 removable, numbered, and hand-painted muscles.
* Realistic bone texture.
* Removable skullcap with magnet and pin fastening system.
* Produced in resistant resin, approved in toxicological tests.
* High-fidelity natural molding.
* Includes an information card with related structures.

* Life-size replicas.

3D Technology and Augmented Reality:

Our anatomical models offer a visual complement through information cards that activate 3D models viewable in augmented reality (AR). This interactive platform aids learning, allowing comparative analysis of anatomical structures and offering resources for continuing education in anatomy, physiology, and pathophysiology.

Technical Specifications:

* Scale: Life-size
* Material: Resin

Main Structures:

occipitofrontalis muscle: Facial expression muscle covering the skullcap, composed of two bellies, the frontal and occipital, interconnected by the epicranial aponeurosis. Its main action is the elevation of the eyebrows and wrinkling of the forehead.

procerus muscle: Small muscle located between the eyebrows, responsible for wrinkling the skin between the eyes, generally expressing sadness or concentration.

right temporalis muscle: One of the main muscles of mastication, located in the lateral region of the head, its contraction elevates the mandible.

left temporalis muscle: Mastication muscle, symmetrical to the right, with the same function of elevating the mandible.

right masseter muscle: Powerful mastication muscle, located in the cheek region, its contraction closes the mandible.

left masseter muscle: Mastication muscle, symmetrical to the right, with the same function of closing the mandible.

right orbicularis oculi muscle: Circular muscle that closes the eyelids, participating in blinking and protecting the eye.

left orbicularis oculi muscle: Circular muscle, symmetrical to the right, with the same function of closing the eyelids.

orbicularis oris muscle + depressor septi nasi muscle: The orbicularis oris muscle closes and projects the lips, while the depressor septi nasi muscle assists in lowering the tip of the nose.

right zygomaticus major and minor muscles: Facial expression muscles that elevate the angle of the mouth, contributing to smiling. The zygomaticus major is more powerful and prominent than the minor.

Other structures can be verified directly on the physical piece or on the interactive 3D model.

About the Anatomical Models:

They are developed with resin replication technology, meeting the demand for anatomical pieces for teaching and research. They present the essential morphological characteristics with excellent cost-benefit, good resistance, hand painting, and numbering for precise identification of structures.

List of all visible structures:

- occipitofrontalis muscle
- procerus muscle
- right temporalis muscle
- left temporalis muscle
- nasalis muscle
- right depressor supercilii muscle
- left depressor supercilii muscle
- right orbicularis oculi muscle
- left orbicularis oculi muscle
- right levator labii superioris alaeque nasi muscle
- left levator labii superioris alaeque nasi muscle
- orbicularis oris muscle + depressor septi nasi muscle
- right levator labii superioris muscle
- left levator labii superioris muscle
- right zygomaticus major and minor muscles
- left zygomaticus major and minor muscles
- right platysma muscle
- left platysma muscle
- depressor anguli oris muscle + mentalis muscle
- right masseter muscle
- left masseter muscle
- right risorius muscle
- left risorius muscle

- left depressor labii inferioris muscle
- right depressor labii inferioris muscle
- mentalis muscle
- occipitofrontalis muscle, occipital belly
- nasal cartilage
- right medial pterygoid muscle
- left medial pterygoid muscle