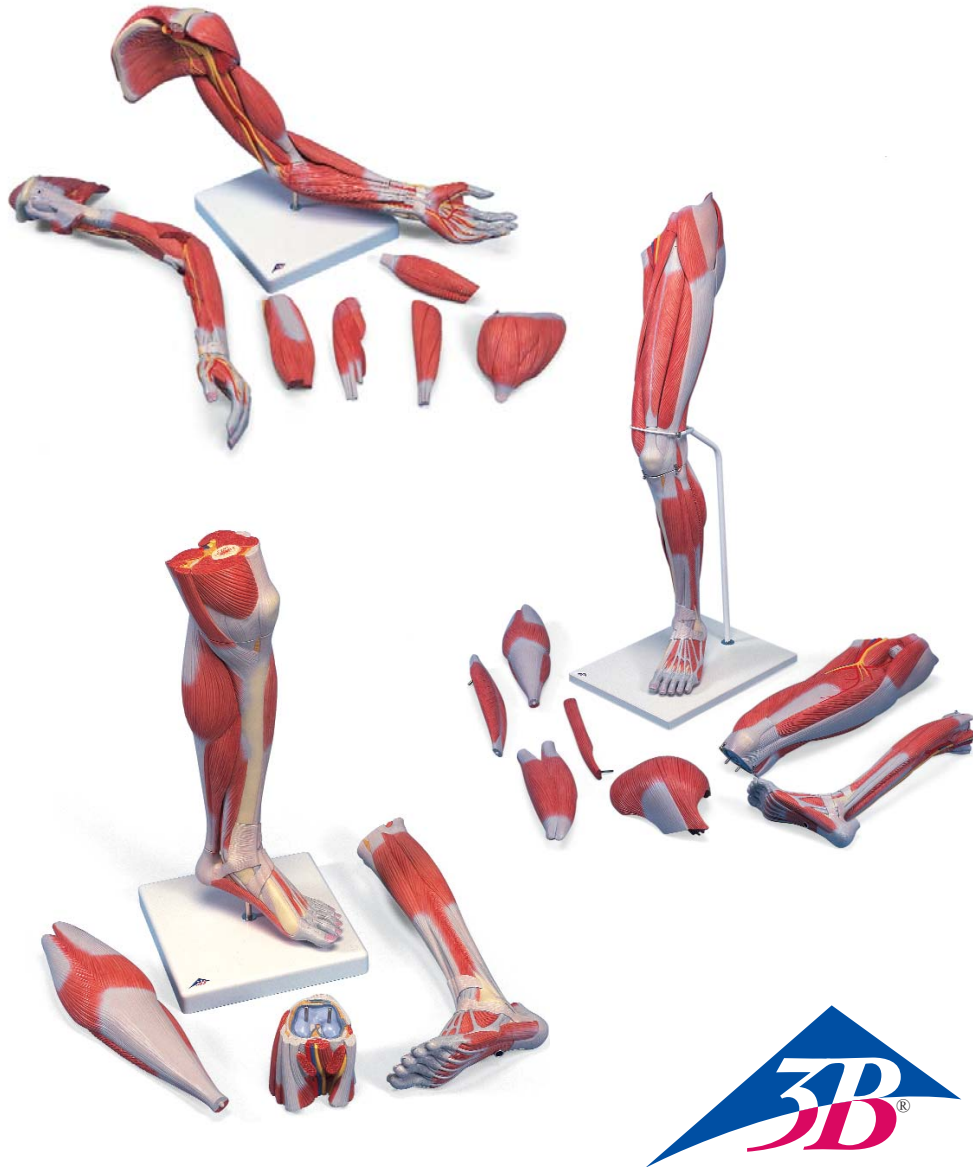
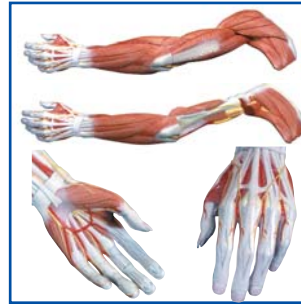

M11, M21, M22

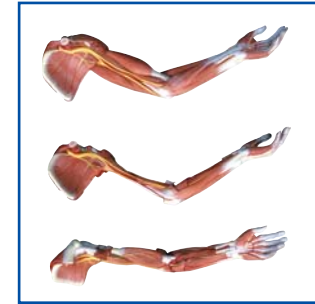

M11 4



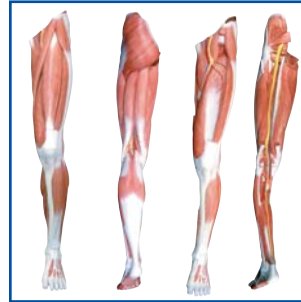
-  5
-  6
-  7
-  8
-  9
-  10
-  11

M11 12



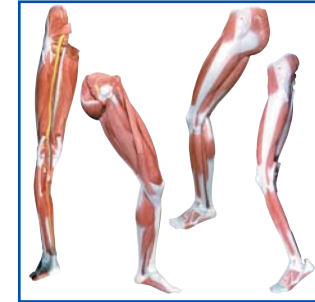-  13
-  14
-  15
-  16
-  17
-  18
-  19

M21 20



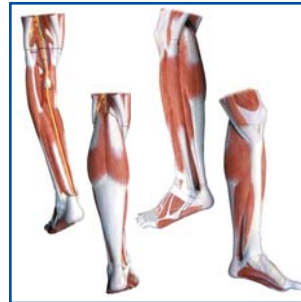-  21
-  22
-  23
-  24
-  25
-  26
-  27

M21 28



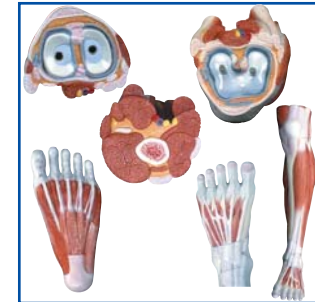-  29
-  30
-  31
-  32
-  33
-  34
-  35








M22 36



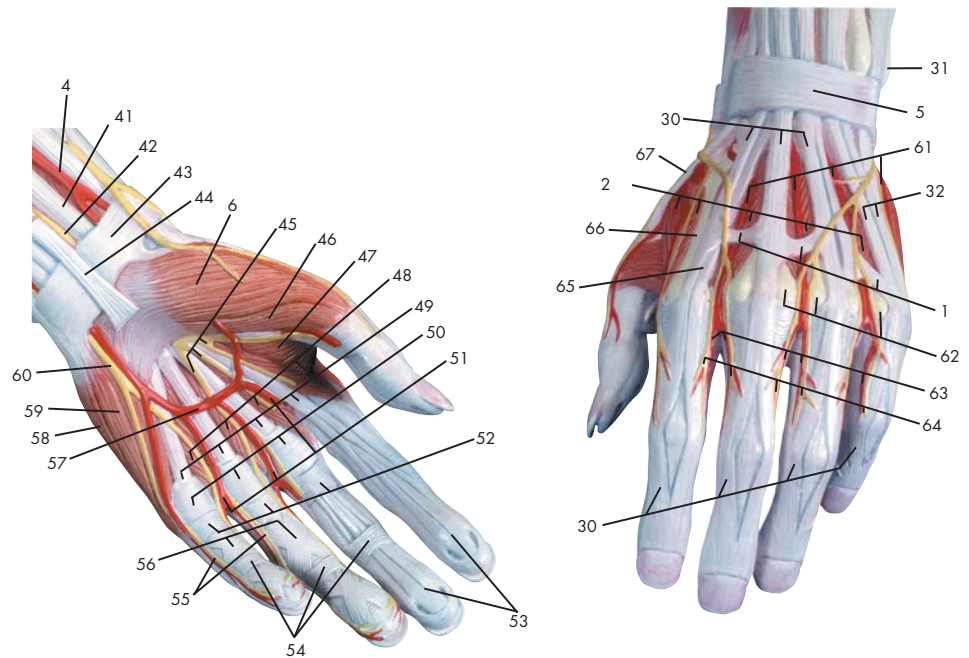
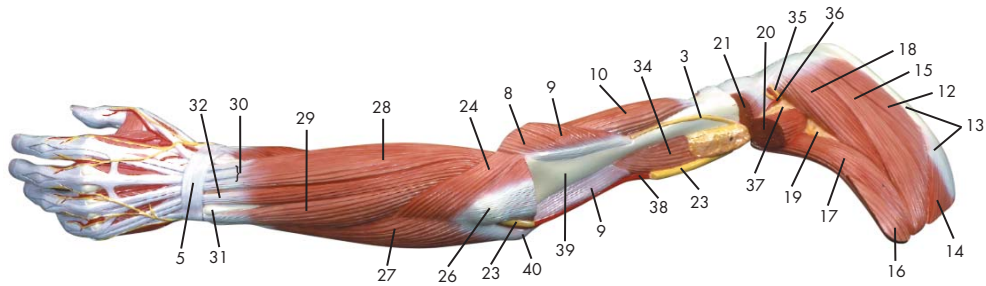
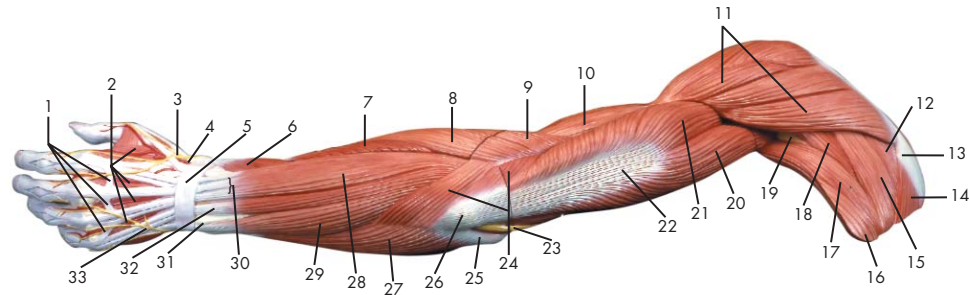
-  37
-  38
-  39
-  40
-  41
-  42
-  43

M22 44



-  45
-  46
-  47
-  48
-  49
-  50
-  51

Latin



- | | | | |
|----|--|----|--|
| 1 | Conexus intertendinei | 48 | Mm. lumbricales manus |
| 2 | Mm. interossei dorsales manus | 49 | M. flexor digitorum superficialis, tendo |
| 3 | N. radialis | 50 | Lig. metacarpale transversum superficiale |
| 4 | A. radialis | 51 | Aa. digitales palmares communes |
| 5 | Retinaculum extensorum | 52 | Manus, vagina tendinum digitorum |
| 6 | M. abductor pollicis brevis | 53 | M. flexor digitorum profundus, tendo |
| 7 | M. extensor carpi radialis brevis | 54 | Vaginae fibrosae, pars anularis |
| 8 | M. extensor carpi radialis longus | 55 | N. ulnaris, nn. digitales palmares proprii |
| 9 | M. brachioradialis | 56 | Vaginae fibrosae, pars cruciforme |
| 10 | M. brachialis | 57 | Arcus palmaris superficialis |
| 11 | M. deltoideus | 58 | M. abductor digiti minimi manus |
| 12 | M. supraspinatus | 59 | M. opponens digiti minimi manus |
| 13 | Scapula, spina | 60 | N. ulnaris, ramus superficialis |
| 14 | M. trapezius | 61 | Aa. metatarsales dorsales |
| 15 | M. infraspinatus | 62 | Os metacarpale, caput |
| 16 | M. latissimus dorsi | 63 | Aa. digitales dorsales manus |
| 17 | M. teres major | 64 | Nn. digitales dorsales (manus) |
| 18 | M. teres minor | 65 | M. extensor indicis, tendo |
| 19 | Spatium axillare mediale | 66 | Os metacarpale, corpus |
| 20 | M. triceps brachii, caput longum | 67 | M. extensor pollicis, tendo |
| 21 | M. triceps brachii, caput laterale | | |
| 22 | M. triceps brachii, tendo | | |
| 23 | N. ulnaris | | |
| 24 | M. anconeus | | |
| 25 | Humerus, epicondylus medialis | | |
| 26 | Olecranon | | |
| 27 | M. flexor carpi ulnaris | | |
| 28 | M. extensor digitorum manus | | |
| 29 | M. extensor carpi ulnaris | | |
| 30 | M. extensor digitorum manus, tendo | | |
| 31 | Ulna, caput | | |
| 32 | M. extensor digiti minimi, tendo | | |
| 33 | N. ulnaris, ramus dorsalis | | |
| 34 | M. coracobrachialis | | |
| 35 | N. axillaris | | |
| 36 | A. circumflexa humeri posterior | | |
| 37 | Spatium axillare laterale | | |
| 38 | A. brachialis | | |
| 39 | Humerus | | |
| 40 | Humerus, epicondylus lateralis | | |
| 41 | M. flexor carpi radialis, tendo | | |
| 42 | N. medianus | | |
| 43 | Retinaculum flexorum | | |
| 44 | M. palmaris longus, tendo | | |
| 45 | N. medianus, nn. digitales palmares communes | | |
| 46 | M. flexor pollicis brevis | | |
| 47 | M. adductor pollicis | | |

Muscular arm

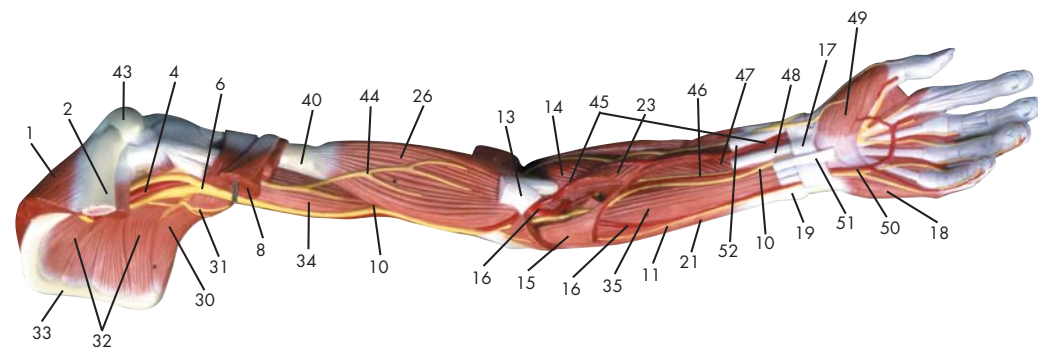
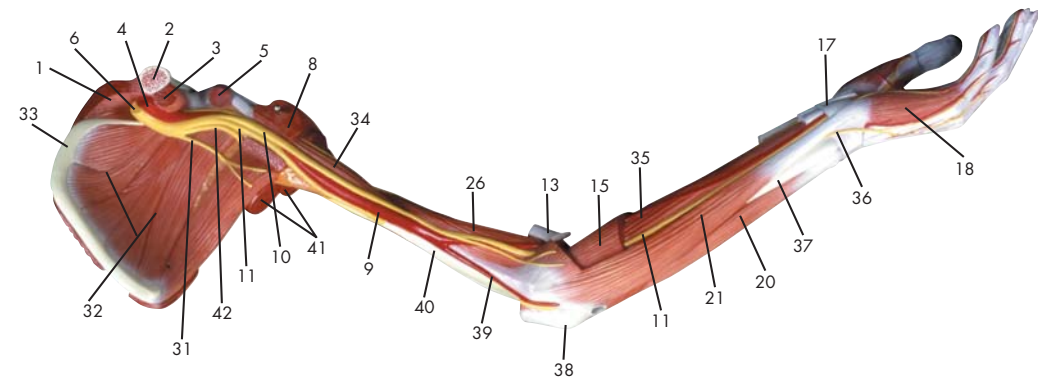
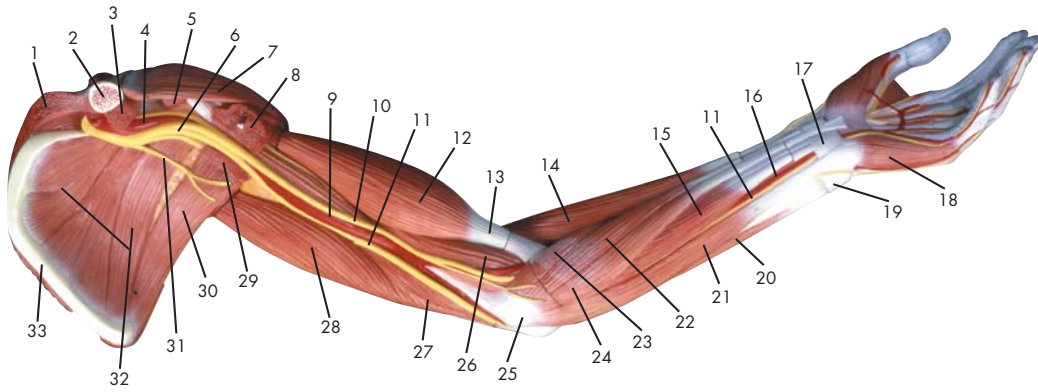
English

- 1 Tendinous junction
- 2 Dorsal interosseous muscles of hand
- 3 Radial nerve
- 4 Radial artery
- 5 Extensor retinaculum
- 6 Abductor pollicis brevis muscle
- 7 Extensor carpi radialis brevis muscle
- 8 Extensor carpi radialis longus muscle
- 9 Brachioradialis muscle
- 10 Brachialis muscle
- 11 Deltoides muscle
- 12 Supraspinatus muscle
- 13 Scapular spine
- 14 Trapezius muscle
- 15 Infraspinatus muscle
- 16 Latissimus dorsi muscle
- 17 Teres major muscle
- 18 Teres minor muscle
- 19 Triangular space
- 20 Long head of triceps brachii muscle
- 21 Lateral head of triceps brachii muscle
- 22 Tendon of triceps brachii muscle
- 23 Ulnar nerve
- 24 Anconeus muscle
- 25 Medial epicondyle of humerus
- 26 Olecranon process of ulna
- 27 Flexor carpi ulnaris muscle
- 28 Extensor digitorum muscle of hand
- 29 Extensor carpi ulnaris muscle
- 30 Tendon of extensor digitorum muscle of hand
- 31 Head of ulna
- 32 Tendon of extensor digiti minimi muscle
- 33 Dorsal branch of ulnar nerve
- 34 Coracobrachialis muscle
- 35 Axillary nerve
- 36 Posterior circumflex humeral artery
- 37 Quadrangular space
- 38 Brachial artery
- 39 Humerus
- 40 Lateral epicondyle of humerus
- 41 Tendon of flexor carpi radialis muscle
- 42 Median nerve
- 43 Flexor retinaculum
- 44 Tendon of palmaris longus muscle
- 45 Common palmar digital nerves of median nerve
- 46 Flexor pollicis brevis muscle
- 47 Adductor pollicis muscle
- 48 Lumbrical muscles of hand
- 49 Tendon of flexor digitorum superficialis muscle
- 50 Superficial transverse metacarpal ligament
- 51 Common palmar digital arteries
- 52 Digital synovial sheath
- 53 Tendon of flexor digitorum profundus muscle
- 54 Annular part of fibrous tendon sheaths
- 55 Proper palmar digital nerves of ulnar nerve
- 56 Cruciform part of fibrous tendon sheaths
- 57 Superficial palmar arch
- 58 Abductor digiti minimi muscle of hand
- 59 Opponens digiti minimi muscle of hand
- 60 Superficial branch of ulnar nerve
- 61 Dorsal metatarsal arteries
- 62 Head of metacarpal bone
- 63 Dorsal digital arteries of hand
- 64 Dorsal digital nerves of fingers
- 65 Tendon of extensor indicis muscle
- 66 Body of metacarpal bone
- 67 Tendon of extensor pollicis muscle

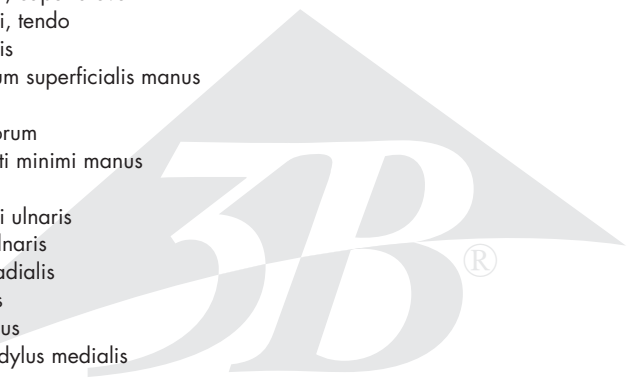
Deutsch

- 1 Sehnenbrücke
- 2 Zwischenknochenmuskeln (Handrücken)
- 3 Speichennerv
- 4 Speichenschlagader
- 5 Querles Handrückenband
- 6 Kurzer Daumenabzieher
- 7 Kurzer, speichenseitiger Handgelenksstrecker
- 8 Langer, speichenseitiger Handgelenksstrecker
- 9 Oberarm-Speichenmuskel
- 10 Oberarmmuskel
- 11 Deltamuskel
- 12 Obergrätenmuskel
- 13 Schulterblattgräte
- 14 Kapuzenmuskel
- 15 Untergrätenmuskel
- 16 Breitester Rückenmuskel
- 17 Großer Rundmuskel
- 18 Kleiner Rundmuskel
- 19 Spatium axillare mediale
- 20 Langer Kopf (Dreiköpfiger Oberarmmuskel)
- 21 Seitlicher Kopf (Dreiköpfiger Oberarmmuskel)
- 22 Sehne des dreiköpfigen Oberarmmuskels
- 23 Ellenerv
- 24 Ellenbogenmuskel
- 25 Mittlerer Epikondylus (Oberarm)
- 26 Ellenbogenkopf
- 27 Ellenseitiger Handgelenksbeuger
- 28 Fingerstrecker
- 29 Ellenseitiger Strecker des Handgelenks
- 30 Sehne des Fingerstreckers
- 31 Ellenkopf
- 32 Sehne des Kleinfingerstreckers
- 33 Ellenseitiger Handrückenast
- 34 M. coracobrachialis
- 35 N. axillaris
- 36 A. circumflexa humeri posterior
- 37 Spatium axillare laterale
- 38 Armschlagader
- 39 Oberarmknochen
- 40 Seitlicher Epikondylus (Oberarm)
- 41 Sehne des speichenseitigen Handgelenksbeugers
- 42 Mittelarmerve
- 43 Retinaculum flexorum
- 44 M. palmaris longus, tendo
- 45 N. medianus, nn. digitales palmares communes
- 46 Kurzer Daumenbeuger
- 47 Daumenanzieher
- 48 Spulmuskeln (Hand)
- 49 M. flexor digitorum superficialis, tendo
- 50 Lig. metacarpale transversum superficiale
- 51 Gemeinsame Fingerarterien der Hohlhandseite
- 52 Manus, vagina tendinum digitorum
- 53 M. flexor digitorum profundus, tendo
- 54 Ringförmiger Anteil der Sehnenscheiden
- 55 Hohlhandseitige Fingeräste des Ellenervs
- 56 Kreuzförmiger Anteil der Sehnenscheiden
- 57 Oberflächlicher Hohlhandbogen
- 58 Kleinfingerabzieher
- 59 M. opponens digiti minimi manus
- 60 Ellenerv, oberflächlicher Ast
- 61 Rückseitige Mittelfußarterien
- 62 Mittelhandknochen, Kopf
- 63 Rückseitige Fingerarterien
- 64 Hautnerven der Fingerrücken
- 65 Sehne des Zeigefingerstreckers
- 66 Mittelhandknochen, Körper
- 67 Sehne des Daumenstreckers

Latin



- | | | | |
|----|---|----|----------------------------------|
| 1 | M. trapezius | 49 | M. abductor pollicis brevis |
| 2 | Clavicula | 50 | Arcus palmaris superficialis |
| 3 | M. subclavius | 51 | M. palmaris longus, tendo |
| 4 | A. axillaris | 52 | M. flexor pollicis longus, tendo |
| 5 | M. pectoralis minor | | |
| 6 | Plexus brachialis | | |
| 7 | M. deltoideus | | |
| 8 | M. pectoralis major | | |
| 9 | A. brachialis | | |
| 10 | N. medianus | | |
| 11 | N. ulnaris | | |
| 12 | M. biceps brachii, caput breve | | |
| 13 | M. biceps brachii, tendo | | |
| 14 | M. brachioradialis | | |
| 15 | M. flexor digitorum superficialis manus | | |
| 16 | A. ulnaris | | |
| 17 | Retinaculum flexorum | | |
| 18 | M. abductor digiti minimi manus | | |
| 19 | Ulna, caput | | |
| 20 | M. extensor carpi ulnaris | | |
| 21 | M. flexor carpi ulnaris | | |
| 22 | M. flexor carpi radialis | | |
| 23 | M. pronator teres | | |
| 24 | M. palmaris longus | | |
| 25 | Humerus, epicondylus medialis | | |
| 26 | M. brachialis | | |
| 27 | M. triceps brachii, caput mediale | | |
| 28 | M. triceps brachii, caput longum | | |
| 29 | M. latissimus dorsi | | |
| 30 | M. teres major | | |
| 31 | N. thoracodorsalis | | |
| 32 | M. subscapularis | | |
| 33 | Scapula, margo medialis | | |
| 34 | M. coracobrachialis | | |
| 35 | M. flexor digitorum profundus manus | | |
| 36 | N. ulnaris, ramus dorsalis | | |
| 37 | Ulna | | |
| 38 | Olecranon | | |
| 39 | A. collateralis ulnaris inferior | | |
| 40 | Humerus | | |
| 41 | M. triceps brachii | | |
| 42 | N. radialis | | |
| 43 | Acromion | | |
| 44 | N. musculocutaneus | | |
| 45 | A. radialis | | |
| 46 | A. interossea anterior | | |
| 47 | M. pronator quadratus | | |
| 48 | M. flexor carpi radialis, tendo | | |



Muscular arm

English

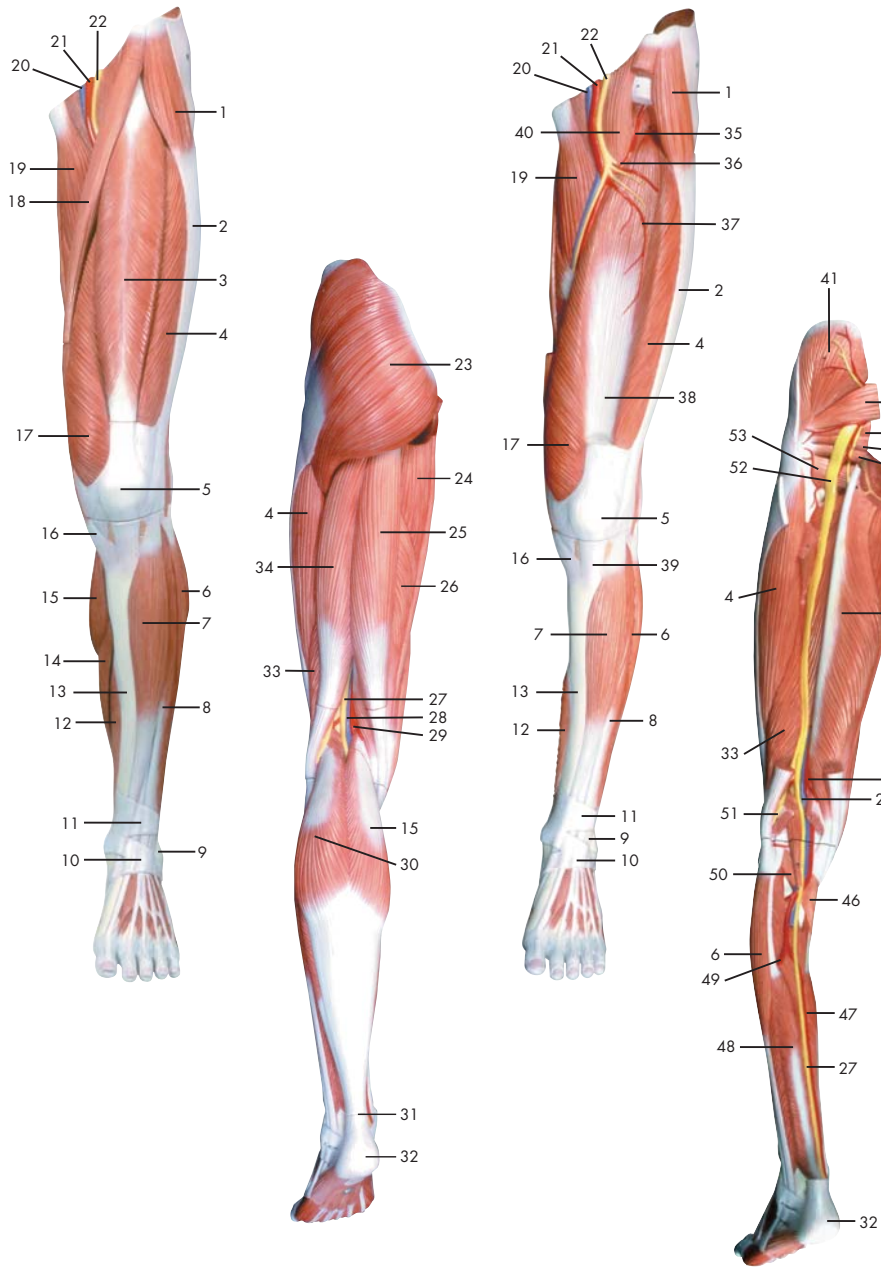
- 1 Trapezius muscle
- 2 Clavicle
- 3 Subclavius muscle
- 4 Axillary artery
- 5 Pectoralis minor muscle
- 6 Brachial plexus
- 7 Deltoides muscle
- 8 Pectoralis major muscle
- 9 Brachial artery
- 10 Median nerve
- 11 Ulnar nerve
- 12 Short (medial) head of biceps brachii muscle
- 13 Tendon of biceps brachii muscle
- 14 Brachioradialis muscle
- 15 Flexor digitorum superficialis muscle
- 16 Ulnar artery
- 17 Flexor retinaculum
- 18 Abductor digiti minimi muscle of hand
- 19 Head of ulna
- 20 Extensor carpi ulnaris muscle
- 21 Flexor carpi ulnaris muscle
- 22 Flexor carpi radialis muscle
- 23 Pronator teres muscle
- 24 Palmaris longus muscle
- 25 Medial epicondyle of humerus
- 26 Brachialis muscle
- 27 Medial head of triceps brachii muscle
- 28 Long head of triceps brachii muscle
- 29 Latissimus dorsi muscle
- 30 Teres major muscle
- 31 Thoracodorsal nerve
- 32 Subscapularis muscle
- 33 Medial margin of scapula
- 34 Coracobrachialis muscle
- 35 Flexor digitorum profundus muscle
- 36 Dorsal branch of ulnar nerve
- 37 Ulna
- 38 Olecranon process of ulna
- 39 Inferior collateral ulnar artery
- 40 Humerus
- 41 Triceps brachii muscle
- 42 Radial nerve
- 43 Acromion (acromial bone)
- 44 Musculocutaneous nerve
- 45 Radial artery
- 46 Anterior interosseous artery
- 47 Pronator quadratus muscle
- 48 Tendon of flexor carpi radialis muscle
- 49 Abductor pollicis brevis muscle
- 50 Superficial palmar arch
- 51 Tendon of palmaris longus muscle
- 52 Tendon of flexor pollicis longus muscle

Deutsch

- 1 Kapuzenmuskel
- 2 Schlüsselbein
- 3 M. subclavius
- 4 Achselschlagader
- 5 Kleiner Brustmuskel
- 6 Armgeflecht
- 7 Deltamuskel
- 8 Großer Brustmuskel
- 9 Armschlagader
- 10 Mittelarmnerv
- 11 Ellenerv
- 12 Kurzer Kopf (Zweiköpfiger Oberarmmuskel)
- 13 Sehne des zweiköpfigen Oberarmmuskels
- 14 Oberarm-Speichenmuskel
- 15 Oberflächlicher Fingerbeuger
- 16 Ellenschlagader
- 17 Retinaculum flexorum
- 18 Kleinfingerabzieher
- 19 Ellenkopf
- 20 Ellenseitiger Strecker des Handgelenks
- 21 Ellenseitiger Handgelenksbeuger
- 22 Speichenseitiger Handgelenksbeuger
- 23 Runder Einwärtsdrehmuskel
- 24 Langer Hohlhandmuskel
- 25 Mittlerer Epikondylus (Oberarm)
- 26 Oberarmmuskel
- 27 Mittlerer Kopf (Dreiköpfiger Oberarmmuskel)
- 28 Langer Kopf (Dreiköpfiger Oberarmmuskel)
- 29 Breitester Rückenmuskel
- 30 Großer Rundmuskel
- 31 N. thoracodorsalis
- 32 M. subscapularis
- 33 Innerer Rand des Schulterblattes
- 34 M. coracobrachialis
- 35 Tiefer Fingerbeuger
- 36 Ellenseitiger Handrückenast
- 37 Elle
- 38 Ellenbogenkopf
- 39 A. collateralis ulnaris inferior
- 40 Oberarmknochen
- 41 Dreiköpfiger Oberarmmuskel
- 42 Speichennerv
- 43 Schulterhöhe
- 44 Muskelhautnerv
- 45 Speichenschlagader
- 46 Vordere Zwischenknochenarterie
- 47 Quadratischer Einwärtsdrehmuskel

Muskelarm

- 48 Sehne des speichenseitigen Handgelenksbeugers
- 49 Kurzer Daumenabzieher
- 50 Oberflächlicher Hohlhandbogen
- 51 M. palmaris longus, tendo
- 52 Sehne des langen Daumenbeugers



Latin

- | | | | |
|----|--|----|-----------------------|
| 1 | M. tensor fasciae latae | 47 | A. tibialis posterior |
| 2 | Tractus iliotibialis | 48 | M. tibialis posterior |
| 3 | M. rectus femoris | 49 | A. fibularis |
| 4 | M. vastus lateralis | 50 | M. plantaris |
| 5 | Patella | 51 | N. fibularis communis |
| 6 | M. peroneus longus | 52 | N. ischiadicus |
| 7 | M. tibialis anterior | 53 | M. quadratus femoris |
| 8 | M. extensor digitorum longus pedis | | |
| 9 | Malleolus lateralis | | |
| 10 | Retinaculum musculorum extensorum inferius | | |
| 11 | Retinaculum musculorum extensorum superius | | |
| 12 | M. flexor digitorum longus pedis | | |
| 13 | Tibia | | |
| 14 | M. soleus | | |
| 15 | M. gastrocnemius, caput mediale | | |
| 16 | M. sartorius, tendo | | |
| 17 | M. vastus medialis | | |
| 18 | M. sartorius | | |
| 19 | M. adductor longus | | |
| 20 | V. femoralis | | |
| 21 | A. femoralis | | |
| 22 | N. femoralis | | |
| 23 | M. gluteus maximus | | |
| 24 | M. adductor magnus | | |
| 25 | M. semitendinosus | | |
| 26 | M. semimembranosus | | |
| 27 | N. tibialis | | |
| 28 | V. poplitea | | |
| 29 | A. poplitea | | |
| 30 | M. gastrocnemius, caput laterale | | |
| 31 | Tendo calcanei | | |
| 32 | Tuber calcanei | | |
| 33 | M. biceps femoris, caput breve | | |
| 34 | M. biceps femoris, caput longum | | |
| 35 | A. circumflexa femoris lateralis, ramus ascendens | | |
| 36 | A. circumflexa femoris lateralis | | |
| 37 | A. circumflexa femoris lateralis, ramus descendens | | |
| 38 | M. vastus intermedius | | |
| 39 | Lig. patellae | | |
| 40 | M. iliopsoas | | |
| 41 | M. gluteus medius | | |
| 42 | M. piriformis | | |
| 43 | M. gemellus superior | | |
| 44 | M. obturatorius internus | | |
| 45 | M. gemellus inferior | | |
| 46 | M. popliteus | | |



Muscular leg

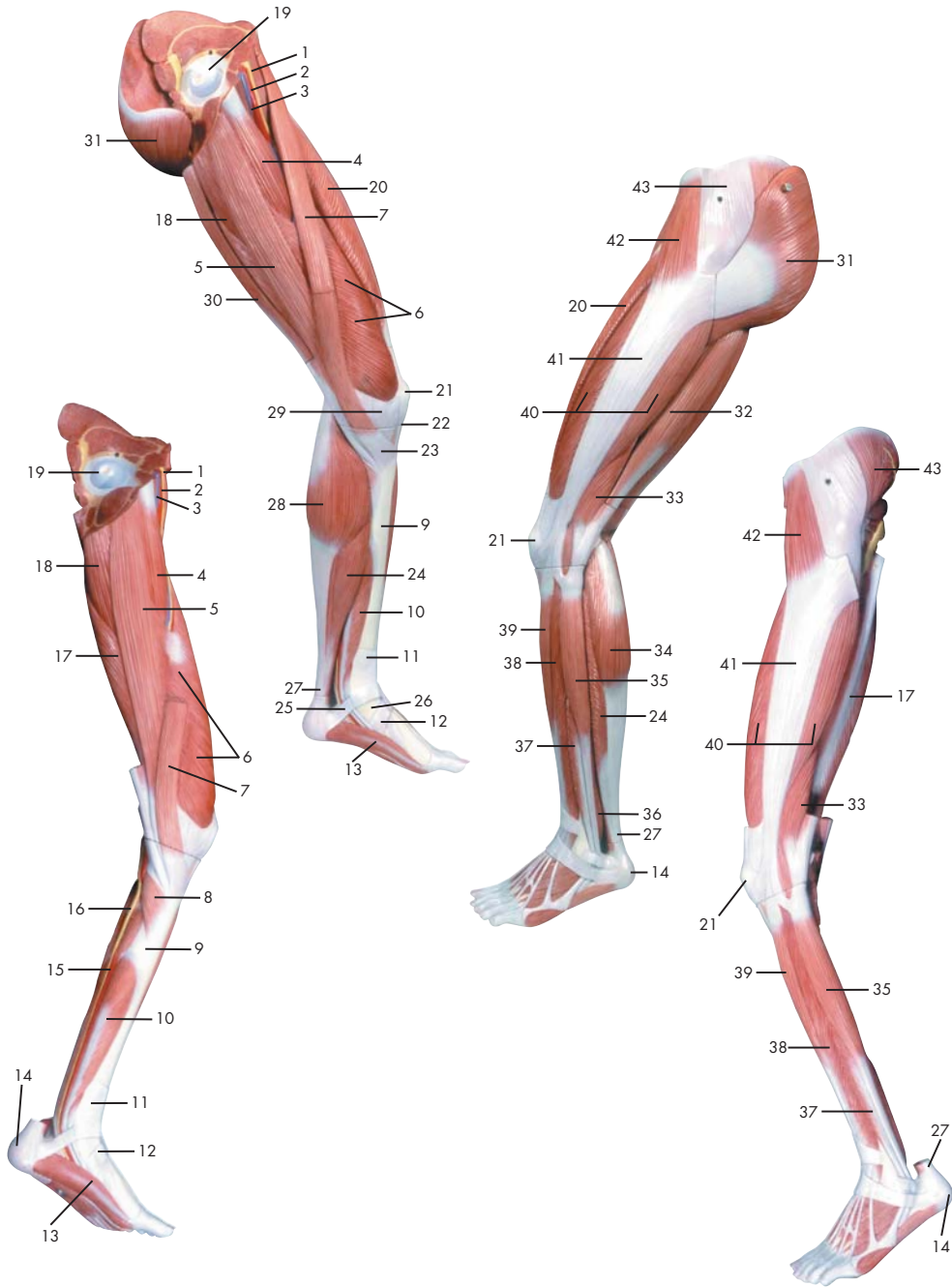
English

- 1 Trapezius muscle
- 2 Clavicle
- 3 Subclavius muscle
- 4 Axillary artery
- 5 Pectoralis minor muscle
- 6 Brachial plexus
- 7 Deltoides muscle
- 8 Pectoralis major muscle
- 9 Brachial artery
- 10 Median nerve
- 11 Ulnar nerve
- 12 Short (medial) head of biceps brachii muscle
- 13 Tendon of biceps brachii muscle
- 14 Brachioradialis muscle
- 15 Flexor digitorum superficialis muscle
- 16 Ulnar artery
- 17 Flexor retinaculum
- 18 Abductor digiti minimi muscle of hand
- 19 Head of ulna
- 20 Extensor carpi ulnaris muscle
- 21 Flexor carpi ulnaris muscle
- 22 Flexor carpi radialis muscle
- 23 Pronator teres muscle
- 24 Palmaris longus muscle
- 25 Medial epicondyle of humerus
- 26 Brachialis muscle
- 27 Medial head of triceps brachii muscle
- 28 Long head of triceps brachii muscle
- 29 Latissimus dorsi muscle
- 30 Teres major muscle
- 31 Thoracodorsal nerve
- 32 Subscapularis muscle
- 33 Medial margin of scapula
- 34 Coracobrachialis muscle
- 35 Flexor digitorum profundus muscle
- 36 Dorsal branch of ulnar nerve
- 37 Ulna
- 38 Olecranon process of ulna
- 39 Inferior collateral ulnar artery
- 40 Humerus
- 41 Triceps brachii muscle
- 42 Radial nerve
- 43 Acromion (acromial bone)
- 44 Musculocutaneous nerve
- 45 Radial artery
- 46 Anterior interosseous artery
- 47 Pronator quadratus muscle
- 48 Tendon of flexor carpi radialis muscle
- 49 Abductor pollicis brevis muscle
- 50 Superficial palmar arch
- 51 Tendon of palmaris longus muscle
- 52 Tendon of flexor pollicis longus muscle
- 53 Quadratus femoris muscle

Deutsch

- 1 Spanner der Oberschenkelbinde
- 2 Faszienspanner des Beines
- 3 Gerader Oberschenkelmuskel
- 4 Seitlicher großer Muskel
- 5 Kniescheibe
- 6 Langer Wadenbeinmuskel
- 7 Vorderer Schienbeinmuskel
- 8 Außenknöchel
- 9 Retinaculum musculorum extensorum inferius
- 10 Retinaculum musculorum extensorum superius
- 11 Langer Zehenbeuger
- 12 Schienbein
- 13 Schollenmuskel
- 14 Mittlerer Kopf des Zwillingswadenmuskels
- 15 Sehne des Schneidermuskels
- 16 Mittlerer großer Muskel
- 17 Schneidermuskel
- 18 Langer Schenkelanzieher
- 19 Oberschenkelvene
- 20 Oberschenkelschlagader
- 21 Oberschenkelnerv
- 22 Großer Gesäßmuskel
- 23 Großer Schenkelanzieher
- 24 Halbsehniger Muskel
- 25 Halbmembranöser Muskel
- 26 Schienbeinnerv
- 27 Kniekehlevene
- 28 Kniekehlschlagader
- 29 Seitlicher Kopf des Zwillingswadenmuskels
- 30 Achillessehne
- 31 Fersenbeinhöcker
- 32 Zweiköpfiger Oberschenkelmuskel, kurzer Kopf
- 33 Zweiköpfiger Oberschenkelmuskel, langer Kopf
- 34 Aufsteigender Ast der seitlichen Kranzarterie des Oberschenkels
- 35 Seitliche Kranzarterie des Oberschenkels
- 36 Absteigender Ast der seitlichen Kranzarterie des Oberschenkels
- 37 M. vastus intermedius
- 38 Kniescheibenband
- 39 Langer Zehenstrecker
- 40 Darmbein-Lendenmuskel
- 41 Mittlerer Gesäßmuskel
- 42 Birnenmuskel
- 43 Oberer Zwillingsmuskel
- 44 Innerer Hüftlochmuskel
- 45 Unterer Zwillingsmuskel
- 46 Kniekehlenmuskel
- 47 Hintere Schienbeinschlagader
- 48 Hinterer Schienbeinmuskel
- 49 Wadenbeinschlagader
- 50 Sohlenspanner
- 51 Gemeinsamer Wadenbeinnerv
- 52 Ischiassnerv
- 53 Viereckiger Oberschenkelmuskel

Muskelbein



- 1 N. femoralis
- 2 A. femoralis
- 3 V. femoralis
- 4 M. adductor longus
- 5 M. gracilis
- 6 M. vastus medialis
- 7 M. sartorius
- 8 M. popliteus
- 9 Tibia
- 10 M. flexor digitorum longus pedis
- 11 Retinaculum musculorum extensorum superius
- 12 Retinaculum musculorum extensorum inferius
- 13 M. abductor hallucis
- 14 Tuber calcanei
- 15 A. tibialis posterior
- 16 N. tibialis
- 17 M. semimembranosus
- 18 M. adductor magnus
- 19 Femur, caput
- 20 M. rectus femoris
- 21 Patella
- 22 Lig. patellae
- 23 Pes anserinus superficialis
- 24 M. soleus
- 25 Pes, retinaculum musculorum flexorum
- 26 Malleolus medialis
- 27 Tendo calcanei
- 28 M. gastrocnemius, caput mediale
- 29 Retinaculum patellae mediale
- 30 M. semitendinosus
- 31 M. gluteus maximus
- 32 M. biceps femoris, caput longum
- 33 M. biceps femoris, caput breve
- 34 M. gastrocnemius, caput laterale
- 35 M. peroneus longus
- 36 M. tibialis posterior
- 37 M. peroneus brevis
- 38 M. extensor digitorum longus pedis
- 39 M. tibialis anterior
- 40 M. vastus lateralis
- 41 Tractus iliitibialis
- 42 M. tensor fasciae latae
- 43 M. gluteus medius



Muscular leg

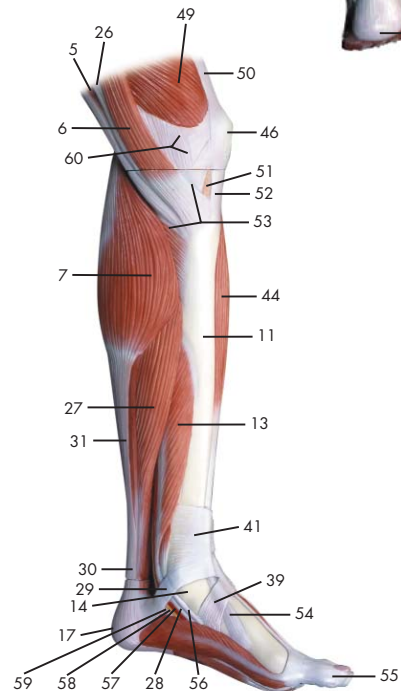
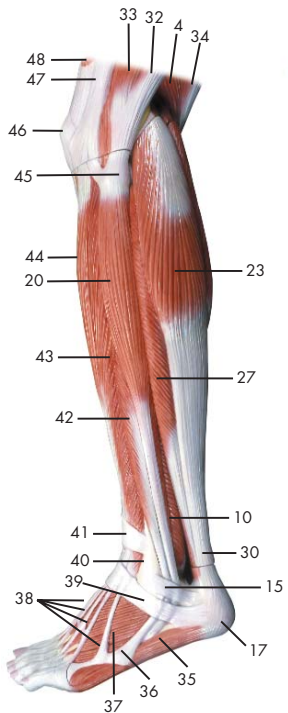
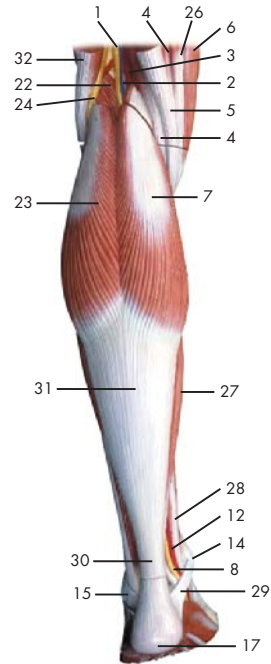
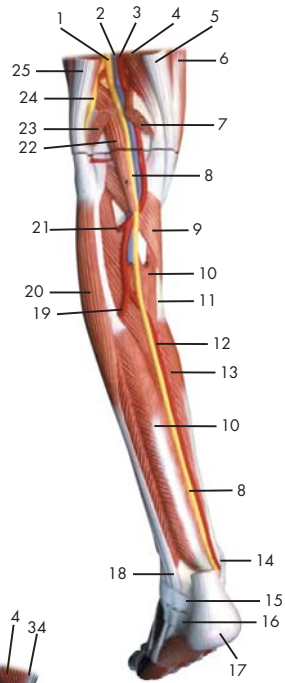
- 1 Femoral nerve
- 2 Femoral artery
- 3 Femoral vein
- 4 Adductor longus muscle
- 5 Gracilis muscle
- 6 Vastus medialis muscle
- 7 Sartorius muscle
- 8 Popliteus muscle
- 9 Tibia (shin bone)
- 10 Flexor digitorum longus muscle
- 11 Transverse ligament of ankle
- 12 Cruciate ligament of ankle
- 13 Abductor hallucis muscle
- 14 Calcaneal tuber
- 15 Posterior tibial artery
- 16 Tibial nerve
- 17 Semimembranosus muscle
- 18 Adductor magnus muscle
- 19 Head of femur (femoral head)
- 20 Rectus femoris muscle
- 21 Patella
- 22 Patellar ligament
- 23 Superficial pes anserinus
- 24 Soleus muscle
- 25 Flexor retinaculum of foot
- 26 Medial malleolus
- 27 Heel tendon
- 28 Medial head of gastrocnemius muscle
- 29 Medial patellar retinaculum
- 30 Semitendinosus muscle
- 31 Gluteus maximus muscle
- 32 Long head of biceps femoris muscle
- 33 Short head of biceps femoris muscle
- 34 Lateral (great) head of gastrocnemius muscle
- 35 Peroneus longus muscle
- 36 Tibialis posterior muscle
- 37 Peroneus brevis muscle
- 38 Extensor digitorum longus muscle (of foot)
- 39 Tibialis anterior muscle
- 40 Vastus lateralis muscle
- 41 Iliotibial tract
- 42 Tensor fasciae latae muscle
- 43 Gluteus medius muscle

English


Deutsch

Muskelbein

- 1 Oberschenkelnerve
- 2 Oberschenkelschlagader
- 3 Oberschenkelvene
- 4 Langer Schenkelanzieher
- 5 Schlankmuskel
- 6 Mittlerer großer Muskel
- 7 Schneidermuskel
- 8 Kniekehlenmuskel
- 9 Schienbein
- 10 Langer Zehenbeuger
- 11 Retinaculum musculorum extensorum superius
- 12 Retinaculum musculorum extensorum inferius
- 13 Abzieher der Großzehe
- 14 Fersenbeinhöcker
- 15 Hintere Schienbeinschlagader
- 16 Schienbeinnerv
- 17 Halbmembranöser Muskel
- 18 Großer Schenkelanzieher
- 19 Oberschenkelkopf
- 20 Gerader Oberschenkelmuskel
- 21 Kniescheibe
- 22 Kniescheibenband
- 23 Oberflächlicher "Gänsefuß",
Ansatz des M. semitendinosus
- 24 Schollenmuskel
- 25 Pes, retinaculum musculorum flexorum
- 26 Innenknöchel
- 27 Achillessehne
- 28 Mittlerer Kopf des Zwillingswadenmuskels
- 29 Retinaculum patellae mediale
- 30 Halbsehniger Muskel
- 31 Großer Gesäßmuskel
- 32 Zweiköpfiger Oberschenkelmuskel,
langer Kopf
- 33 Zweiköpfiger Oberschenkelmuskel,
kurzer Kopf
- 34 Seitlicher Kopf des Zwillingswadenmuskels
- 35 Langer Wadenbeinmuskel
- 36 Hinterer Schienbeinmuskel
- 37 Kurzer Wadenbeinmuskel
- 38 Langer Zehenstrecker
- 39 Vorderer Schienbeinmuskel
- 40 Seitlicher großer Muskel
- 41 Faszienspanner des Beines
- 42 Spanner der Oberschenkelbinde
- 43 Mittlerer Gesäßmuskel



- | | |
|---|-------------------------------------|
| 1 N. ischiadicus | 49 M. vastus medialis |
| 2 V. poplitea | 50 M. quadratus femoris, tendo |
| 3 A. poplitea | 51 Corpus adiposum infrapatellare |
| 4 M. semimembranosus | 52 Ligamentum patellae |
| 5 M. semitendinosus, tendo | 53 Pes anserinus superficialis |
| 6 M. sartorius | 54 M. tibialis anterior, tendo |
| 7 M. gastrocnemius, caput mediale | 55 Hallux |
| 8 N. tibialis | 56 M. tibialis posterior, tendo |
| 9 M. popliteus | 57 A. plantaris medialis |
| 10 M. tibialis posterior | 58 N. plantaris medialis |
| 11 Tibia | 59 M. flexor hallucis longus, tendo |
| 12 A. tibialis posterior | 60 Retinaculum patellae mediale |
| 13 M. flexor digitorum longus pedis | |
| 14 Malleolus medialis | |
| 15 Retinaculum musculorum peroneorum superius | |
| 16 Retinaculum musculorum peroneorum inferius | |
| 17 Tuber calcanei | |
| 18 M. peroneus longus, tendo | |
| 19 A. fibularis | |
| 20 M. peroneus longus | |
| 21 A. tibialis anterior | |
| 22 M. plantaris | |
| 23 M. gastrocnemius, caput laterale | |
| 24 N. fibularis communis | |
| 25 M. biceps femoris, tendo | |
| 26 M. gracilis, tendo | |
| 27 M. soleus | |
| 28 M. flexor digitorum longus, tendo | |
| 29 Pes, retinaculum musculorum flexorum | |
| 30 Tendo calcanei | |
| 31 M. gastrocnemius, tendo | |
| 32 M. biceps femoris | |
| 33 M. vastus lateralis | |
| 34 M. semitendinosus | |
| 35 M. abductor digiti minimi pedis | |
| 36 M. peroneus brevis, tendo | |
| 37 M. extensor digitorum brevis pedis | |
| 38 M. extensor digitorum longus pedis, tendines | |
| 39 Retinaculum musculorum extensorum inferius | |
| 40 Malleolus lateralis | |
| 41 Retinaculum musculorum extensorum superius | |
| 42 M. peroneus brevis | |
| 43 M. extensor digitorum longus pedis | |
| 44 M. tibialis anterior | |
| 45 Fibula, caput | |
| 46 Patella | |
| 47 Tractus iliotibialis | |
| 48 M. rectus femoris | |



Muscular lower leg with knee

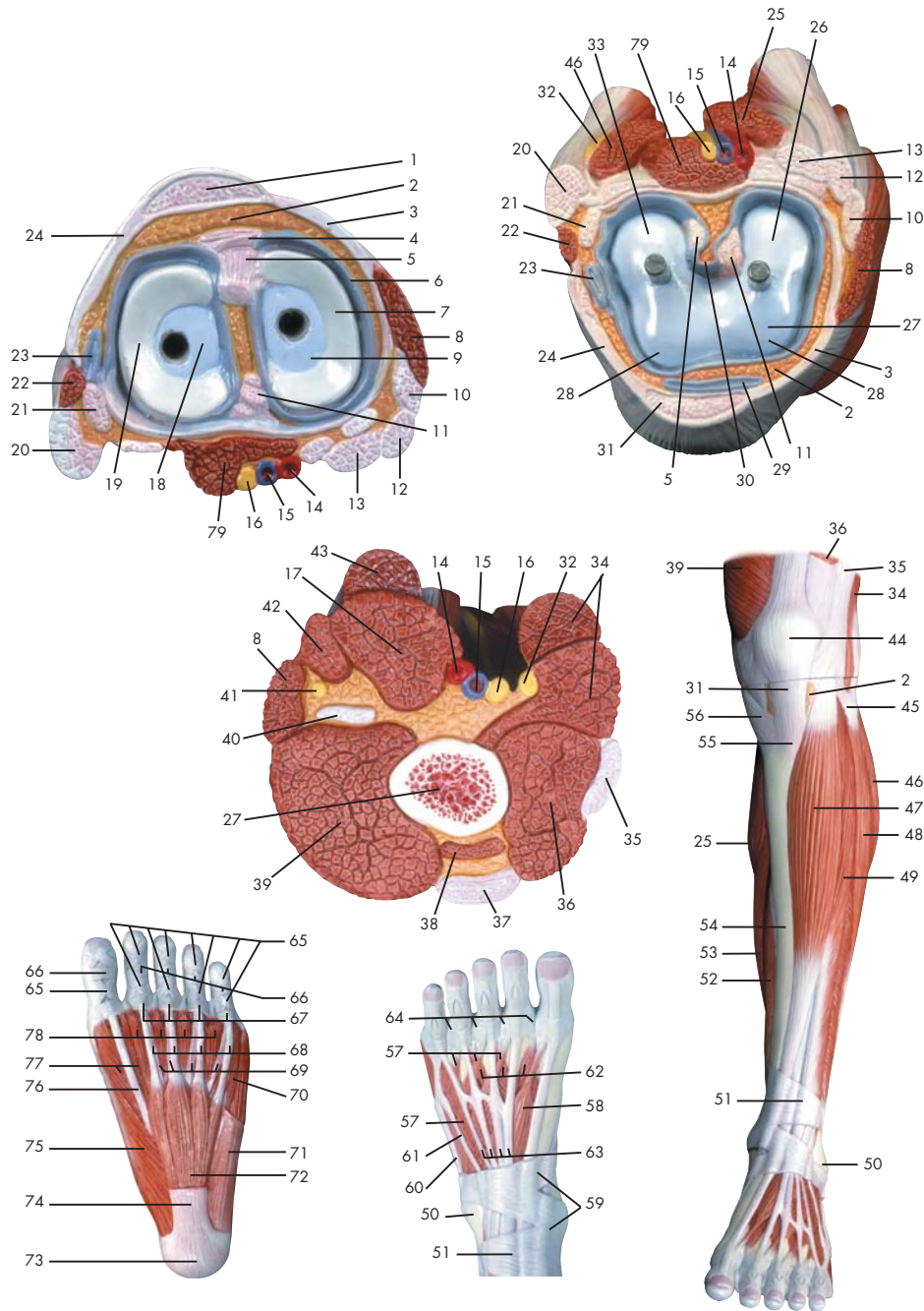
English

- 1 Sciatic nerve
- 2 Popliteal vein
- 3 Popliteal artery
- 4 Semimembranosus muscle
- 5 Tendon of semitendinosus muscle
- 6 Sartorius muscle
- 7 Medial head of gastrocnemius muscle
- 8 Tibial nerve
- 9 Popliteus muscle
- 10 Tibialis posterior muscle
- 11 Tibia (shin bone)
- 12 Posterior tibial artery
- 13 Flexor digitorum longus muscle
- 14 Medial malleolus
- 15 Superior peroneal retinaculum
- 16 Inferior peroneal retinaculum
- 17 Calcaneal tuber
- 18 Tendon of peroneus longus muscle
- 19 Fibular artery (peroneal artery)
- 20 Peroneus longus muscle
- 21 Anterior tibial artery
- 22 Plantaris muscle
- 23 Lateral (great) head of gastrocnemius muscle
- 24 Common fibular nerve
- 25 Tendon of biceps femoris muscle
- 26 Tendon of gracilis muscle
- 27 Soleus muscle
- 28 Tendon of flexor digitorum longus muscle
- 29 Flexor retinaculum of foot
- 30 Heel tendon
- 31 Tendon of gastrocnemius muscle
- 32 Biceps femoris muscle
- 33 Vastus lateralis muscle
- 34 Semitendinosus muscle
- 35 Abductor digiti minimi muscle of foot
- 36 Tendon of peroneus brevis muscle
- 37 Extensor digitorum brevis muscle of foot
- 38 Tendons of extensor digitorum longus pedis muscle
- 39 Cruciate ligament of ankle
- 40 Lateral malleolus
- 41 Transverse ligament of ankle
- 42 Peroneus brevis muscle
- 43 Extensor digitorum longus muscle (of foot)
- 44 Tibialis anterior muscle
- 45 Head of fibula
- 46 Patella
- 47 Iliotibial tract
- 48 Rectus femoris muscle
- 49 Vastus medialis muscle
- 50 Tendon of quadratus femoris muscle
- 51 Adipose body of patella
- 52 Patellar tendon
- 53 Superficial pes anserinus
- 54 Tibialis anterior muscle, tendon
- 55 Great toe
- 56 Tendon of tibialis posterior muscle
- 57 Medial plantar artery
- 58 Medial plantar nerve
- 59 Tendon of flexor hallucis longus muscle
- 60 Medial patellar retinaculum

Deutsch

Muskelunterschenkel mit Knie

- 1 Ischiasnerv
- 2 Kniekehlevene
- 3 Kniekehlschlagader
- 4 Halbmembranöser Muskel
- 5 M. semitendinosus, tendo
- 6 Schneidermuskel
- 7 Mittlerer Kopf des Zwillingswadenmuskels
- 8 Schienbeinnerv
- 9 Kniekehlenmuskel
- 10 Hinterer Schienbeinmuskel
- 11 Schienbein
- 12 Hintere Schienbeinschlagader
- 13 Langer Zehenbeuger
- 14 Innenknöchel
- 15 Retinaculum musculorum peroneorum superius
- 16 Retinaculum musculorum peroneorum inferius
- 17 Fersenbeinhöcker
- 18 M. peroneus longus, tendo
- 19 Wadenbeinschlagader
- 20 Langer Wadenbeinmuskel
- 21 Vordere Schienbeinschlagader
- 22 Sohlenspanner
- 23 Seitlicher Kopf des Zwillingswadenmuskels
- 24 Gemeinsamer Wadenbeinnerv
- 25 M. biceps femoris, tendo
- 26 Sehne des Schlankmuskels
- 27 Schollenmuskel
- 28 M. flexor digitorum longus, tendo
- 29 Pes, retinaculum musculorum flexorum
- 30 Achillessehne
- 31 Sehne des Wadenmuskels
- 32 Zweiköpfiger Oberschenkelmuskel
- 33 Seitlicher großer Muskel
- 34 Halbsehniger Muskel
- 35 Kleinzehenabzieher
- 36 M. peroneus brevis, tendo
- 37 Kurzer Zehenstrecker
- 38 Sehnen des langen Zehenstreckers
- 39 Retinaculum musculorum extensorum inferius
- 40 Außenknöchel
- 41 Retinaculum musculorum extensorum superius
- 42 Kurzer Wadenbeinmuskel
- 43 Langer Zehenstrecker
- 44 Vorderer Schienbeinmuskel
- 45 Wadenbeinkopf
- 46 Kniescheibe
- 47 Faszienspanner des Beines
- 48 Gerader Oberschenkelmuskel
- 49 Mittlerer großer Muskel
- 50 Sehne des viereckigen Oberschenkelmuskel
- 51 Corpus adiposum infrapatellare
- 52 Patellarsehne
- 53 Oberflächlicher "Gänsefuß", Ansatz des M. semitendinosus
- 54 M. tibialis anterior, tendo
- 55 Großzehe
- 56 Hinterer Schienbeinmuskel, Sehne
- 57 Mittlere Fußsohlenschlagader
- 58 N. plantaris medialis
- 59 Sehne des langen Großzehenbeugers
- 60 Retinaculum patellae mediale



- 1 Ligamentum patellae
- 2 Corpus adiposum infrapatellare
- 3 Retinaculum patellae mediale
- 4 Lig. transversum genus
- 5 Lig. cruciatum anterius
- 6 Membrana synovialis
- 7 Meniscus medialis
- 8 M. sartorius
- 9 Tibia, condylus medialis
- 10 M. gracilis, tendo
- 11 Lig. cruciatum posterius
- 12 M. semitendinosus, tendo
- 13 M. semimembranosus, tendo
- 14 A. poplitea
- 15 V. poplitea
- 16 N. tibialis
- 17 M. semimembranosus
- 18 Tibia, condylus lateralis
- 19 Meniscus lateralis
- 20 M. biceps femoris, caput longum
- 21 M. popliteus, tendo
- 22 M. biceps femoris, caput breve
- 23 Recessus subpopliteus
- 24 Retinaculum patellae laterale
- 25 M. gastrocnemius, caput mediale
- 26 Femur, condylus medialis
- 27 Femur
- 28 Femur, facies patellaris
- 29 Bursa infrapatellaris profunda
- 30 Plica synovialis infrapatellaris
- 31 Lig. patellae
- 32 N. fibularis communis
- 33 Femur, condylus lateralis
- 34 M. biceps femoris
- 35 Tractus iliotibialis
- 36 M. vastus lateralis
- 37 M. rectus femoris, tendo
- 38 M. vastus intermedius
- 39 M. vastus medialis
- 40 M. adductor magnus, Tendo
- 41 N. saphenus
- 42 M. gracilis
- 43 M. semitendinosus
- 44 Patella
- 45 Fibula, caput
- 46 M. gastrocnemius, caput laterale
- 47 M. tibialis anterior
- 48 M. peroneus longus
- 49 M. extensor digitorum longus pedis
- 50 Malleolus lateralis
- 51 Retinaculum musculorum extensorum superius
- 52 M. flexor digitorum longus pedis
- 53 M. soleus
- 54 Tibia
- 55 Tibia, tuberositas
- 56 M. sartorius, tendo
- 57 M. extensor digitorum brevis pedis
- 58 M. extensor hallucis brevis
- 59 Retinaculum musculorum extensorum inferius
- 60 M. peroneus brevis, tendo
- 61 M. peroneus tertius, tendo
- 62 Mm. interossei dorsales pedis
- 63 M. extensor digitorum longus pedis, tendines
- 64 Lig. metatarsale transversum superficiale
- 65 Vaginae fibrosae, pars cruciforme
- 66 Vaginae fibrosae, pars annularis
- 67 Lig. metacarpale transversum superficiale
- 68 M. flexor digitorum brevis, tendo
- 69 M. flexor digitorum longus, tendo
- 70 M. flexor digiti minimi brevis pedis
- 71 M. abductor digiti minimi pedis
- 72 M. flexor digitorum brevis pedis
- 73 Tuber calcanei
- 74 Aponeurosis plantaris
- 75 M. abductor hallucis
- 76 M. flexor hallucis longus, tendo
- 77 M. flexor hallucis brevis
- 78 M. lumbricalis pedis
- 79 M. plantaris

Muscular lower leg with knee

English

1 Patellar tendon	49 Extensor digitorum longus muscle (of foot)
2 Adipose body of patella	50 Lateral malleolus
3 Medial patellar retinaculum	51 Transverse ligament of ankle
4 Transverse ligament of knee	52 Flexor digitorum longus muscle
5 Anterior cruciate ligament	53 Soleus muscle
6 Synovial membrane	54 Tibia (shin bone)
7 Medial meniscus of knee	55 Tuberosity of tibia
8 Sartorius muscle	56 Tendon of sartorius muscle
9 Medial condyle of tibia	57 Extensor digitorum brevis muscle of foot
10 Tendon of gracilis muscle	58 Extensor hallucis brevis muscle
11 Posterior cruciate ligament	59 Cruciate ligament of ankle
12 Tendon of semitendinosus muscle	60 Tendon of peroneus brevis muscle
13 Tendon of semimembranosus muscle	61 Tendon of peroneus tertius muscle
14 Popliteal artery	62 Dorsal interosseous muscles of foot
15 Popliteal vein	63 Tendons of extensor digitorum longus pedis muscle
16 Tibial nerve	64 Superficial transverse metatarsal ligament
17 Semimembranosus muscle	65 Cruciform part of fibrous tendon sheaths
18 Lateral condyle of tibia	66 Annular part of fibrous tendon sheaths
19 Lateral meniscus of knee	67 Superficial transverse metacarpal ligament
20 Long head of biceps femoris muscle	68 Tendon of flexor digitorum brevis muscle
21 Tendon of popliteal muscle	69 Tendon of flexor digitorum longus muscle
22 Short head of biceps femoris muscle	70 Flexor digiti minimi brevis muscle of foot
23 Subpopliteal recess	71 Abductor digiti minimi muscle of foot
24 Lateral patellar retinaculum	72 Flexor digitorum brevis muscle
25 Medial head of gastrocnemius muscle	73 Calcaneal tuber
26 Medial condyle of femur	74 Plantar aponeurosis
27 Femur (thigh bone)	75 Abductor hallucis muscle
28 Patellar surface of femur	76 Tendon of flexor hallucis longus muscle
29 Deep infrapatellar bursa	77 Flexor hallucis brevis muscle
30 Infrapatellar synovial fold	78 Lumbrical muscle of foot
31 Patellar ligament	79 Plantaris muscle
32 Common fibular nerve	
33 Lateral condyle of femur	
34 Biceps femoris muscle	
35 Iliotibial tract	
36 Vastus lateralis muscle	
37 Tendon of rectus femoris muscle	
38 Vastus intermedius muscle	
39 Vastus medialis muscle	
40 Tendon of adductor magnus muscle	
41 Saphenous nerve	
42 Gracilis muscle	
43 Semitendinosus muscle	
44 Patella	
45 Head of fibula	
46 Lateral (great) head of gastrocnemius muscle	
47 Tibialis anterior muscle	
48 Peroneus longus muscle	

Deutsch

Muskelunterschenkel mit Knie

1 Patellarsehne	47 Vorderer Schienbeinmuskel
2 Corpus adiposum infrapatellare	48 Langer Wadenbeinmuskel
3 Retinaculum patellae mediale	49 Langer Zehenstrecker
4 Lig. transversum genus	50 Außenknöchel
5 Vorderes Kreuzband	51 Retinaculum musculorum extensorum superius
6 Membrana synovialis	52 Langer Zehenbeuger
7 Innenmeniskus	53 Schollenmuskel
8 Schneidermuskel	54 Schienbein
9 Mittlerer Knorren (Schienbein)	55 Rauhgigkeit des Schienbeins
10 Sehne des Schlankmuskels	56 Sehne des Schneidermuskels
11 Hinteres Kreuzband	57 Kurzer Zehenstrecker
12 M. semitendinosus, tendo	58 Kurzer Großzehenstrecker
13 Sehne des halbmembranösen Muskels	59 Retinaculum musculorum extensorum inferius
14 Kniekehlschlagader	60 M. peroneus brevis, tendo
15 Kniekehlnvene	61 M. peroneus tertius, tendo
16 Schienbeinnerv	62 Zwischenknochenmuskeln (Fußrücken)
17 Halbmembranöser Muskel	63 Sehnen des langen Zehenstreckers
18 Seitliche Knorren (Schienbein)	64 Lig. metatarsale transversum superficiale
19 Außenmeniskus	65 Kreuzförmiger Anteil der Sehnenscheiden
20 Zweiköpfiger Oberschenkelmuskel, langer Kopf	66 Ringförmiger Anteil der Sehnenscheiden
21 Sehne des Kniekehlmuskels	67 Lig. metacarpale transversum superficiale
22 Zweiköpfiger Oberschenkelmuskel, kurzer Kopf	68 M. flexor digitorum brevis, tendo
23 Recessus subpopliteus	69 M. flexor digitorum longus, tendo
24 Retinaculum patellae laterale	70 Kurzer Kleinzehenbeuger
25 Mittlerer Kopf des Zwillingswadenmuskels	71 Kleinzehenabzieher
26 Mittlerer Knorren (Oberschenkel)	72 Kurzer Zehenbeuger
27 Oberschenkelknochen	73 Fersenbeinhöcker
28 Femur, facies patellaris	74 Sehnenplatte der Fußsohle
29 Bursa infrapatellaris profunda	75 Abzieher der Großzehe
30 Infrapatellare Synovialfalte	76 Sehne des langen Großzehenbeugers
31 Kniescheibenband	77 Kurzer Großzehenbeuger
32 Gemeinsamer Wadenbeinnerv	78 Spulmuskel des Fußes
33 Seitlicher Knorren (Oberschenkel)	79 Sohlenspanner
34 Zweiköpfiger Oberschenkelmuskel	
35 Faszienpanner des Beines	
36 Seitlicher großer Muskel	
37 Sehne des geraden Schenkelmuskels	
38 M. vastus intermedius	
39 Mittlerer großer Muskel	
40 Sehne des großen Anziehers	
41 Verborgener Nerv	
42 Schlankmuskel	
43 Halbsehniger Muskel	
44 Kniescheibe	
45 Wadenbeinkopf	
46 Seitlicher Kopf des Zwillingswadenmuskels	



3B Scientific Products

www.3bscientific.com

Copyright 2001 For instruction manual and design of product:
3B Scientific GmbH