

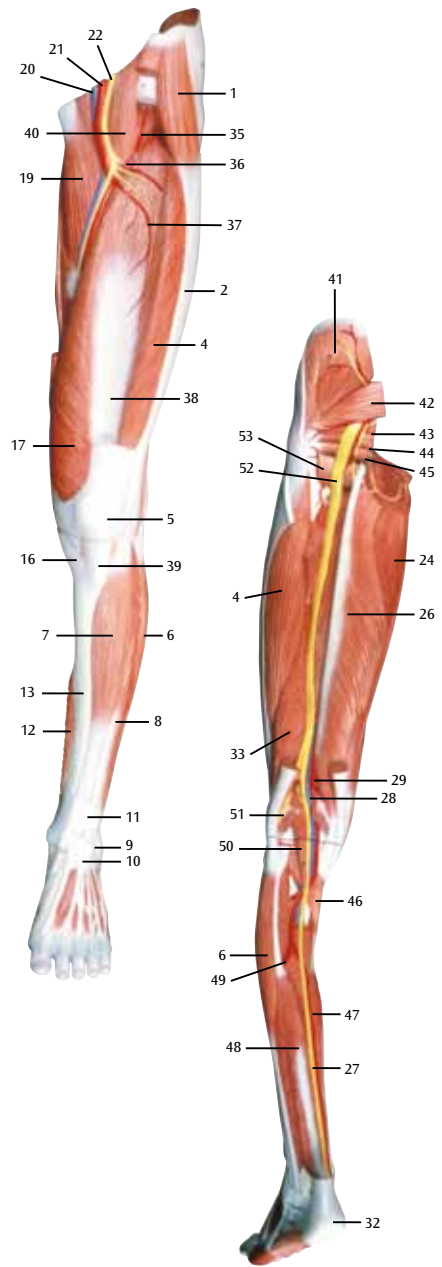
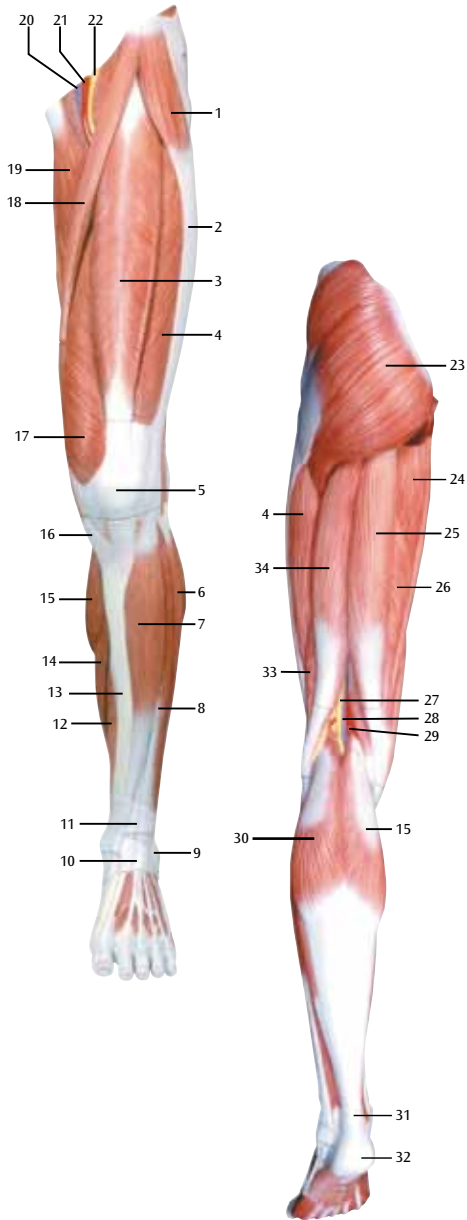


*...going one step further*



**M21**

(1000352)



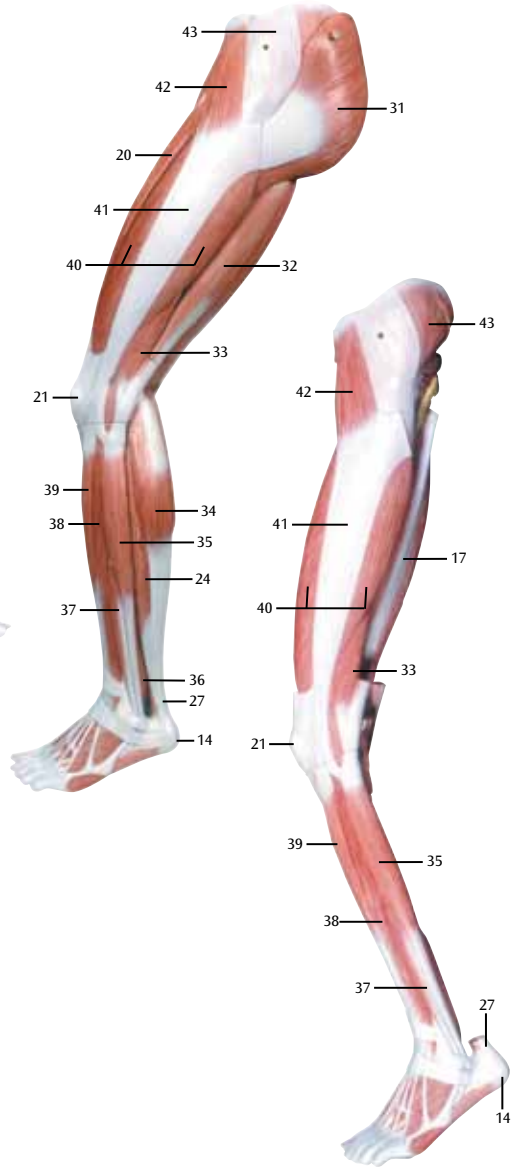
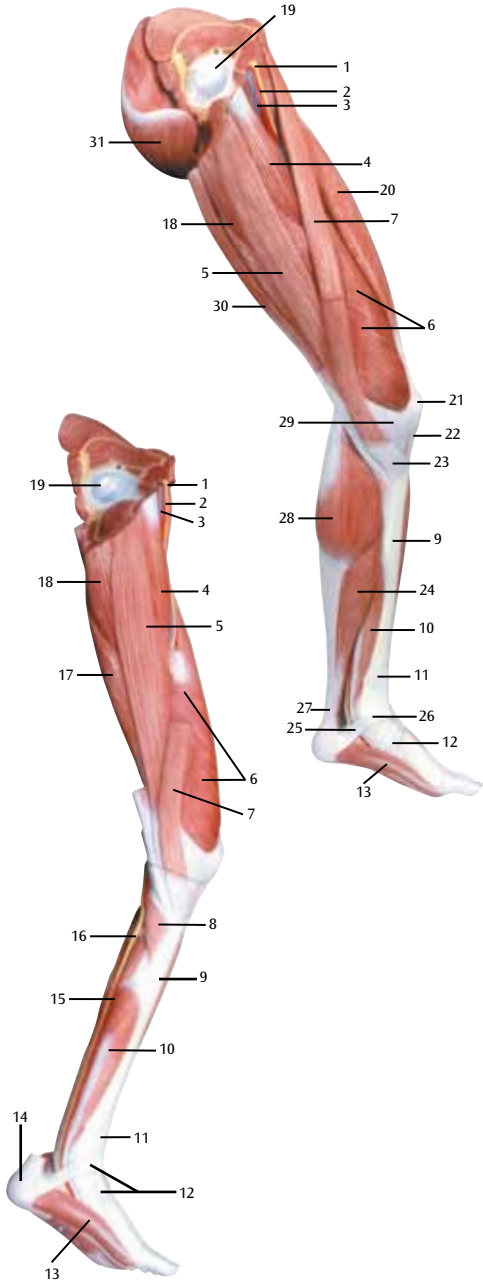
## **Latin**

- 1 M. tensor fasciae latae
- 2 Tractus iliotibialis
- 3 M. rectus femoris
- 4 M. vastus lateralis
- 5 Patella
- 6 M. fibularis longus (M. peroneus longus)
- 7 M. tibialis anterior
- 8 M. extensor digitorum longus pedis
- 9 Malleolus lateralis
- 10 Retinaculum musculorum extensorum inferius
- 11 Retinaculum musculorum extensorum superius
- 12 M. flexor digitorum longus pedis
- 13 Tibia
- 14 M. soleus
- 15 M. gastrocnemius, caput mediale
- 16 M. sartorius, tendo
- 17 M. vastus medialis
- 18 M. sartorius
- 19 M. adductor longus
- 20 V. femoralis
- 21 A. femoralis
- 22 N. femoralis
- 23 M. gluteus maximus
- 24 M. adductor magnus
- 25 M. semitendinosus
- 26 M. semimembranosus
- 27 N. tibialis
- 28 V. poplitea
- 29 A. poplitea
- 30 M. gastrocnemius, caput laterale
- 31 Tendo calcanei
- 32 Tuber calcanei
- 33 M. biceps femoris, caput breve
- 34 M. biceps femoris, caput longum
- 35 A. circumflexa femoris lateralis, ramus ascendens
- 36 A. circumflexa femoris lateralis
- 37 A. circumflexa femoris lateralis, ramus descendens
- 38 M. vastus intermedius
- 39 Lig. patellae
- 40 M. iliopsoas
- 41 M. gluteus medius
- 42 M. piriformis
- 43 M. gemellus superior
- 44 M. obturatorius internus
- 45 M. gemellus inferior
- 46 M. popliteus
- 47 A. tibialis posterior
- 48 M. flexor hallucis longus
- 49 N. fibularis communis (N. peroneus communis)
- 50 M. plantaris
- 51 N. fibularis communis (N. peroneus communis)
- 52 N. ischiadicus
- 53 M. quadratus femoris

# Muscular leg

English

- 1 Tensor fasciae latae muscle
- 2 Iliotibial tract
- 3 Rectus femoris muscle
- 4 Vastus lateralis muscle
- 5 Patella (Knee cap)
- 6 Fibularis longus muscle (Peroneus longus muscle)
- 7 Tibialis anterior muscle
- 8 Extensor digitorum longus muscle of foot
- 9 Lateral malleolus
- 10 Cruciate ligament of ankle
- 11 Transverse ligament of ankle
- 12 Flexor digitorum longus muscle of foot
- 13 Tibia (Shin bone)
- 14 Soleus muscle
- 15 Gastrocnemius muscle, medial head
- 16 Sartorius muscle, tendon
- 17 Vastus medialis muscle
- 18 Sartorius muscle
- 19 Adductor longus muscle
- 20 Femoral vein
- 21 Femoral artery
- 22 Femoral nerve
- 23 Gluteus maximus muscle
- 24 Adductor magnus muscle
- 25 Semitendinosus muscle
- 26 Semimembranosus muscle
- 27 Tibial nerve
- 28 Popliteal vein
- 29 Popliteal artery
- 30 Gastrocnemius muscle, lateral (great)
- 31 Heel tendon
- 32 Calcaneus, tuber
- 33 Biceps femoris muscle, short head
- 34 Biceps femoris muscle, long head
- 35 Lateral circumflex femoral artery, ascending branch
- 36 Lateral circumflex femoral artery
- 37 Lateral circumflex femoral artery, descending branch
- 38 Vastus intermedius muscle
- 39 Patellar ligament
- 40 Iliopsoas muscle
- 41 Gluteus medius muscle
- 42 Piriformis muscle
- 43 Gemellus superior muscle
- 44 Obturator internus muscle
- 45 Gemellus inferior muscle
- 46 Popliteus muscle
- 47 Posterior tibial artery
- 48 Flexor hallucis longus muscle
- 49 Common fibular nerve (Common peroneal nerve)
- 50 Plantaris muscle
- 51 Common fibular nerve (Common peroneal nerve)
- 52 Sciatic nerve
- 53 Quadratus femoris muscle



## **Latin**

- 1 N. femoralis
- 2 A. femoralis
- 3 V. femoralis
- 4 M. adductor longus
- 5 M. gracilis
- 6 M. vastus medialis
- 7 M. sartorius
- 8 M. popliteus
- 9 Tibia
- 10 M. flexor digitorum longus pedis
- 11 Retinaculum musculorum extensorum superius
- 12 Retinaculum musculorum extensorum inferius
- 13 M. abductor hallucis
- 14 Calcaneus, tuber
- 15 A. tibialis posterior
- 16 N. tibialis
- 17 M. semimembranosus
- 18 M. adductor magnus
- 19 Femur, caput
- 20 M. rectus femoris
- 21 Patella
- 22 Lig. patellae
- 23 Pes anserinus superficialis
- 24 M. soleus
- 25 Retinaculum musculorum flexorum pedis
- 26 Malleolus medialis
- 27 Tendo calcanei
- 28 M. gastrocnemius, caput mediale
- 29 Retinaculum patellae mediale
- 30 M. semitendinosus
- 31 M. gluteus maximus
- 32 M. biceps femoris, caput longum
- 33 M. biceps femoris, caput breve
- 34 M. gastrocnemius, caput laterale
- 35 M. fibularis longus (M. peroneus longus)
- 36 M. fibularis brevis (M. peroneus brevis)
- 37 M. fibularis brevis (M. peroneus brevis)
- 38 M. extensor digitorum longus pedis
- 39 M. tibialis anterior
- 40 M. vastus lateralis
- 41 Tractus iliotibialis
- 42 M. tensor fasciae latae
- 43 M. gluteus medius

# Muscular leg

English

- 1 Femoral nerve
- 2 Femoral artery
- 3 Femoral vein
- 4 Adductor longus muscle
- 5 Gracilis muscle
- 6 Vastus medialis muscle
- 7 Sartorius muscle
- 8 Popliteus muscle
- 9 Tibia (Shin bone)
- 10 Flexor digitorum longus muscle of foot
- 11 Transverse ligament of ankle
- 12 Cruciate ligament of ankle
- 13 Abductor hallucis muscle
- 14 Calcaneus, tuber
- 15 Posterior tibial artery
- 16 Tibial nerve
- 17 Semimembranosus muscle
- 18 Adductor magnus muscle
- 19 Head of femur (Femoral head)
- 20 Rectus femoris muscle
- 21 Patella (Knee cap)
- 22 Patellar ligament
- 23 Superficial pes anserinus
- 24 Soleus muscle
- 25 Flexor retinaculum of foot
- 26 Medial malleolus
- 27 Heel tendon
- 28 Gastrocnemius muscle, medial head
- 29 Medial patellar retinaculum
- 30 Semitendinosus muscle
- 31 Gluteus maximus muscle
- 32 Biceps femoris muscle, long head
- 33 Biceps femoris muscle, short head
- 34 Gastrocnemius muscle, lateral (great) head
- 35 Peroneus longus muscle
- 36 Tibialis posterior muscle
- 37 Tibialis posterior muscle
- 38 Extensor digitorum longus muscle
- 39 Tibialis anterior muscle
- 40 Vastus lateralis muscle
- 41 Iliotibial tract
- 42 Tensor fasciae latae muscle
- 43 Gluteus medius muscle