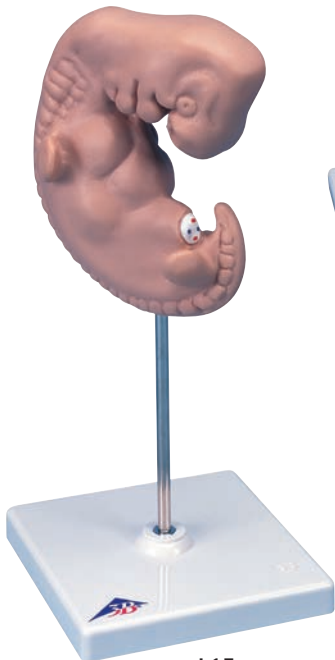
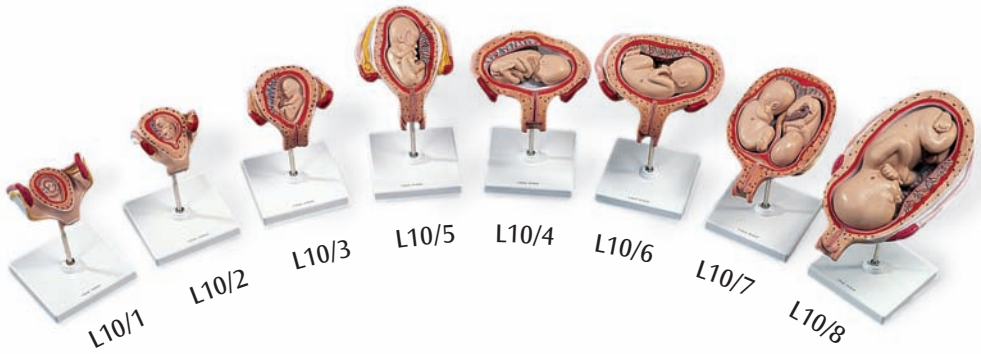
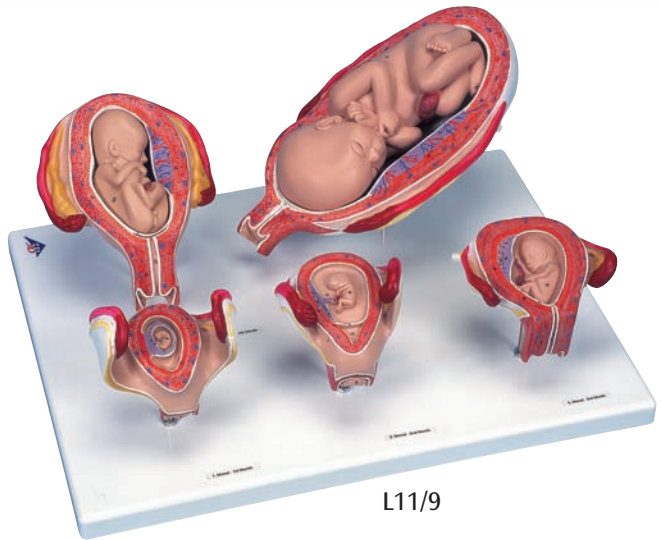




...going one step further



L15



L11/9

**L10, L11, L11/9, L15**

**Latin**

**L10: L10/1, L10/2, L10/3, L10/4, L10/5, L10/6, L10/7, L10/8**

**L11: L10, L15**

**L11/9: L10/1, L10/2, L10/3, L10/5, L10/8**

L10/1, L10/2, L10/3, L10/4, L10/5, L10/6, L10/7, L10/8

- 1 Vagina
- 2 Cervix uteri
- 3 Tuba uterina
- 4 Fimbriae tubae uterinae
- 5 Ovarium
- 6 Lig. latum uteri
- 7 Uterus
- 8 Placenta
- 8a Placenta, pars fetalis
- 8b Placenta, pars uterina
- 9 Funiculus umbilicalis
- 10 Embryo/fetus
- 11 Amnion, chorion, decidua capsularis
- 12 Amnion
- 13 Cavitas uteri
- 14 Decidua parietalis
- 15 Lig. teres uteri

L15

- 1 Encephalon (primordium)
- 1a Telencephalon (primordium)
- 1b Diencephalon (primordium)
- 1c Mesencephalon (primordium)
- 1d Cerebellum (primordium)
- 1e Rhombencephalon (primordium)
- 2 Nasus (primordium)
- 3 Oculus (primordium)
- 4 Maxilla (primordium)
- 4a Auris (primordium)
- 5 Arcus branchialis
- 5a Arcus mandibularis (Arcus branchialis I)
- 5b Arcus hyoideus (Arcus branchialis II)
- 5c Arcus pharyngobranchialis (Arcus branchialis III)
- 5d Arcus branchialis IV
- 6 Cor (primordium)
- 6a Atrium cordis (primordium)
- 6b Ventriculus cordis (primordium)
- 7 Hepar (primordium)
- 8 Membrum superius (primordium)
- 9 Membrum inferius (primordium)
- 10 Vertebra (primordium)

# Pregnancy Series

English

**L10 includes: L10/1, L10/2, L10/3, L10/4, L10/5, L10/6, L10/7, L10/8**

**L11 includes: L10, L15**

**L11/9 includes: L10/1, L10/2, L10/3, L10/5, L10/8**

- L10/1 Uterus with 1st month embryo
- L10/2 Uterus with 2nd month embryo
- L10/3 Uterus with 3rd month fetus
- L10/4 Uterus with 4th month fetus (transverse position)
- L10/5 Uterus with 5th month fetus (breech position)
- L10/6 Uterus with 5th month fetus (transverse position)
- L10/7 Uterus with 5th month twin fetuses (normal position)
- L10/8 Uterus with 7th month fetus (normal position)
  - 1 Vagina
  - 2 Uterine neck (cervix)
  - 3 Uterine tube (fallopian tube)
  - 4 Fimbriae of uterine tube
  - 5 Ovary
  - 6 Broad ligament of uterus
  - 7 Uterus
  - 8 Placenta
  - 8a Placenta, part of the child
  - 8b Placenta, part of the mother
  - 9 Umbilical cord
  - 10 Embryo or fetus
  - 11 Fetal integument (amnion, chorion, decidua capsularis)
  - 12 Amnion (embryonic membrane)
  - 13 Uterine cavity
  - 14 Decidua parietalis
  - 15 Round ligament of uterus

**L15 Giant embryo approx. 4 weeks old, 25 times life-size**

- 1 Primordium of the brain
  - 1a Primordium of the telencephalon
  - 1b Primordium of the diencephalon
  - 1c Primordium of the mesencephalon
  - 1d Primordium of the cerebellum (rhombic lips)
  - 1e Primordium of the rhombencephalon
- 2 Primordium of the nose (olfactory pit)
- 3 Primordium of the eyes (ocular cups, lenticular vesicles)
- 4 Primordium of the upper jaw
  - 4a Primordium of the ears (otic pits)
- 5 Branchial arches
  - 5a Mandibular arch (1st branchial arch)
  - 5b Hyoid arch (2nd branchial arch)
  - 5c 3rd branchial arch
  - 5d 4th branchial arch
- 6 Primordium of the heart
  - 6a Primordium of the atriums
  - 6b Primordium of the ventricles
- 7 Primordium of the liver
- 8 Upper (anterior) limb buds
- 9 Lower (posterior) limb buds
- 10 Primordium of vertebra (4th somite)