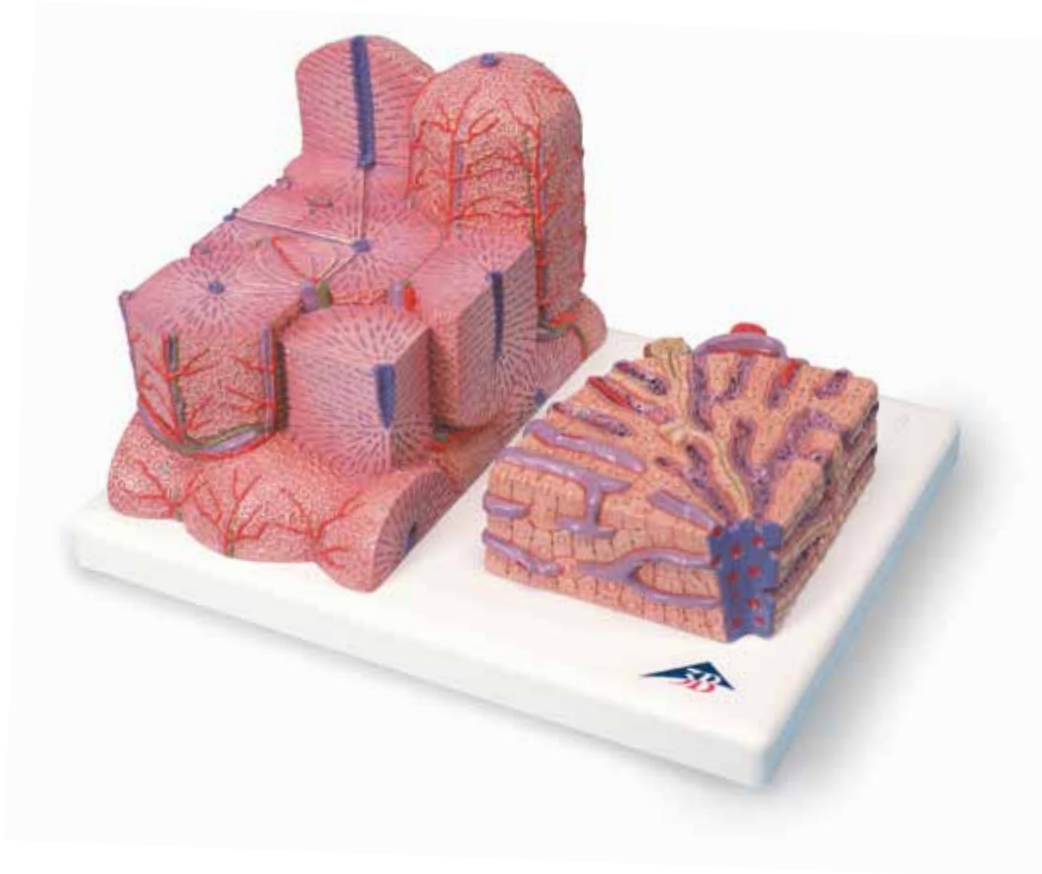




*...going one step further*




**K24**

(1000312)

**Latin**

- 1 Vena centralis
- 2 Lobulus portalis
- 3 Canalis portalis
- 4 Acinus hepatis
- 5 Zona 1
- 6 Zona 2
- 7 Zona 3
- 8 Lobulus hepatis
- 9 Ductus interlobularis bilifer
- 10 Arteria interlobularis
- 11 Vena interlobularis
- 12 Cell of Kupffer
- 13 Hepaticocytus
- 14 Terminal bile duct (Herring's canal)
- 15 Vasa sinusoidea
- 16 Canaliculi biliferi



# 3B MICROanatomy™ Liver

English

This 2-part model shows a highly magnified diagrammatic view of a section of the liver. It illustrates the structure of the functional and structural components of the liver in two different enlargements. The left part of the model shows a section of the liver that comprises several liver lobules. The important morphological and functional regions are depicted on various levels: The central vein is at the center of the classic liver lobule. Located at the center of the portal liver lobule is the portal canal with the interlobular artery and vein and an interlobular bile duct (hepatic triad, Glisson's triad). The liver acinus consists of three zones and its axis is defined by one side branch each of the interlobular artery and of the interlobular vein. The right part of the model is a highly magnified view of the sectioned liver lobule on the left.

- 1 Central vein
- 2 Portal liver lobule
- 3 Portal canal
- 4 Liver acinus
- 5 Zone 1
- 6 Zone 2
- 7 Zone 3
- 8 Classic liver lobule
- 9 Interlobular bile duct
- 10 Interlobular artery
- 11 Interlobular vein
- 12 Cell of Kupffer
- 13 Hepatocyte
- 14 Terminal bile duct (Herring's canal)
- 15 Liver sinusoids
- 16 Bile canaliculi

