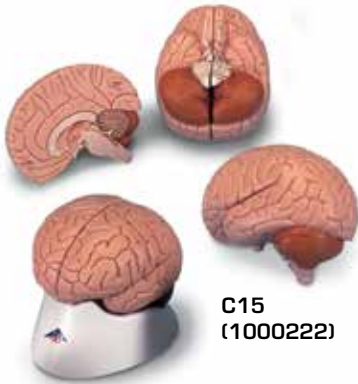
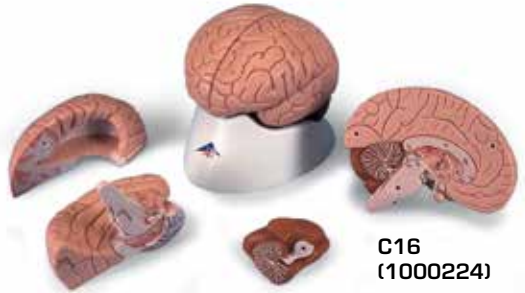



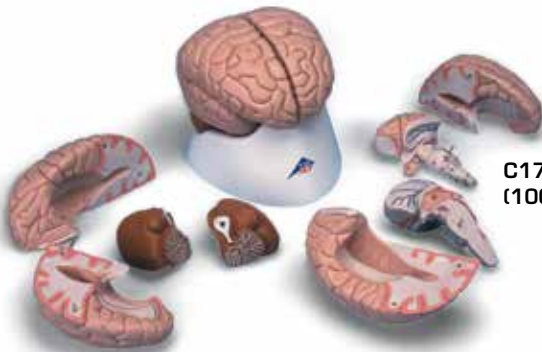
...going one step further



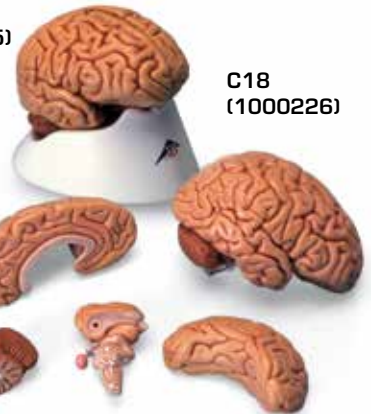
C15
(1000222)



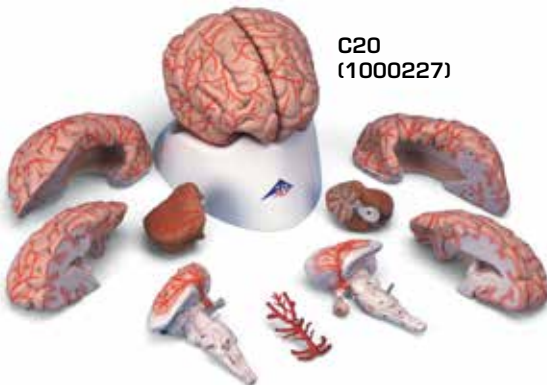C16
(1000224)



C17
(1000225)



C18
(1000226)



C20
(1000227)

**C15, C16,
C17, C18, C20**

(1000222, 1000224, 1000225, 1000226, 1000227)

Telencephalon

C15, C16, C17, C18, C20:

- 1 Lobus frontalis
- 2 Lobus parietalis
- 3 Lobus occipitalis
- 4 Lobus temporalis
- 5 Sulcus centralis
- 6 Gyrus precentralis
- 7 Gyrus postcentralis
- 8 Bulbus olfactorius
- 9 Commissura anterior
- 10 Corpus callosum
 - a Genu
 - b Truncus
 - c Splenium
 - d Rostrum
- 11 Septum pellucidum
- 12 Fornix
- 13 Commissura posterior

C16, C17, C18, C20:

- 14 Insula
- 15 Capsula interna
- 16 Ventriculus lateralis
 - e Cornu frontale
 - f Pars centralis
- 17 Plexus choroideus
 - g Cornu occipitale

C17, C18, C20:

- h Cornu temporale
- 18 Hippocampus

Diencephalon

C15, C16, C17, C18, C20:

- 19 Thalamus
- 20 Sulcus hypothalamicus
- 21 Hypothalamus
- 22 Adhesio interthalamica
- 23 Glandula pinealis
- 24 Corpus mammillare sinistrum
- 25 Hypophysis
- 26 Ventriculus tertius cum plexus choroideus

C17, C18, C20:

- 27 Nucleus caudatus
- 28 Pulvinar thalami
- 29 Corpus geniculatum mediale
- 30 Corpus geniculatum laterale

Mesencephalon

C15, C16, C17, C18, C20:

- 31 Lamina tecti

32 Tegmentum mesencephali

33 Crus cerebri

34 Aqueductus mesencephali

Metencephalon

35 Cerebellum

- a Vermis
- b Tonsilla
- c Flocculus
- d Arbor vitae
- e Ventriculus quartus
- 36 Pons
 - f Pedunculus cerebellaris superior
 - g Pedunculus cerebellaris medius
 - h Pedunculus cerebellaris inferior

Myelencephalon

37 Medulla oblongata

38 Oliva

39 Pyramis

40 N. cervicalis I. (C1)

Nervi craniales [®]

- I N. olfactorius
- II N. opticus
- III N. oculomotorius
- IV N. trochlearis
- V N. trigeminus
- VI N. abducens
- VII N. facialis
- VIII N. vestibulocochlearis
- IX N. glossopharyngeus
- X N. vagus
- XI N. accessorius
- XII N. hypoglossus

Circulus arteriosus cerebri (Willisii)

C20:

- 1 A. cerebri anterior
- 2 A. communicans anterior
- 3 A. carotis interna
- 4 A. cerebri media
- 5 A. communicans posterior
- 6 A. cerebri posterior
- 7 A. superior cerebelli
- 8 A. basilaris
- 9 Aa. pontis
- 10 A. labyrinthi
- 11 A. inferior anterior cerebelli
- 12 A. vertebralis
- 13 A. inferior posterior cerebelli
- 14 A. spinalis anterior

The Human Brain

English

Telencephalon

C15, C16, C17, C18, C20:

- 1 Frontal lobe
- 2 Parietal lobe
- 3 Occipital lobe
- 4 Temporal lobe
- 5 Central sulcus
- 6 Precentral gyrus
- 7 Postcentral gyrus
- 8 Olfactory bulb
- 9 Anterior commissure
- 10 Corpus callosum
 - a Genu
 - b Trunk
 - c Splenium
 - d Rostrum
- 11 Septum pellucidum
- 12 Fornix
- 13 Posterior commissure

C16, C17, C18, C20:

- 14 Insula
- 15 Internal capsule
- 16 Lateral ventricle
 - e Frontal horn
 - f Central part
- 17 Choroid plexus
 - g Occipital horn

C17, C18, C20:

- h Temporal horn
- 18 Hippocampus

Diencephalon

C15, C16, C17, C18, C20:

- 19 Thalamus
- 20 Hypothalamic sulcus
- 21 Hypothalamus
- 22 Interthalamic adhesion
- 23 Pineal gland
- 24 Left mammillary body
- 25 Pituitary gland
- 26 Choroid plexus of 3rd ventricle

C17, C18, C20:

- 27 Caudate nucleus
- 28 Pulvinar
- 29 Medial geniculate body
- 30 Lateral geniculate body

Mesencephalon

C15, C16, C17, C18, C20:

- 31 Tectal plate

32 Tegmentum of midbrain

33 Cerebral crus

34 Aqueduct of midbrain

Metencephalon

35 Cerebellum

- a Vermis
 - b Tonsil
 - c Flocculus
 - d Arbor vitae
 - e Fourth ventricle
- 36 Pons
- f Superior cerebellar peduncle
 - g Middle cerebellar peduncle
 - h Inferior cerebellar peduncle

Myelencephalon

37 Medulla oblongata

38 Inferior olive

39 Pyramid

40 First cervical nerve (C1)

Cranial Nerves [®]

- I Olfactory nerve
- II Optic nerve
- III Oculomotor nerve
- IV Trochlear nerve
- V Trigeminal nerve
- VI Abducent nerve
- VII Facial nerve
- VIII Vestibulocochlear nerve
- IX Glossopharyngeal nerve
- X Vagus nerve
- XI Accessory nerve
- XII Hypoglossal nerve

Cerebral arterial circle (Circle of Willis)

C20:

- 1 Anterior cerebral artery
- 2 Anterior communicating artery
- 3 Internal carotid artery
- 4 Middle cerebral artery
- 5 Posterior communicating artery
- 6 Posterior cerebral artery
- 7 Superior cerebellar artery
- 8 Basilar artery
- 9 Pontine arteries
- 10 Labyrinthine artery
- 11 Anterior inferior cerebellar artery
- 12 Vertebral artery
- 13 Posterior inferior cerebellar artery
- 14 Anterior spinal artery