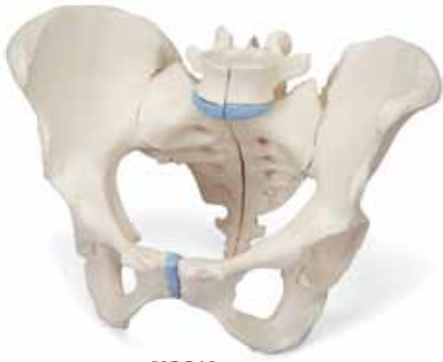
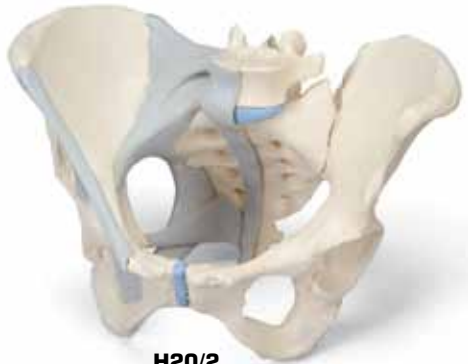


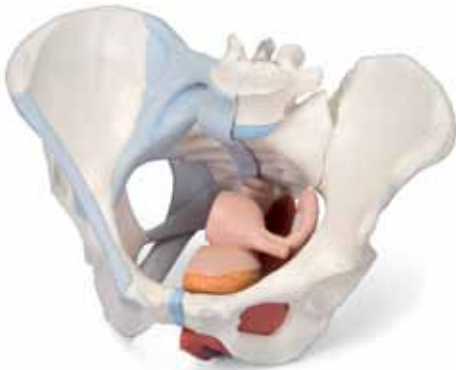*...going one step further*



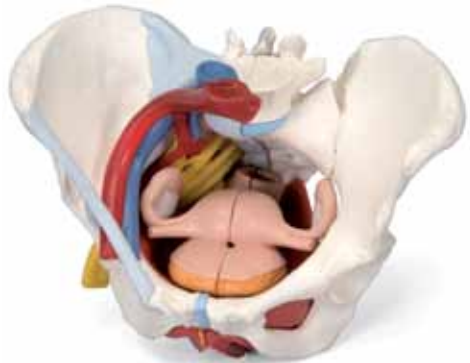**H20/1**  
(1000285)



**H20/2**  
(1000286)



**H20/3**  
(1000287)



**H20/4**  
(1000288)

**H20/1, H20/2, H20/3, H20/4**

(1000285\_1000286\_1000287\_1000288)

## Latin

### H20/1, H20/2, H20/3, H20/4

- 1 Promontorium
- 2 Processus articularis superior
- 3 Vertebra lumbalis V
- 4 Processus costalis
- 5 Discus intervertebralis
- 6 Crista iliaca
- 7 Ala ossis ilii
- 8 Spina iliaca anterior superior
- 9 Spina iliaca anterior inferior
- 10 Acetabulum
- 11 Foramen obturatum
- 12 Ramus ossis ischii
- 13 Ramus superior ossis pubis
- 14 Ramus inferior ossis pubis
- 15 Tuberculum pubicum
- 16 Crista pubica
- 17 Symphysis pubica
- 18 Corpus ossis pubis
- 19 Tuber ischiadicum
- 20 Spina ischiadica
- 21 Eminentia iliopubica
- 22 Os coccygis
- 23 Foramina sacralia anteriora
- 24 Os sacrum
- 25 Articulatio sacroiliaca
- 26 Processus spinosus
- 27 Processus articularis inferior
- 28 Spina iliaca posterior superior
- 29 Spina iliaca posterior inferior
- 30 Cornu sacrale
- 31 Hiatus sacralis
- 32 Foramina sacralia posteriora
- 33 Crista sacralis mediana
- 34 Cauda equina
- 35 Incisura ischiadica major
- 36 Incisura ischiadica minor
- 37 Os ischii

### H20/2, H20/3, H20/4

- 38 Lig. longitudinale anterius
- 39 Membrana obturatoria
- 40 Lig. sacrospinale
- 41 Lig. sacrotuberale
- 42 Lig. inguinale
- 43 Ligg. sacroiliaca anteriora
- 44 Lig. iliolumbale
- 45 Ligg. sacroiliaca interossea
- 46 Lig. sacroiliacum posterius
- 47 Lig. supraspinale

### H20/3, H20/4

- 48 Rectum
- 49 Ovarium
- 50 Tuba uterina
- 51 Uterus
- 52 Lig. ovarii proprium
- 53 Vesica urinaria
- 54 Membrana perinei
- 55 M. obturatorius internus
- 56 M. transversus perinei profundus
- 57 M. bulbospongiosus
- 58 M. sphincter ani externus
- 59 M. sphincter ani internus
- 60 Lig. anococcygeum
- 61 M. puborectalis
- 62 M. pubococcygeus
- 63 M. iliococcygeus
- 64 M. levator ani
- 65 M. coccygeus
- 66 Clitoris
- 67 Urethra
- 68 Vagina
- 69 Cavitas uteri
- 70 Ostium uteri
- 71 Anus
- 72 Excavatio rectouterina
- 73 Plica transversa recti
- 74 M. transversus perinei superficialis
- 75 Glandula vestibularis major (BARTHOLINI)
- 76 Bulbus vestibuli
- 77 M. ischiocavernosus

### H20/4

- 78 A. iliaca externa
- 79 V. iliaca externa
- 80 A. iliaca interna
- 81 V. iliaca interna
- 82 A. iliaca communis dextra
- 83 V. cava inferior
- 84 Pars abdominalis aortae
- 85 A. iliaca communis sinistra
- 86 N. ischiadicus
- 87 A. femoralis
- 88 Plexus sacralis
- 89 N. dorsalis clitoridis
- 90 N. pudendus
- 91 M. piriformis
- 92 Nn. rectales inferiores
- 93 Nn. perineales
- 94 Nn. labiales posteriores
- 95 V. femoralis
- 96 V. iliaca communis sinistra
- 97 A. glutealis superior
- 98 A. glutealis inferior
- 99 A. pudenda interna
- 100 A. rectalis media
- 101 A. vesicalis inferior
- 102 A. uterina
- 103 A. umbilicalis
- 104 A. obturatoria

**H20/1, H20/2, H20/3, H20/4**

- 1 Promontory
- 2 Superior articular surface
- 3 Lumbar vertebra V
- 4 Costal process
- 5 Intervertebral disc
- 6 Crest of ilium
- 7 Wing of ilium
- 8 Anterior superior iliac spine
- 9 Anterior inferior iliac spine
- 10 Acetabulum
- 11 Obturator foramen
- 12 Frame of ischial bone
- 13 Superior pubic ramus
- 14 Inferior pubic ramus
- 15 Pubic tubercle
- 16 Pubic crest
- 17 Pubic symphysis
- 18 Body of pubis
- 19 Sciatic tuber
- 20 Ischial spine
- 21 Iliopubic eminence
- 22 Coccygeal bone
- 23 Anterior sacral foramina
- 24 Sacral bone
- 25 Sacroiliac joint
- 26 Spinous process
- 27 Inferior articular process
- 28 Posterior superior iliac spine
- 29 Posterior inferior iliac spine
- 30 Sacral horn
- 31 Sacral hiatus
- 32 Posterior sacral foramina
- 33 Median sacral crest
- 34 Cauda equina
- 35 Greater sciatic notch
- 36 Lesser sciatic notch
- 37 Ischial bone

**H20/2, H20/3, H20/4**

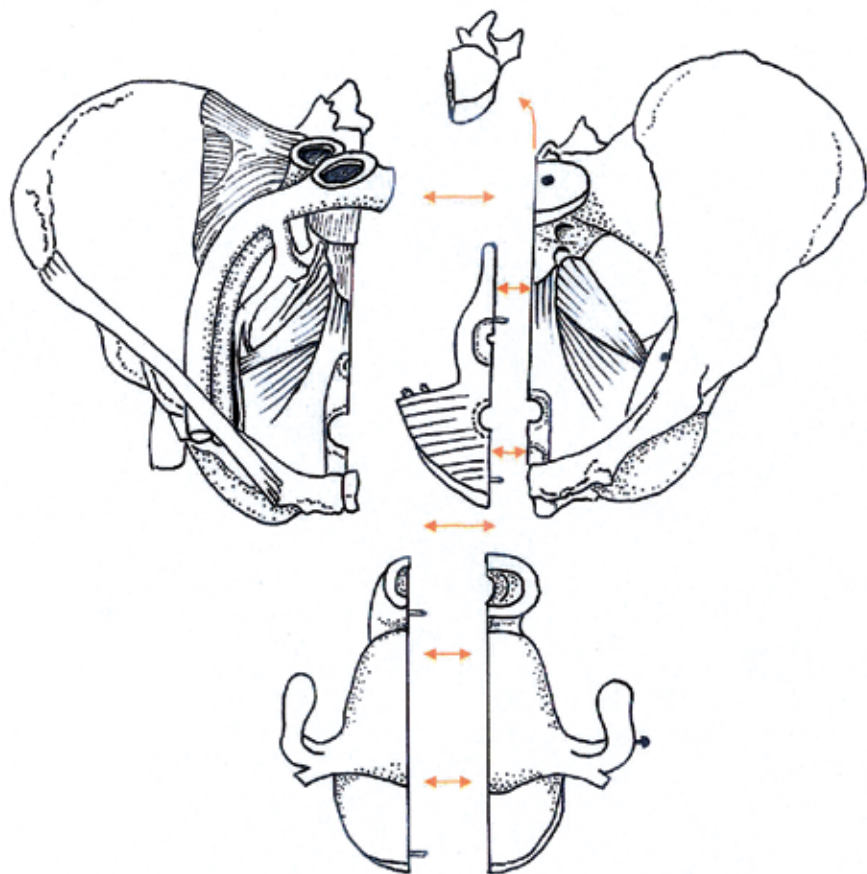
- 38 Anterior longitudinal ligament
- 39 Obturator membrane
- 40 Sacrospinous ligament
- 41 Sacrotuberal ligament
- 42 Inguinal ligament
- 43 Anterior sacroiliac ligaments
- 44 Iliolumbar ligament
- 45 Interosseous sacro-iliac ligaments
- 46 Posterior sacro-iliac ligament
- 47 Supraspinous ligament

**H20/3, H20/4**

- 48 Rectum
- 49 Ovary
- 50 Uterine tube
- 51 Uterus
- 52 Ligament of ovary
- 53 Urinary bladder
- 54 Perineal membrane
- 55 Obturator internus
- 56 Deep transverse perineal muscle
- 57 Bulbospongiosus muscle
- 58 Sphincter ani externus muscle
- 59 Sphincter ani internus muscle
- 60 Anococcygeal ligament
- 61 Puborectalis muscle
- 62 Pubococcygeus
- 63 Iliococcygeus muscle
- 64 Levator ani
- 65 Coccygeal muscle
- 66 Clitoris
- 67 Urethra
- 68 Vagina
- 69 Uterine cavity
- 70 Opening of uterus
- 71 Anus [anal orifice]
- 72 Recto-uterine pouch
- 73 Transverse rectal fold
- 74 Superficial transverse perineal muscle
- 75 Greater vestibular gland (BARTHOLINI)
- 76 Bulb of vestibule
- 77 Ischiacavernosus

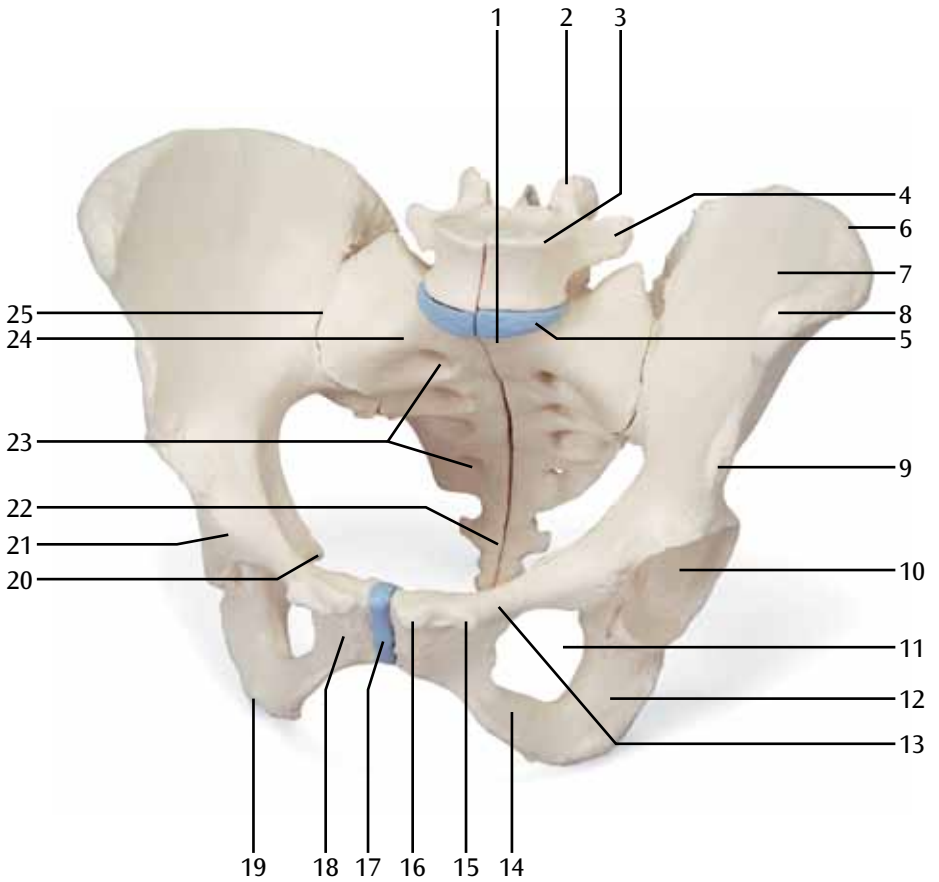
**H20/4**

- 78 External iliac artery
- 79 External iliac vein
- 80 Internal iliac artery
- 81 Internal iliac vein
- 82 Right common iliac artery
- 83 Inferior vena cava
- 84 Abdominal aorta
- 85 Left common iliac artery
- 86 Sciatic nerve
- 87 Femoral artery
- 88 Sacral plexus
- 89 Dorsal nerve of clitoris
- 90 Pudendal nerve
- 91 Piriformis
- 92 Inferior rectal nerves
- 93 Perineal nerves
- 94 Posterior labial nerves
- 95 Femoral vein
- 96 Left common iliac vein
- 97 Superior gluteal artery
- 98 Inferior gluteal artery
- 99 Internal pudendal artery
- 100 Middle rectal artery
- 101 Inferior vesical artery
- 102 Uterine artery [Fallopian artery]
- 103 Umbilical artery
- 104 Obturator artery



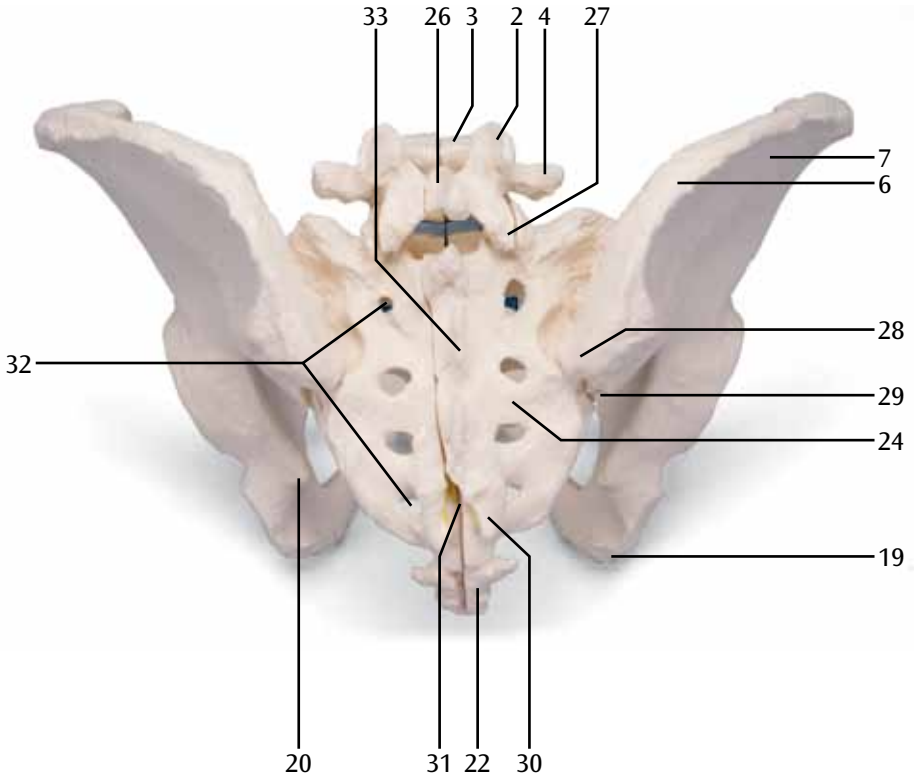
# H20/1

(1000285)



# H20/1

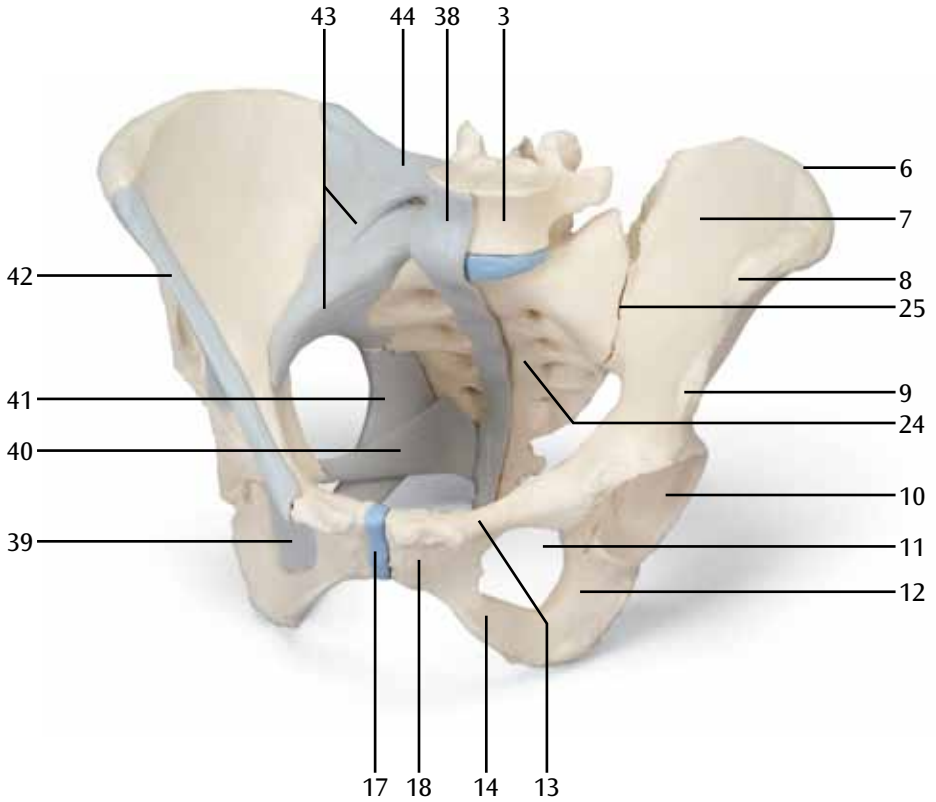
(1000285)





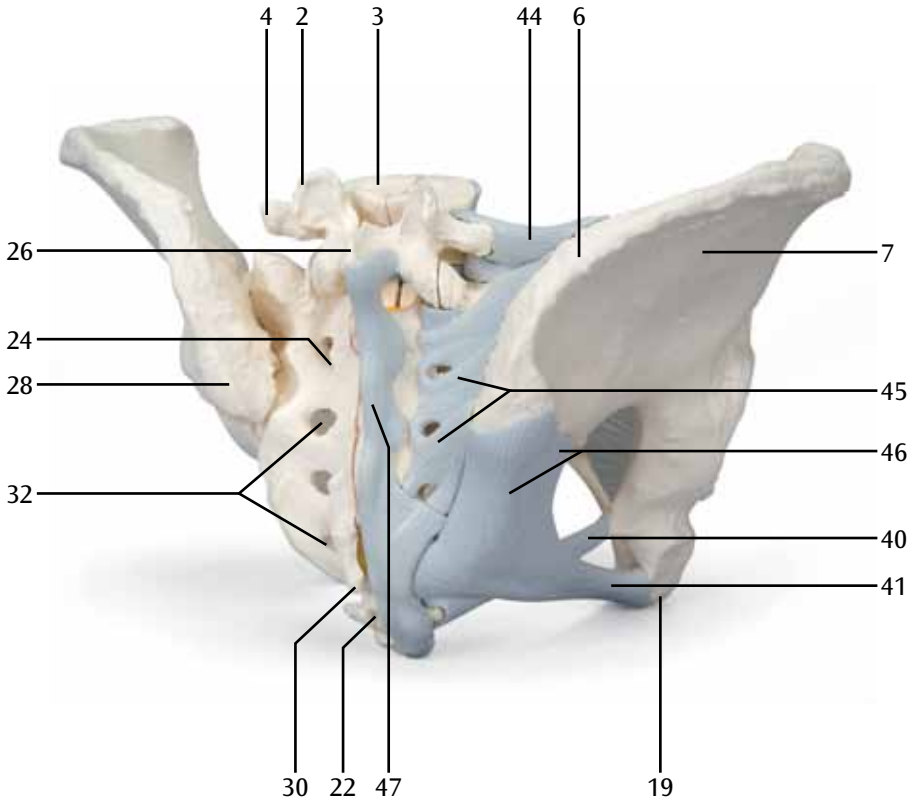
# H20/2

(1000286)



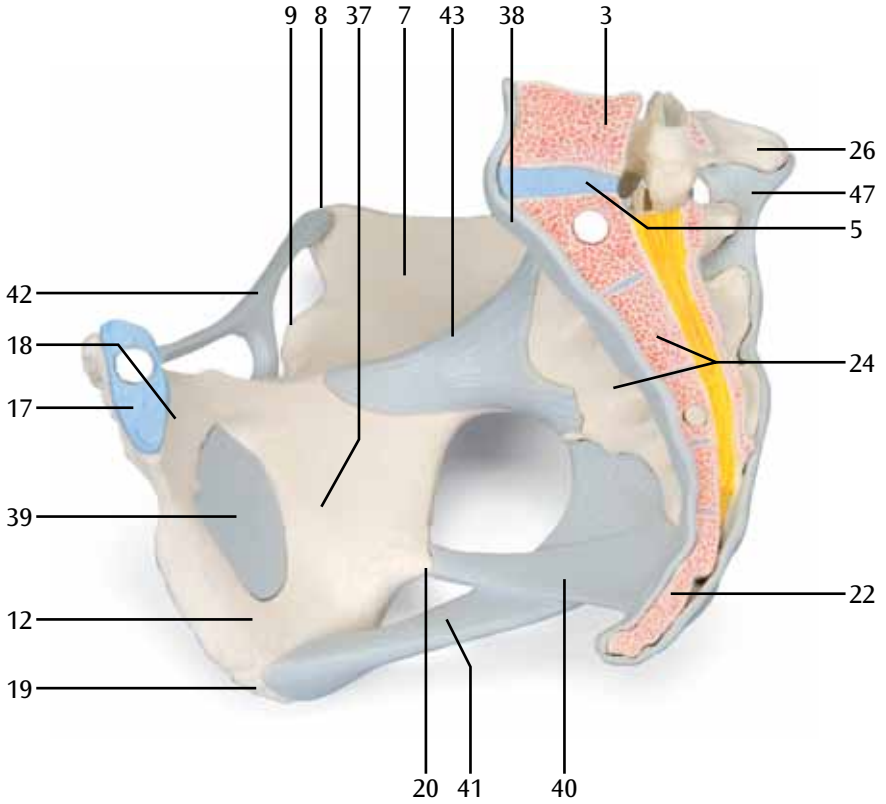


**H20/2**  
**(1000286)**

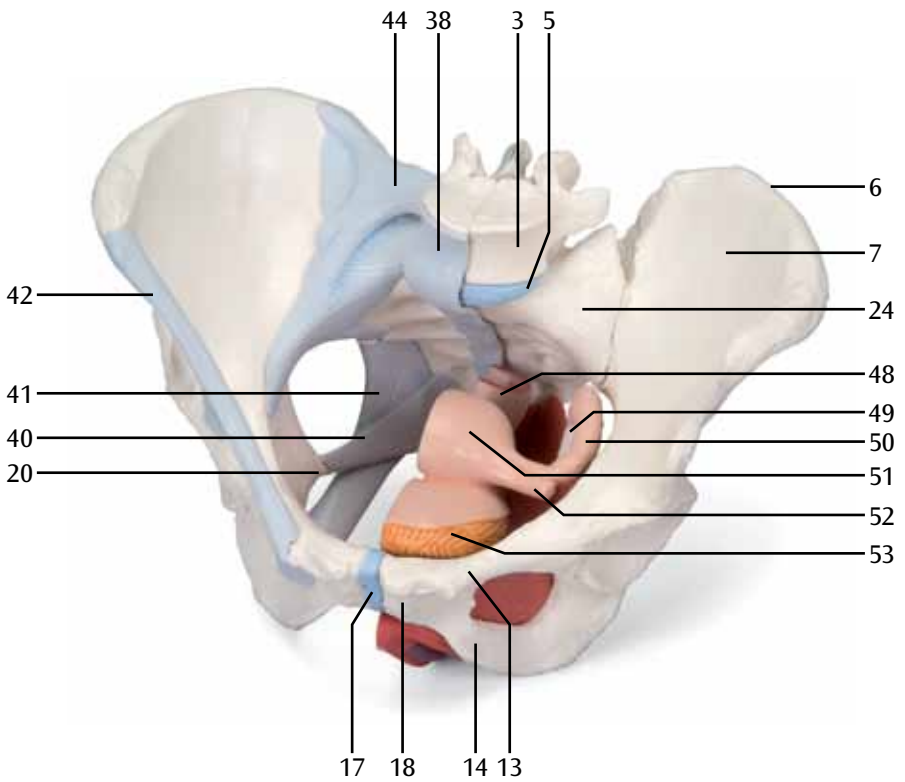


# H20/2

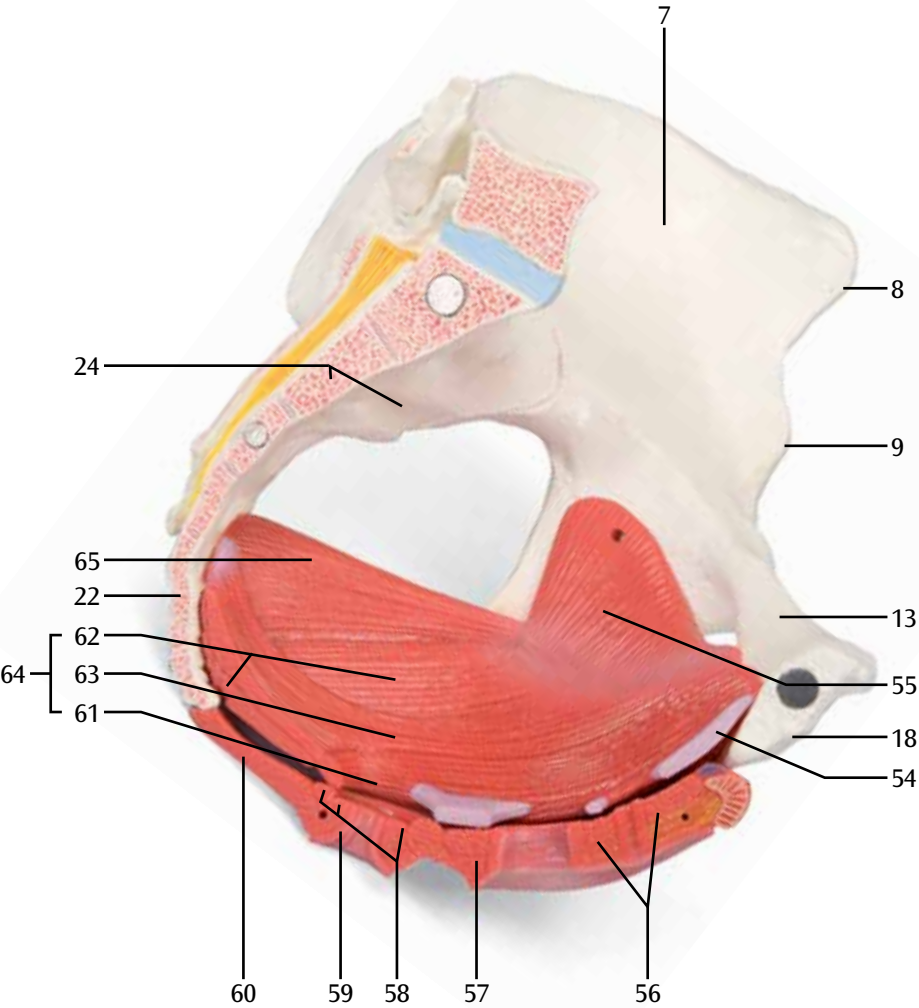
(1000286)



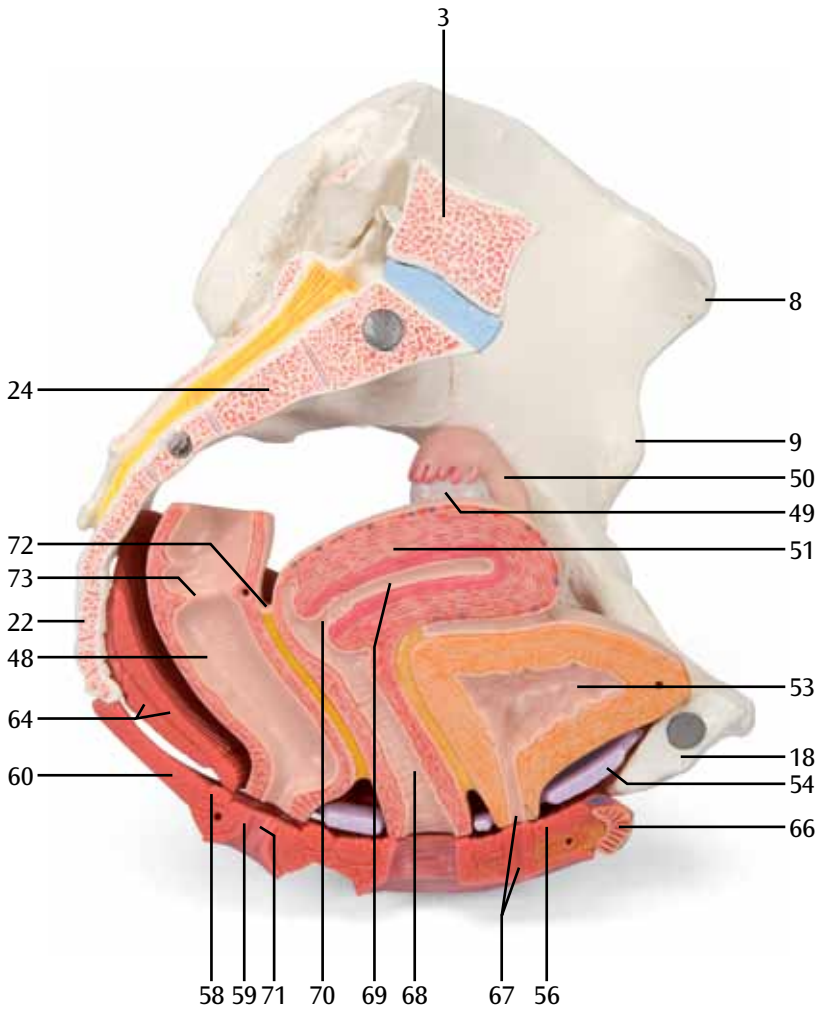
**H20/3**  
**(1000287)**



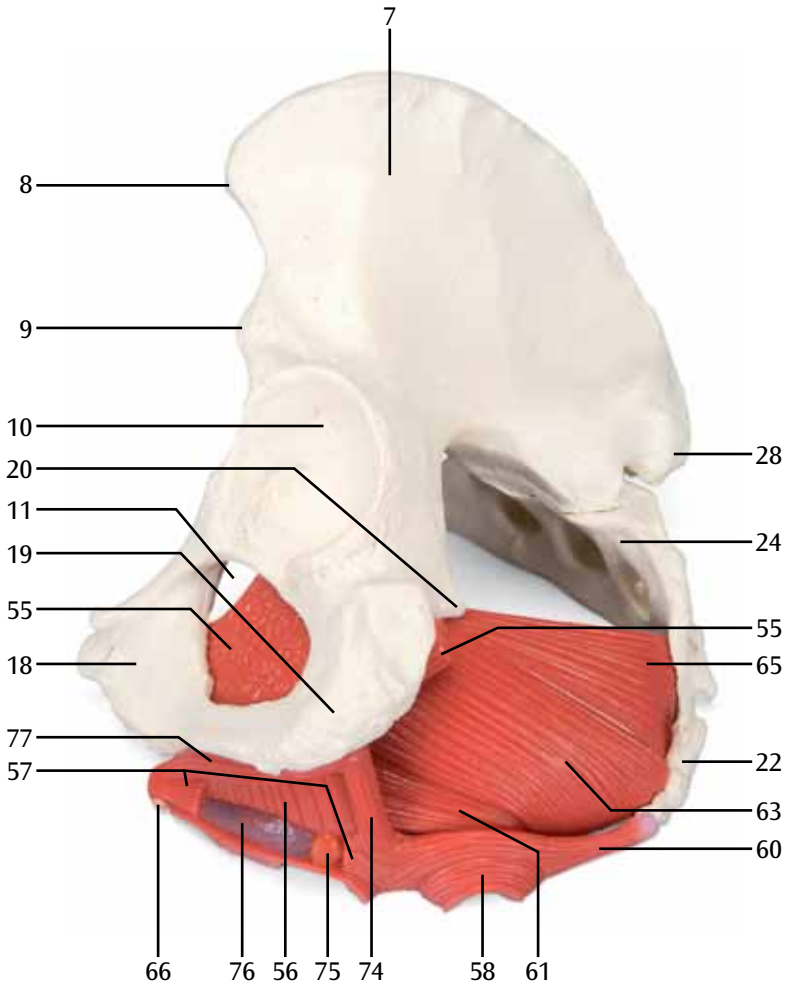
**H20/3, H20/4**  
(1000287, 1000288)



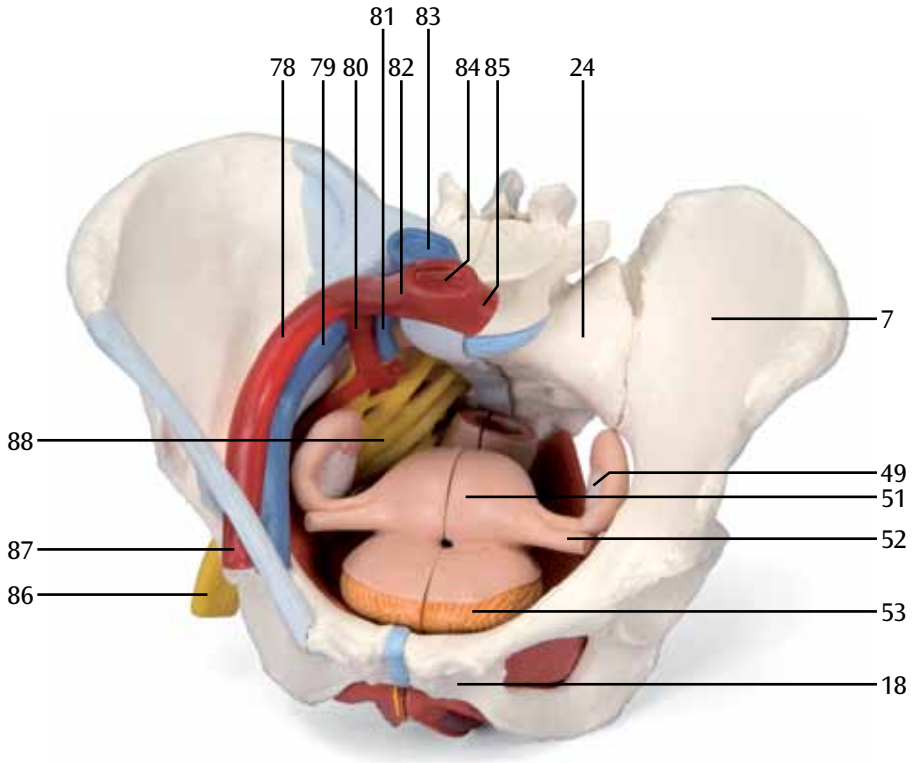
# H20/3, H20/4 (1000287, 1000288)



**H20/3, H20/4**  
**(1000287, 1000288)**

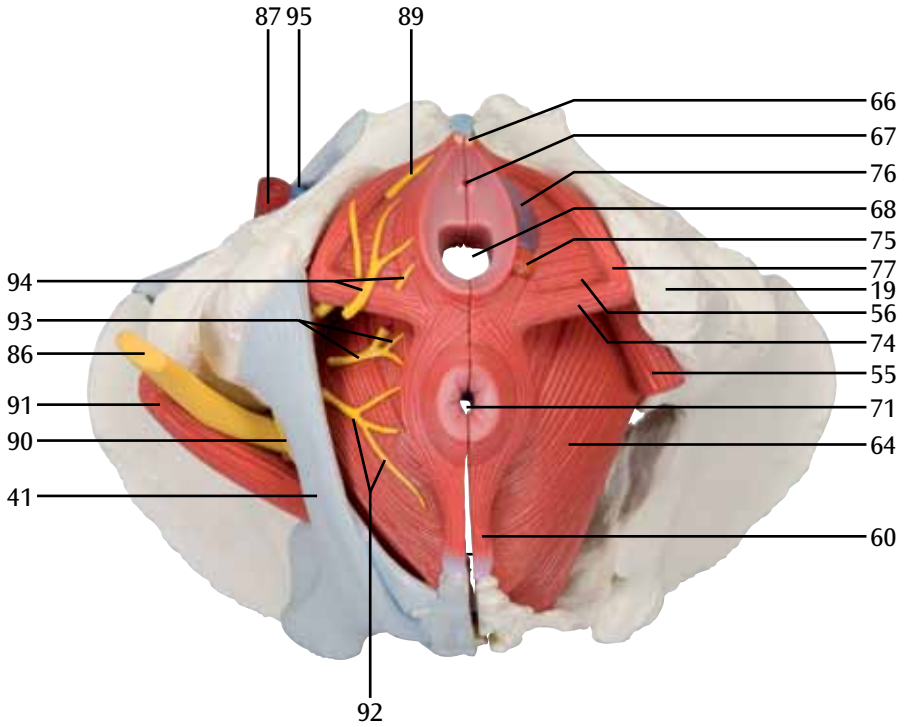


# H20/4 (1000288)



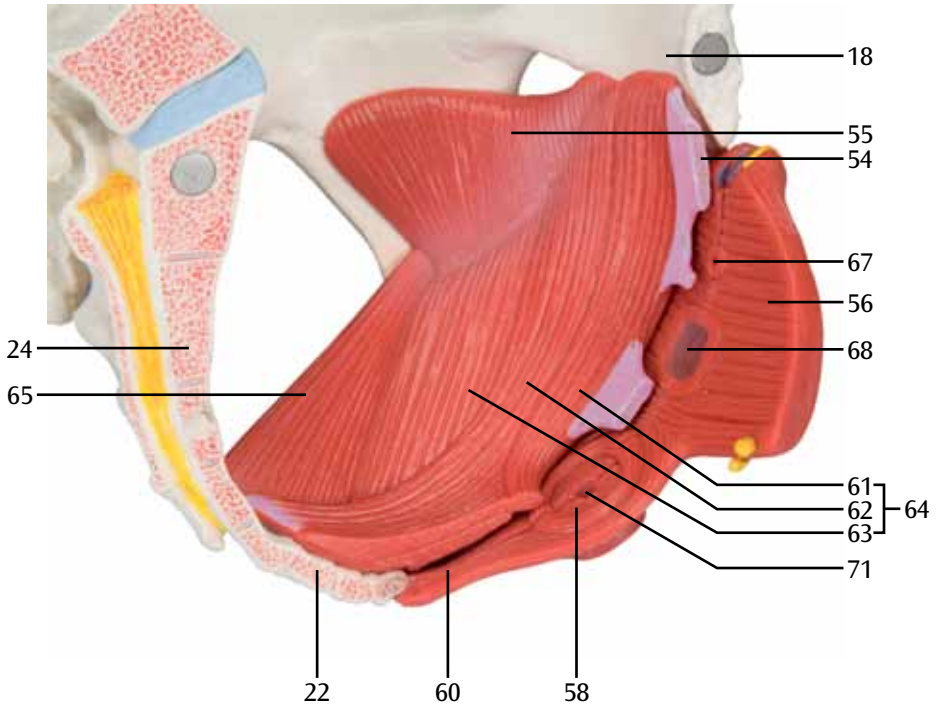
# H20/4

(1000288)

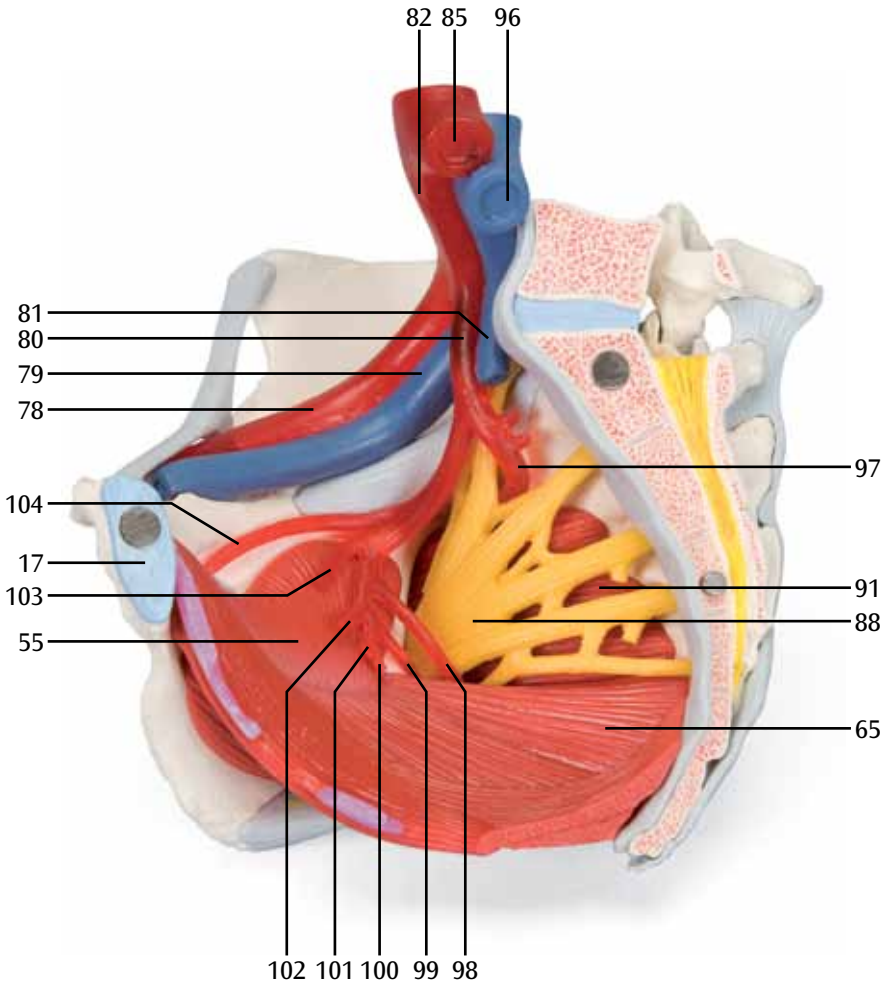




# H20/3, H20/4 (1000287, 1000288)



**H20/4**  
**(1000288)**



# H20/4 (1000288)

