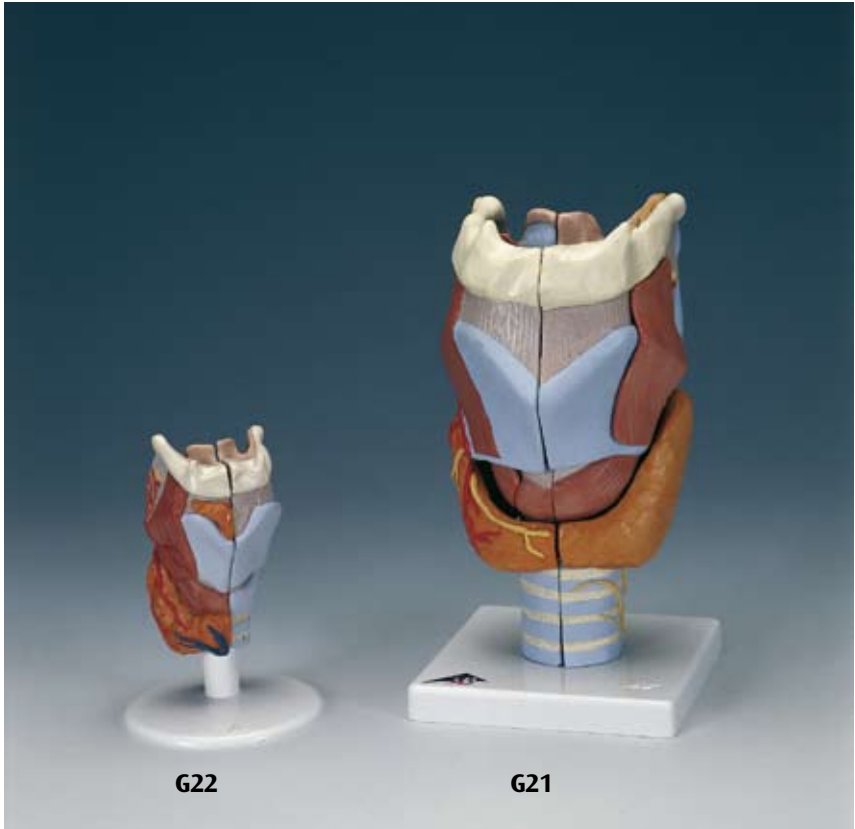



...going one step further



G21
G22

Latin

G21

- 1 N. laryngealis superior
- 2 A. laryngea superior
- 3 A. thyroidea superior
- 4 N. laryngeus recurrens
- 5 Os hyoideum, cornu minus
- 6 Os hyoideum, cornu majus
- 7 Lig. thyrohyoideum laterale
- 8 Cartilago triticea
- 9 Cartilago thyroidea, cornu superius
- 10 Membrana thyrohyoidea
- 11 Cartilago thyroidea, cornu inferius
- 12 Articulatio cricothyroidea, capsula
- 13 M. cricothyroideus, pars obliqua
- 14 Lig. cricotracheale
- 15 Cartilagine tracheales
- 16 Os hyoideum
- 17 Os hyoideum, corpus
- 18 Incisura thyroidea superior
- 19 M. thyrohyoideus
- 20 Cartilago thyroidea
- 21 Lig. cricothyroideum medianum
- 22 M. cricothyroideus, pars recta
- 23 Glandula thyroidea, isthmus
- 24 M. cricothyroideus
- 25 A. thyroidea superior, ramus glandularis anterior
- 26 Lig. thyrohyoideum medianum
- 27 Cartilago cuneiformis
- 28 M. arytenoideus obliquus
- 29 M. cricoarytenoideus posterior
- 30 M. arytenoideus transversus
- 31 Cartilago arytenoidea
- 32 Cartilago corniculata
- 33 Recessus piriformis
- 34 Plica aryepiglottica
- 35 Lig. hyoepiglotticum
- 36 Cartilago epiglottica
- 37 N. laryngealis superior, ramus internus
- 38 M. thyroepiglotticus
- 39 Corpus adiposum pre-epiglotticum
- 40 M. thyroarytenoideus
- 41 M. thyroarytenoideus obliquus
- 42 M. cricoarytenoideus lateralis
- 43 N. laryngealis inferior
- 44 Facies articularis thyroidea
- 45 M. aryepiglotticus
- 46 M. stylopharyngeus
- 47 Plica vestibularis
- 48 Ventriculus laryngis
- 49 Plica vocalis
- 50 M. vocalis
- 51 Trachea

- 52 Cartilago cricoidea
- 53 Lig. thyroepiglotticum

G22

- 1 Glandula thyroidea, lobus pyramidalis
- 2 Glandula thyroidea
- 3 V. thyroidea inferior
- 4 A. thyroidea superior, ramus glandularis anterior
- 5 M. cricothyroideus
- 6 M. thyrohyoideus
- 7 A. laryngea superior
- 8 N. laryngealis superior
- 9 M. arytenoideus transversus
- 10 M. cricoarytenoideus posterior
- 11 M. arytenoideus obliquus
- 12 Cartilago arytenoidea
- 13 Lig. hyoepiglotticum
- 14 Cartilago epiglottica
- 15 Corpus adiposum pre-epiglotticum
- 16 Ventriculus laryngis
- 17 Os hyoideum, cornu minus
- 18 Os hyoideum, cornu majus
- 19 Lig. thyrohyoideum laterale
- 20 Cartilago triticea
- 21 Cartilago thyroidea, cornu superius
- 22 Cartilago thyroidea, cornu inferius
- 23 Cartilagine tracheales
- 24 Lig. cricotracheale
- 25 Cartilago cricoidea
- 26 Lig. cricothyroideum medianum
- 27 Cartilago thyroidea
- 28 Incisura thyroidea superior
- 29 Membrana thyrohyoidea
- 30 Os hyoideum

Larynx Models

English

G21

Larynx, 2 times full-size, 7-part

- 1 Superior laryngeal nerve
- 2 Superior laryngeal artery
- 3 Superior thyroid artery
- 4 Recurrent laryngeal nerve
- 5 Lesser horn of hyoid bone
- 6 Greater horn of hyoid bone
- 7 Lateral thyrohyoid ligament
- 8 Triticeal cartilage
- 9 Superior horn of thyroid
- 10 Thyroid membrane
- 11 Inferior horn of thyroid
- 12 Cricothyroid articular capsule
- 13 Oblique part of cricothyroid muscle
- 14 Cricotracheal ligament
- 15 Tracheal cartilages
- 16 Hyoid bone
- 17 Body of hyoid bone
- 18 Superior thyroid notch
- 19 Thyrohyoideus muscle
- 20 Thyroid cartilage
- 21 Mediate Cricothyroid ligament
- 22 Vertical part of cricothyroid muscle
- 23 Isthmus of thyroid gland
- 24 Cricothyroid muscle
- 25 Anterior glandular branch of superior thyroid artery
- 26 Medial thyrohyoid ligament
- 27 Cuneiform cartilage
- 28 Oblique arytenoid muscle
- 29 Cricoarytenoideus posterior muscle
- 30 Transverse arytenoid muscle
- 31 Arytenoid (arytenoid cartilage]
- 32 Corniculate cartilage, (SANTORINI)
- 33 Piriform recess
- 34 Aryepiglottic fold
- 35 Hyoepiglottic ligament
- 36 Epiglottic cartilage
- 37 Internal branch of superior laryngeal nerve
- 38 Thyroepiglotticus muscle
- 39 Preepiglottic fat pad
- 40 Thyroarytenoideus muscle
- 41 Thyroarytaenoid muscle, pars vocalis
- 42 Cricoarytenoideus lateralis muscle
- 43 Inferior laryngeal nerve
- 44 Articular surface of thyroid
- 45 Aryepiglotticus muscle
- 46 Stylopharyngeus muscle
- 47 Vestibular fold
- 48 Laryngeal ventricle
- 49 Vocal fold
- 50 Vocalis muscle

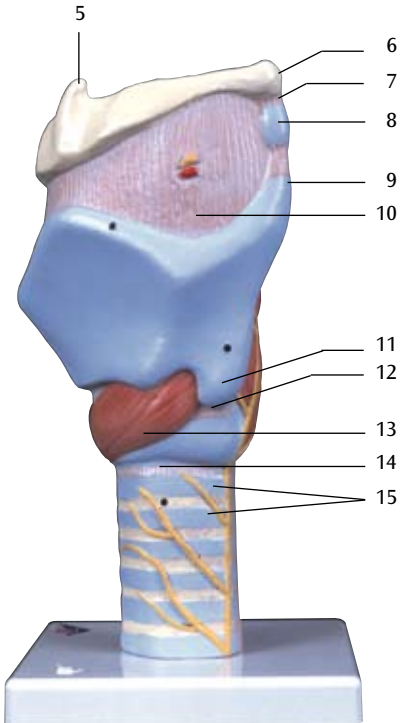
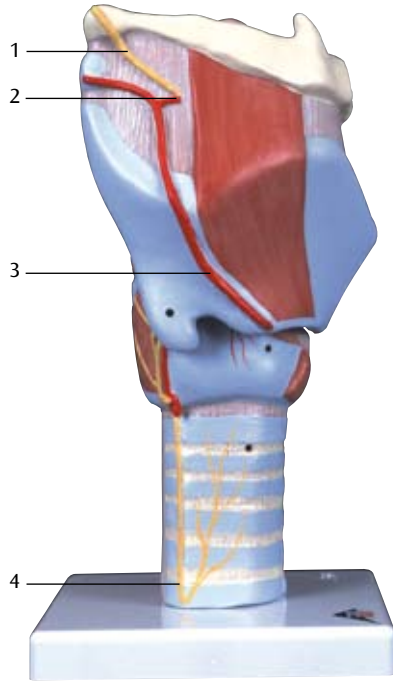
- 51 Trachea (windpipe]
- 52 Cricoid cartilage (annular cartilage]
- 53 Ligamentum thyroepiglotticum

G22

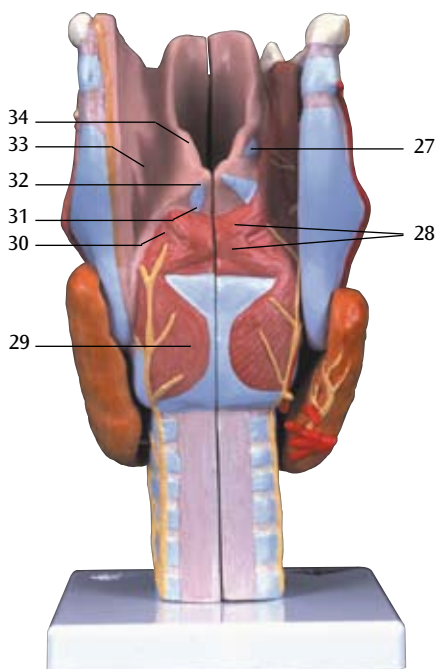
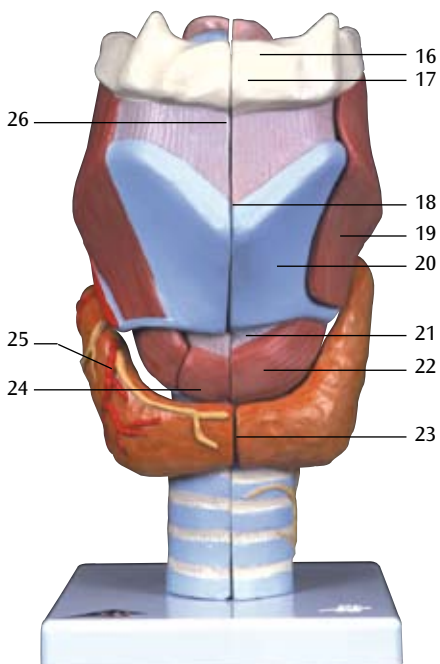
Larynx, full-size, 2-part

- 1 Pyramid of thyroid
- 2 Thyroid gland
- 3 Inferior thyroid vein
- 4 Anterior glandular branch of superior thyroid artery
- 5 Cricothyroid muscle
- 6 Thyrohyoideus muscle
- 7 Superior laryngeal artery
- 8 Superior laryngeal nerve
- 9 Transverse arytenoid muscle
- 10 Cricoarytenoideus posterior muscle
- 11 Oblique arytenoid muscle
- 12 Arytenoid (arytenoid cartilage)
- 13 Hyoepiglottic ligament
- 14 Epiglottic cartilage
- 15 Preepiglottic fat pad
- 16 Laryngeal ventricle
- 17 Lesser horn of hyoid bone
- 18 Greater horn of hyoid bone
- 19 Lateral thyrohyoid ligament
- 20 Triticeal cartilage
- 21 Superior horn of thyroid
- 22 Inferior horn of thyroid
- 23 Tracheal cartilages
- 24 Cricotracheal ligament
- 25 Cricoid cartilage (annular cartilage]
- 26 Mediate Cricothyroid ligament
- 27 Thyroid cartilage
- 28 Superior thyroid notch
- 29 Thyroid membrane
- 30 Hyoid bone

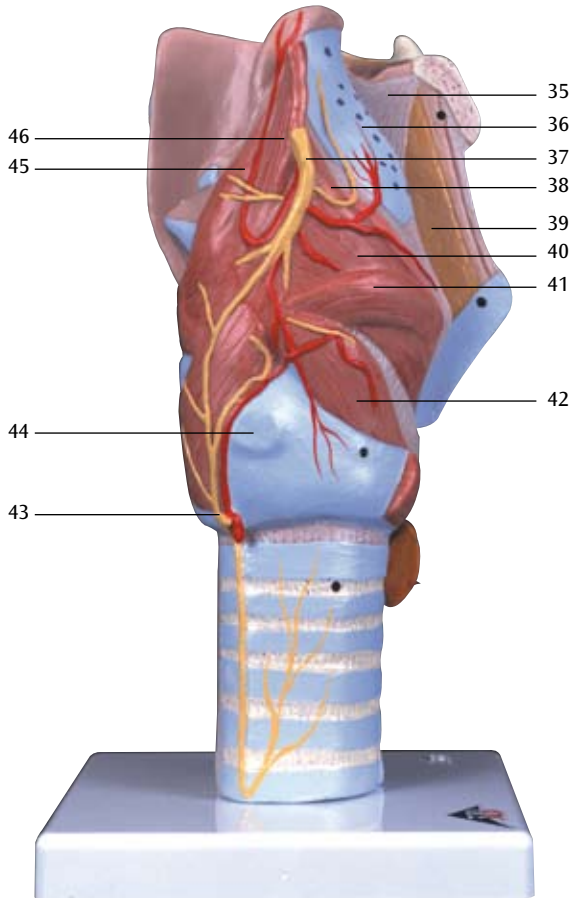
G21

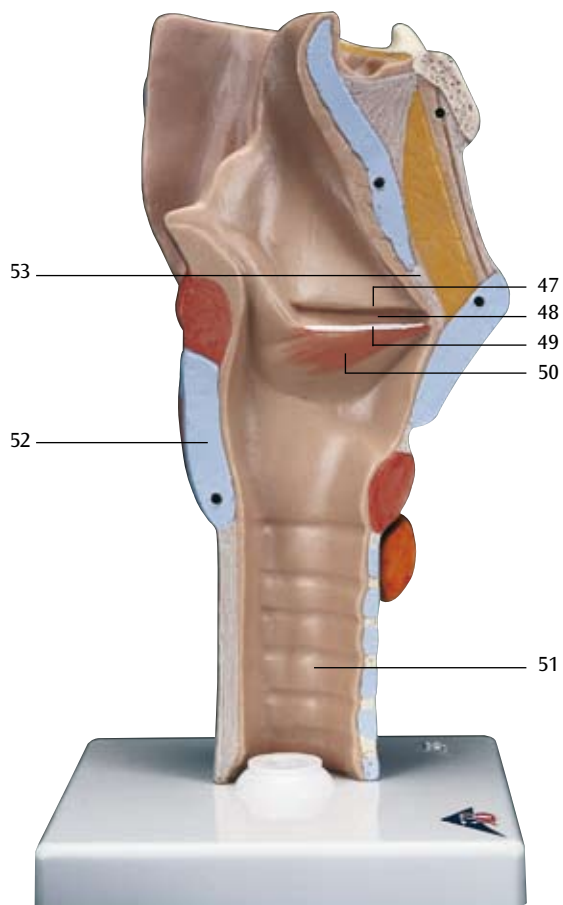


G21



G21





G22

