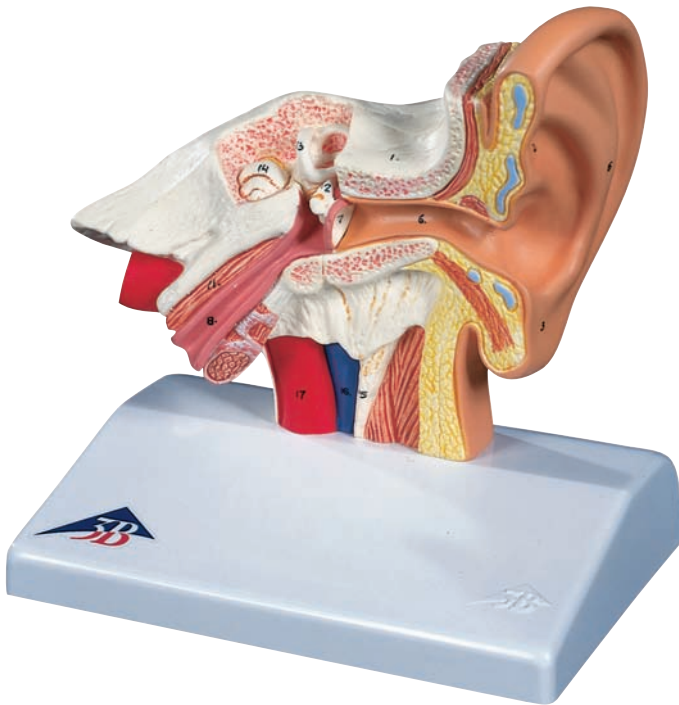




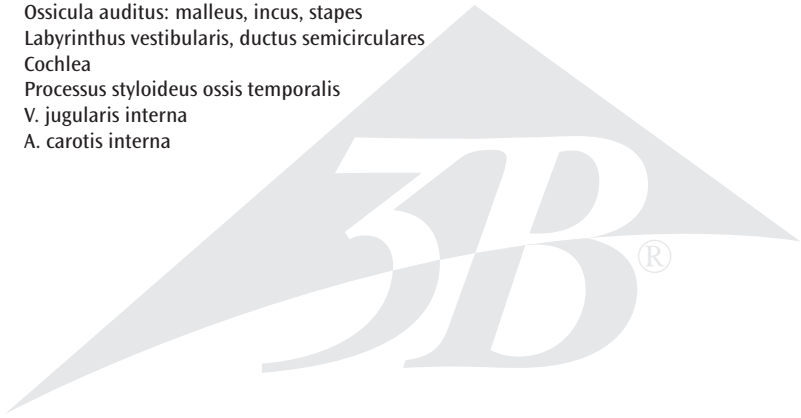
...going one step further



E12

Latin

- 1 Os temporale
- 2 Auricula
- 3 Lobulus auriculae
- 4 Helix
- 5 Antihelix
- 6 Meatus acusticus externus
- 7 Membrana tympanica
- 8 Tuba auditiva
- 9 Meatus acusticus internus
- 10 N. vestibulocochlearis
- 11 M. tensor tympani
- 12 Ossicula auditus: malleus, incus, stapes
- 13 Labyrinthus vestibularis, ductus semicirculares
- 14 Cochlea
- 15 Processus styloideus ossis temporalis
- 16 V. jugularis interna
- 17 A. carotis interna



Ear Model

English

- 1 Temporal bone
- 2 Auricle
- 3 Lobule of auricle
- 4 Helix
- 5 Antihelix
- 6 External acoustic meatus
- 7 Tympanic membrane
- 8 Pharyngotympanic tube
- 9 Internal acoustic meatus
- 10 Vestibulocochlear nerve
- 11 Tensor tympani muscle
- 12 Auditory ossicles: malleus, incus, stapes
- 13 Vestibular labyrinth, semicircular ducts
- 14 Cochlea
- 15 Styloid process of temporal bone
- 16 Internal jugular vein
- 17 Internal carotid artery

