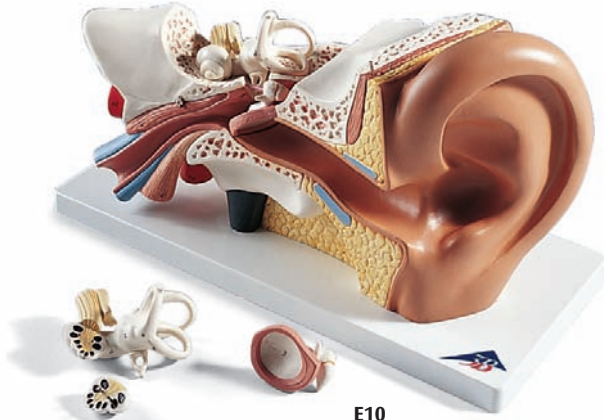
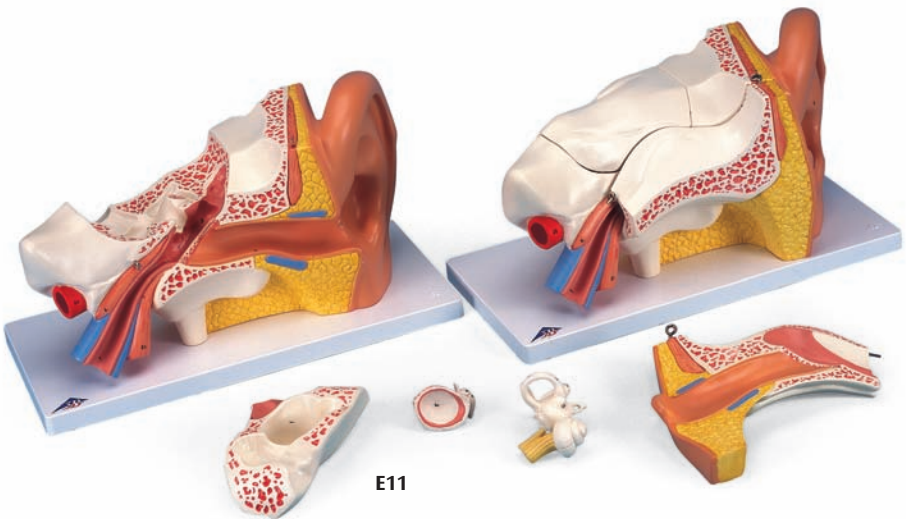




*...going one step further*



**E10**



**E11**

**E10**  
**E11**

# Organum vestibulocochleare

## **A Auris externa**

- 1 Auricula
- 2 Meatus acusticus externus
- 3 Membrana tympanica
- 4 Anulus fibrocartilagineus

## **B Auris media**

- 5 Cavitas tympani
- 6 M. tensor tympani
- 7 Tuba auditiva
- 8 Malleus
- 8a Caput mallei
- 8b Manubrium mallei
- 8c Processus anterior
- 9 Incus
- 9a Crus breve
- 9b Crus longum
- 10 Processus lenticularis
- 11 Stapes
- 11a Caput stapedis
- 11b Crus posterius
- 11c Basis stapedis

## **C Auris interna**

- 12 Vestibulum
- 13 Fenestra vestibuli
- 14 Fenestra cochleae
- 15 Canalis semicircularis lateralis
- 15a Ampulla ossea lateralis
- 16 Canalis semicircularis anterior
- 16b Ampulla ossea anterior
- 17 Canalis semicircularis posterior
- 17c Ampulla ossea posterior
- 18 Cochlea
- 19 N. vestibulocochlearis
- 20 A. carotis interna
- 21 M. tensor veli palatini



# Vestibulocochlear organ

English

## **A External ear**

- 1 Auricle
- 2 External acoustic meatus
- 3 Tympanic membrane
- 4 Fibrocartilaginous ring

## **B Middle ear**

- 5 Tympanic cavity
- 6 Tensor tympani muscle
- 7 Pharyngotympanic tube
- 8 Malleus
- 8a Head of malleus
- 8b Handle of malleus
- 8c Anterior process
- 9 Incus
- 9a Short limb of incus
- 9b Long limb of incus
- 10 Lenticular process
- 11 Stapes
- 11a Head of stapes
- 11b Posterior limb
- 11c Base of stapes

## **C Internal ear**

- 12 Vestibule
- 13 Oval window
- 14 Round window
- 15 Lateral semicircular canal
- 15a Lateral bony ampulla
- 16 Anterior semicircular canal
- 16b Anterior bony ampulla
- 17 Posterior semicircular canal
- 17c Posterior bony ampulla
- 18 Cochlea
- 19 Vestibulocochlear nerve
- 20 Internal carotid artery
- 21 Tensor veli palatini

