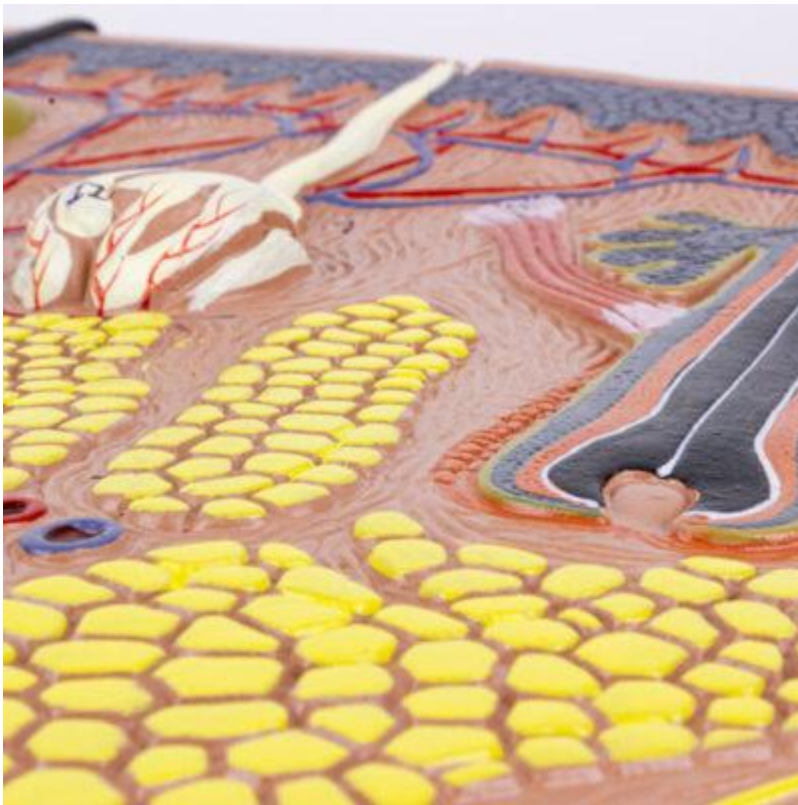
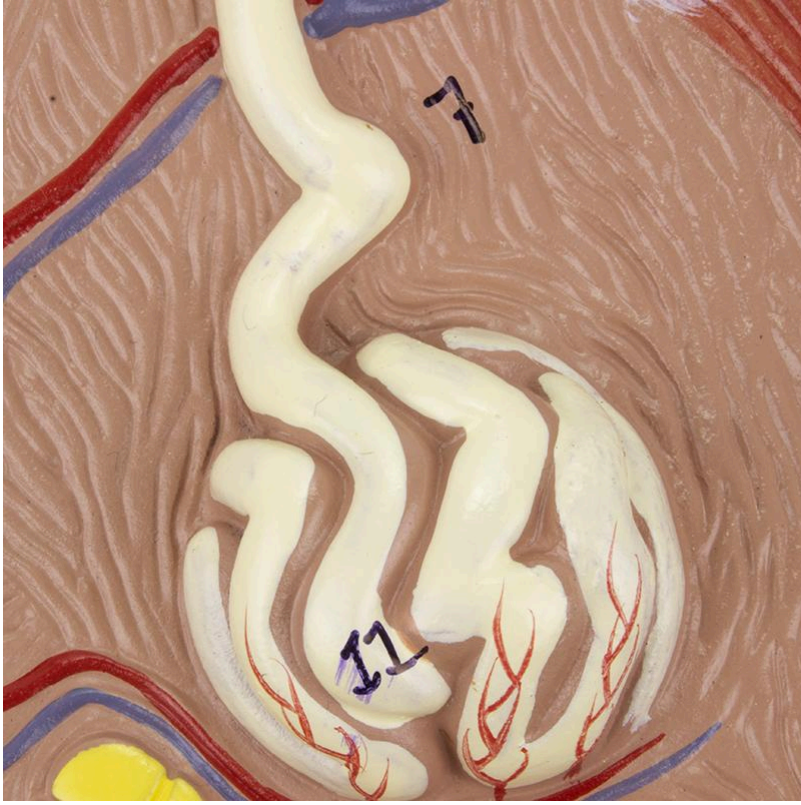


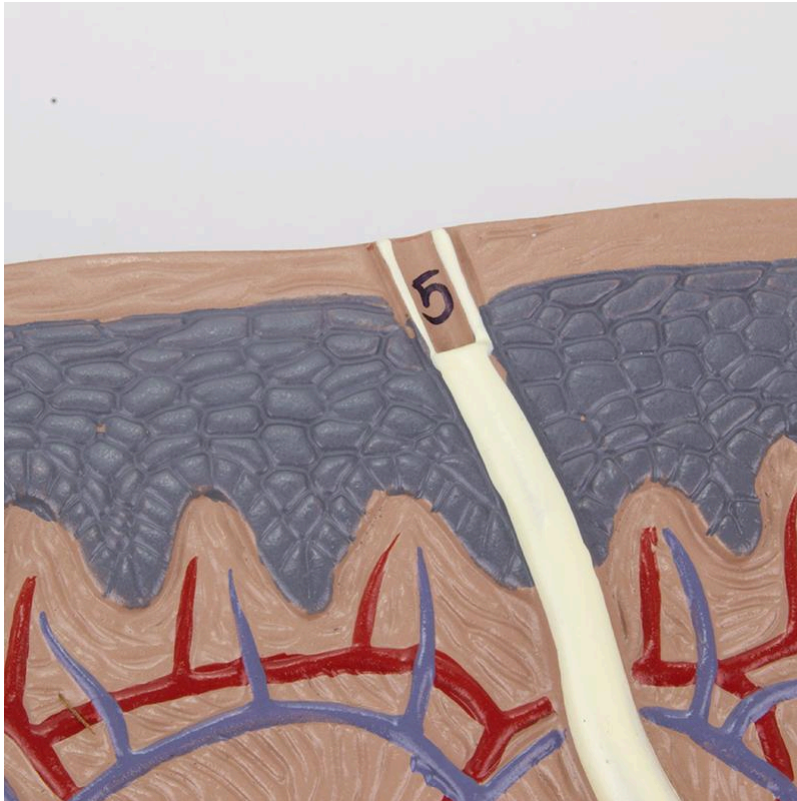


**MG31096 | HUMAN SKIN SECTION, 70 TIMES ENLARGED**









Enlarged anatomical model of hairy skin, displaying in detail the three main layers and structures such as hair follicles, sebaceous and sweat glands, arrector pili muscles, sensory corpuscles, nerves, and blood vessels. The anatomical structures are numbered for easy identification and learning.

**Applications:**

Ideal for detailed study of hairy skin anatomy, dermatology training, skin physiology education, and for demonstrations in clinical and educational settings.

**Technical Advantages:**

- \* Enlarged representation (70 times natural size) for detailed visualization of structures.
- \* Numbered anatomical structures for easy identification.
- \* Manufactured with durable synthetic material.
- \* Mounted on a resistant polymer base with support.

**3D Technology and Augmented Reality:**

Our anatomical models offer an innovative visual complement through informative cards that activate 3D models viewable in augmented reality (AR). This exclusive interactive platform stimulates learning, allowing comparative analysis of anatomical structures and offering opportunities for continuing education in anatomy, physiology, and pathophysiology.



### **Technical Specifications:**

- \* Scale: Enlarged 70 times
- \* Material: Durable synthetic material
- \* Base: Durable polymer with support
- \* Numbering: Numbered anatomical structures

### **Main Structures:**

**Stratum corneum:** The outermost layer of the epidermis, composed of dead and keratinized cells. It acts as a protective barrier against the external environment, preventing water loss and the entry of pathogens.

**Meissner's corpuscle:** Encapsulated sensory receptor located in the dermal papillae, especially abundant in areas sensitive to touch, such as the fingertips. It responds to light touch stimuli and low-frequency vibrations.

**Stratum spinosum:** Layer of the epidermis rich in keratinocytes interconnected by desmosomes, conferring resistance and flexibility to the skin. The cells of this layer also contain lamellar granules that release lipids to waterproof the skin.

**Stratum granulosum:** Layer of the epidermis where keratinocytes begin the keratinization process, accumulating keratohyalin granules. The cells of this layer also release lipids that contribute to the skin's barrier function.

**Dermal papilla:** Projections of the dermis that extend into the epidermis, increasing the contact area between the two layers and providing nutrients to the keratinocytes. The dermal papillae contain blood capillaries and nerve endings.

**Epidermis:** The outermost layer of the skin, composed of keratinized stratified squamous epithelium. It acts as a protective barrier against the external environment, preventing water loss and the entry of pathogens.

**Dermis:** The intermediate layer of the skin, composed of dense irregular connective tissue. It contains blood vessels, nerves, hair follicles, sebaceous and sweat glands.

**Free nerve ending:** Non-encapsulated sensory receptor located in the epidermis and dermis. It responds to a variety of stimuli, including pain, temperature, itching, and pressure.

**Subcutaneous tissue:** The deepest layer of the skin, composed of adipose tissue and connective tissue. It acts as thermal insulation, energy reserve, and protection against impacts.

**Pacinian corpuscle (lamellar corpuscle):** Encapsulated sensory receptor located in the



deep dermis and subcutaneous tissue. It responds to high-frequency vibrations and deep pressure.

**Customizable Skin Tones:**

This anatomical model offers the option to choose between three skin tones to better represent human diversity and meet different educational and clinical needs. It is possible to choose between light skin, intermediate tone, and dark skin, providing greater realism and inclusion during training and demonstrations.

**About Anatomical Models:**

They are developed with resin replication technology, addressing the scarcity of natural anatomical parts for teaching and research. They present all the essential morphological characteristics with excellent cost-benefit, resistance, manual painting, and numbering for precise identification of structures.

**List of all visible structures:**

- Stratum corneum
- Meissner's corpuscle
- Stratum spinosum
- Stratum granulosum
- Dermal papilla
- Epidermis
- Dermis
- Free nerve ending
- Subcutaneous tissue
- Pacinian corpuscle (lamellar corpuscle)
- Hair root
- Sweat gland
- Reticular layer
- Arrector pili muscle
- Sebaceous gland
- Hair follicle
- Artery
- Vein
- Hair shaft
- Sweat gland duct