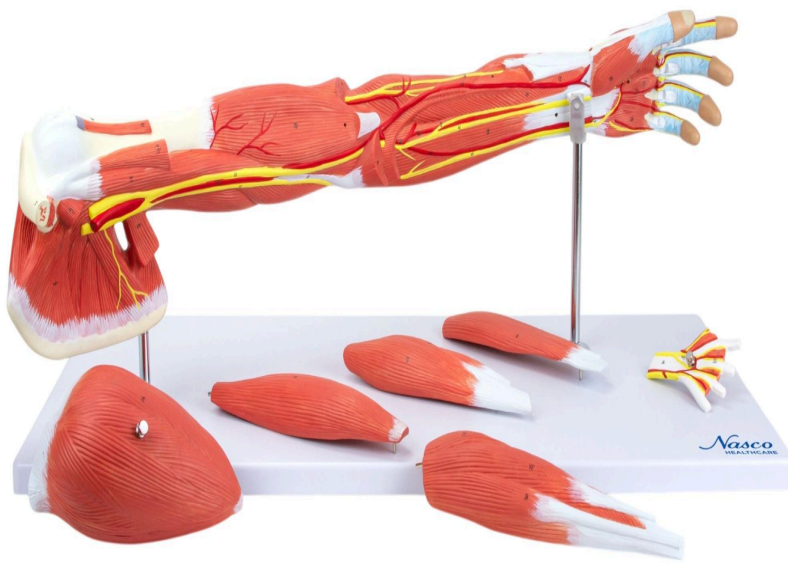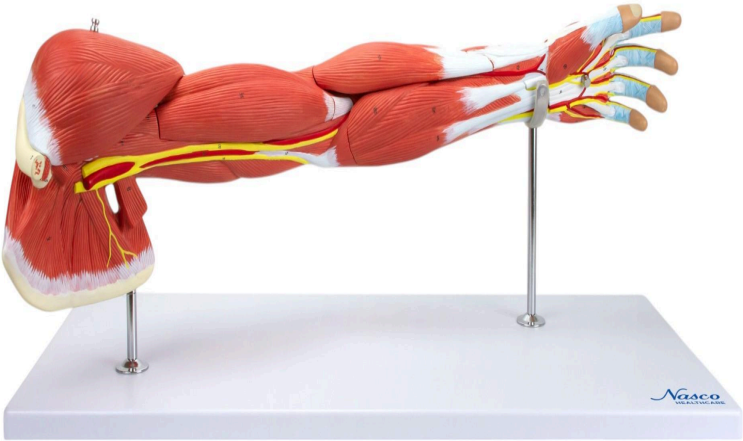
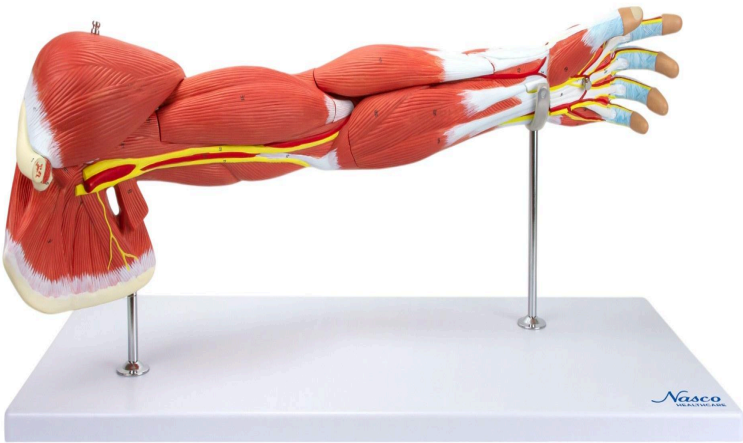


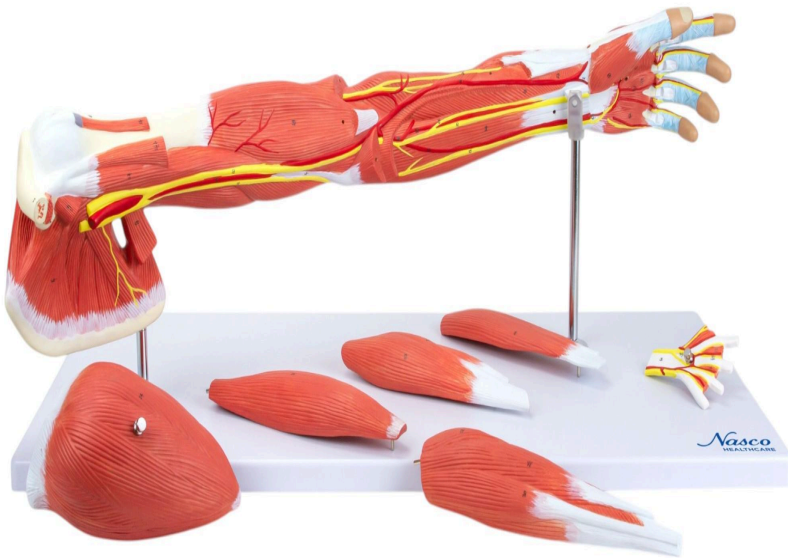MG21152 | MUSCLE OF ARM, 7 PARTS

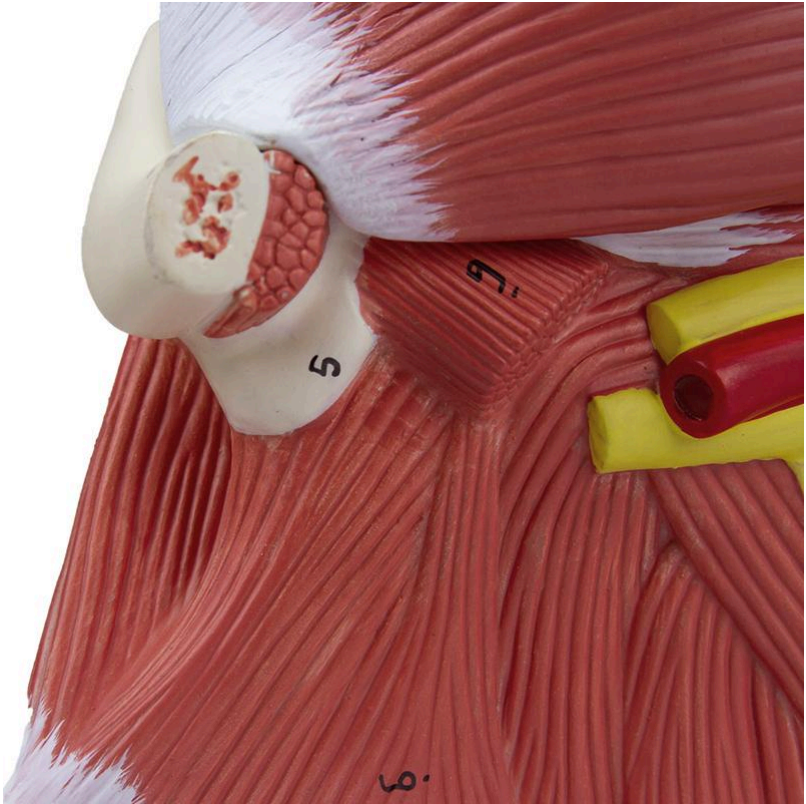
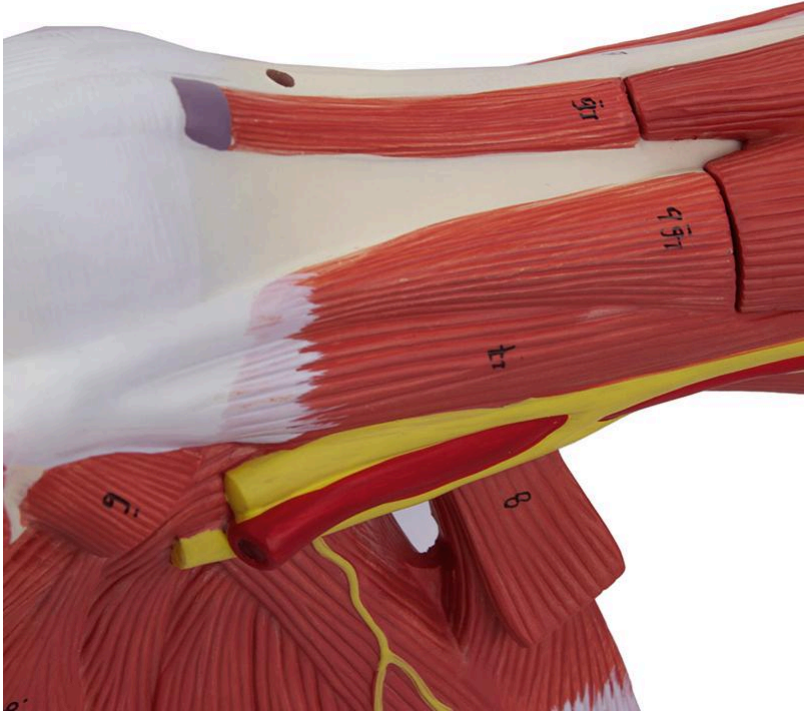


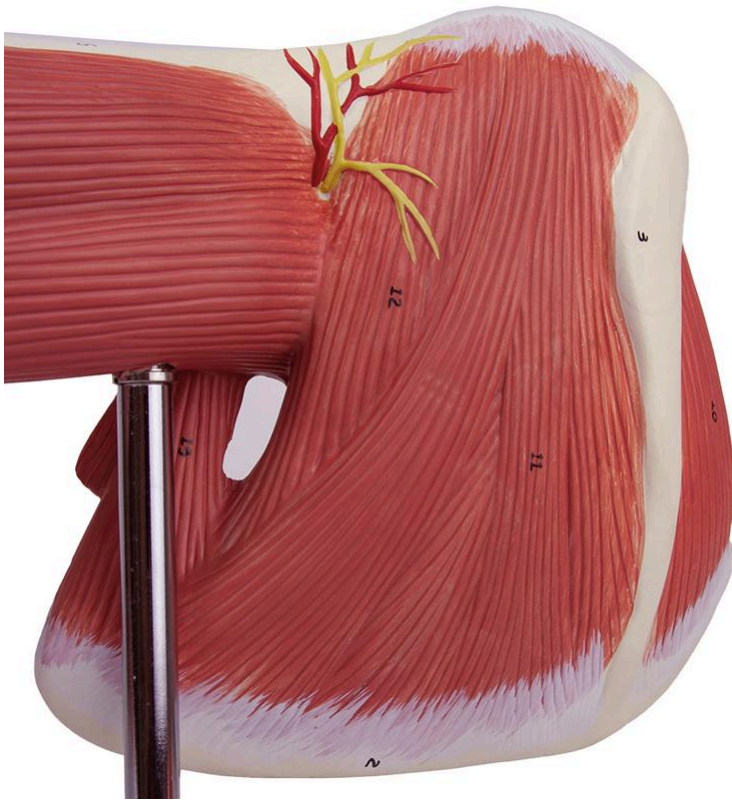Nasco
HEALTHCARE



Nasco
HEALTHCARE







This life-size anatomical model offers a detailed and comprehensive representation of the human arm structure, encompassing superficial and deep muscles, vascular structures, nerves, ligaments, as well as the hand and shoulder. For in-depth study, the model features removable parts, including the deltoid muscle, biceps, triceps, palmaris longus muscle with flexor carpi radialis muscle, brachioradialis muscle, extensor carpi radialis muscle, and palmar aponeurosis, facilitating internal visualization and understanding of anatomical relationships.

Applications:

Ideal for in-depth study of upper limb anatomy, this model is a valuable tool for higher education institutions, medical, physiotherapy, nursing, and related health courses. It is perfectly suited for classroom demonstrations, anatomy labs, practical training, and for the continuous improvement of knowledge in anatomy, physiology, and pathophysiology, allowing for comparative analysis of structures and understanding of their interactions.

Technical Differentiators:

This model stands out for its life-size representation, which offers a high level of detail of the anatomical structures of the arm, hand, and shoulder. The inclusion of various removable parts, such as muscles and aponeuroses, provides an interactive learning experience, allowing for exploration of the layers and relationships between structures. Its design aims to



facilitate the complex understanding of upper limb anatomy.

3D Technology and Augmented Reality:

Our anatomical models offer an innovative visual complement through informative cards that activate 3D models viewable in augmented reality (A.R.). This exclusive interactive platform stimulates learning, allowing for comparative analysis of anatomical structures and offering opportunities for continued education in anatomy, physiology, and pathophysiology.

Technical Specifications:

* Scale: Life-size

Main Structures:

Clavicle: It is a long, paired bone that forms the anterior portion of the shoulder girdle, connecting the sternum to the scapula. Its main function is to act as a pillar for the upper limb, transmitting forces from the arm to the trunk and protecting underlying neurovascular structures.

Scapula: Also known as the shoulder blade, it is a flat, triangular bone located on the posterior aspect of the thorax, which articulates with the humerus and clavicle. It serves as the origin and insertion point for several important shoulder and arm muscles, facilitating a wide range of movements.

Humerus: It is the longest bone of the upper limb, extending from the shoulder to the elbow. Its proximal end articulates with the scapula at the glenohumeral joint, while the distal end articulates with the ulna and radius, forming the elbow joint. It is fundamental for arm mobility and strength.

Radius: It is one of the two long bones of the forearm, located laterally (on the thumb side) in relation to the ulna. It articulates with the humerus at the elbow and with the carpal bones at the wrist, playing a crucial role in pronation and supination movements of the forearm and hand movements.

Deltoid muscle: It is a large, triangular muscle that covers the shoulder joint, giving it its rounded contour. It is the main muscle responsible for arm abduction, but also contributes to flexion, extension, and rotation of the humerus, being essential for shoulder mobility.

Biceps brachii muscle: Located on the anterior aspect of the arm, it is a muscle with two heads (long and short) that originates in the scapula and inserts into the radius. Its main function is elbow flexion and forearm supination, in addition to assisting in shoulder flexion.

Triceps brachii muscle: It is a large muscle located on the posterior aspect of the arm, composed of three heads (long, lateral, and medial) that unite to insert into the olecranon of



the ulna. It is the main extensor of the forearm at the elbow joint, being crucial for pushing and straightening the arm.

Median nerve: It is one of the main nerves of the brachial plexus, responsible for innervating a large part of the flexor muscles of the forearm and most of the muscles of the thenar eminence in the hand. It also provides sensitivity to the palm of the hand and some fingers, being vital for motor and sensory function of the hand.

Brachial artery: It is the continuation of the axillary artery and the main artery of the arm, running through the anterior compartment. It provides blood supply to the arm muscles and divides at the elbow into the ulnar and radial arteries, which irrigate the forearm and hand.

Superficial palmar arch: It is one of the main arterial anastomoses of the palm of the hand, formed mainly by the continuation of the ulnar artery and a superficial branch of the radial artery. From this arch, the common digital arteries originate, which supply the fingers, ensuring a robust blood supply to the hand.

Other structures can be verified directly on the physical piece or in the interactive 3D model.

Customizable Skin Tones:

This anatomical model offers the option to choose between three skin tones to better represent human diversity and meet different educational and clinical needs. It is possible to choose between light skin, intermediate tone, and dark skin, providing greater realism and inclusion during training and demonstrations.

Smart Tags:

Designed to provide comprehensive training in the healthcare field, with interactive simulations covering Pulse examinations. This solution assists in the development of diagnostic skills in different clinical scenarios, allowing professionals and students to explore and enhance their skills with greater safety and accuracy.

Virtual Patient Monitor: Provides an immersive and realistic training environment for healthcare students. It allows instructors to customize parameters for various vital signs, empowering students to interpret signals, develop critical thinking, and enhance their clinical reasoning skills through realistic scenarios.

Customizable Vital Signs

- Blood Pressure
- SpO2
- Heart Rate

ECG Interpretation: Train on 18 diverse ECG scenarios, including: Atrial Fibrillation, Ventricular Tachycardia and Heart Blocks. The monitor also simulates synchronized pulses with ECG for truly realistic cardiology training.



ECG Patterns

- Sinus Rhythm
- Atrial Extrasystole
- Atrial Flutter
- Atrial Fibrillation
- Paroxysmal Supraventricular Tachycardia (PSVT)
- Ventricular Extrasystole
- Ventricular Tachycardia (VT)
- Ventricular Fibrillation (VF)
- First-Degree Atrioventricular Block (AVB)
- Second-Degree Atrioventricular Block
- Third-Degree Atrioventricular Block (Complete Block)
- Long QT Syndrome
- ST Segment Elevation
- ST Segment Depression
- T Wave Inversion
- Left Ventricular Hypertrophy (LVH)
- Right Ventricular Hypertrophy (RVH)
- Wolff-Parkinson-White Syndrome (WPW)

Breathing Patterns

- Normal
- Dyspnea
- Apnea
- Cheyne-Stokes
- Biot
- Kussmaul

About Anatomical Models:

They are developed with resin replication technology, addressing the scarcity of natural anatomical pieces for teaching and research. They present all the essential morphological characteristics with excellent cost-benefit, resistance, manual painting, and numbering for precise identification of structures.

List of all visible structures:

- Proper palmar digital artery
- Proper palmar digital nerve
- Abductor digiti minimi muscle
- Flexor digiti minimi brevis muscle
- Common palmar digital artery



- Common palmar digital nerve
- Lumbrical muscles
- Superficial palmar arch
- Flexor digitorum superficialis tendon
- Flexor pollicis brevis muscle
- Abductor pollicis brevis muscle
- Superficial palmar branch of the radial artery
- Pronator quadratus muscle
- Palmaris longus muscle
- Flexor carpi radialis muscle
- Pronator teres muscle
- Brachioradialis muscle
- Extensor carpi radialis longus muscle
- Extensor carpi radialis brevis muscle
- Biceps brachii muscle
- Medial intermuscular septum of the arm
- Ulnar nerve
- Brachial artery
- Median nerve
- Latissimus dorsi muscle
- Subscapularis muscle
- Coracobrachialis muscle
- Pectoralis minor muscle
- Coracoid process
- Clavicle
- Deltoid muscle
- Acromion
- Subclavius muscle
- Spine of the scapula
- Supraspinatus muscle
- Scapula
- Teres minor muscle
- Teres major muscle
- Lateral head
- Triceps brachii muscle
- Medial head
- Olecranon
- Anconeus muscle
- Flexor carpi ulnaris muscle
- Extensor digitorum muscle
- Extensor digiti minimi muscle
- Extensor carpi ulnaris muscle
- Radius



- Extensor digitorum tendon
- Dorsal interosseous muscle
- Dorsal palmar artery
- Metacarpal bone
- Dorsal digital artery
- Dorsal digital aponeurosis
- Deep brachial artery
- Radial nerve
- Proper palmar digital artery
- Proper palmar digital nerve
- Abductor digiti minimi muscle
- Flexor digiti minimi brevis muscle
- Palmar metacarpal artery
- Palmar interosseous muscle
- Adductor pollicis muscle
- Flexor pollicis brevis muscle
- Abductor pollicis brevis muscle
- Deep palmar arch
- Deep palmar branch
- Superficial palmar branch of radial artery
- Pronator quadratus muscle
- Radial nerve
- Flexor digitorum profundus muscle
- Median nerve
- Anterior interosseous nerve
- Flexor pollicis longus muscle
- Ulnar artery
- Anterior interosseous artery
- Common interosseous artery
- Medial intermuscular septum of arm
- Ulnar nerve
- Brachial artery
- Median nerve
- Latissimus dorsi muscle
- Subscapularis muscle
- Pectoralis major muscle
- Coracoid process
- Coracobrachialis muscle
- Humerus
- Long head
- Short head
- Radial nerve
- Deep brachial artery



- Acromion
- Clavicle
- Supraspinatus muscle
- Spine of scapula
- Infraspinatus muscle
- Scapula
- Teres minor muscle
- Teres minor muscle
- Long head
- Lateral head
- Triceps brachii muscle
- Medial head
- Olecranon
- Anconeus muscle
- Flexor carpi ulnaris muscle
- Recurrent interosseous artery
- Supinator muscle
- Posterior interosseous artery
- Posterior interosseous nerve
- Radius
- Abductor pollicis longus muscle
- Extensor pollicis brevis muscle
- Extensor pollicis longus muscle
- Extensor indicis muscle
- Radius
- Extensor digitorum tendon
- Adductor pollicis muscle
- Dorsal palmar artery
- Metacarpal bone
- Dorsal digital artery
- Dorsal aponeurosis of finger