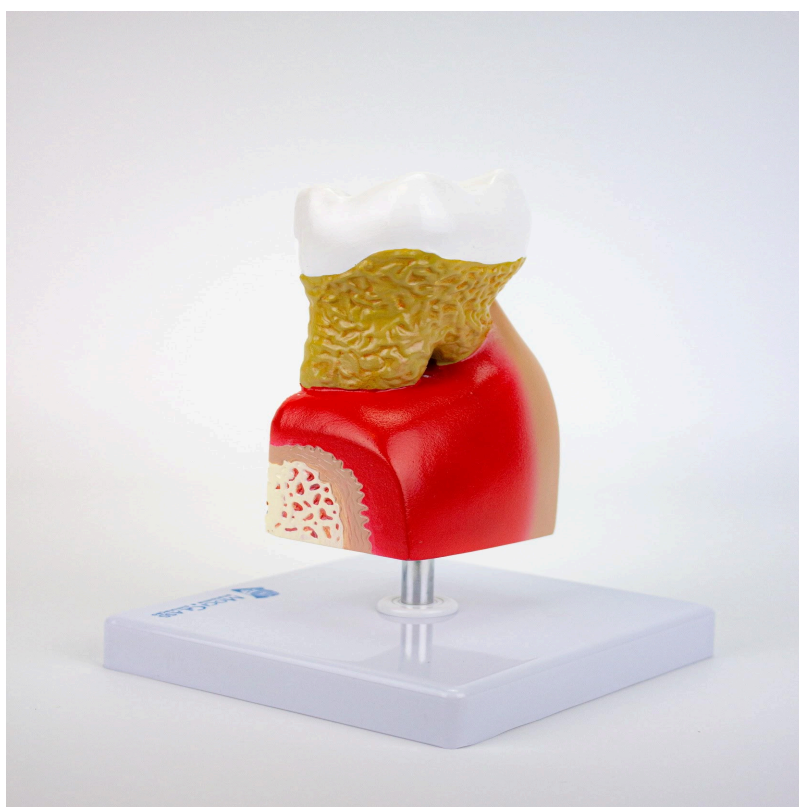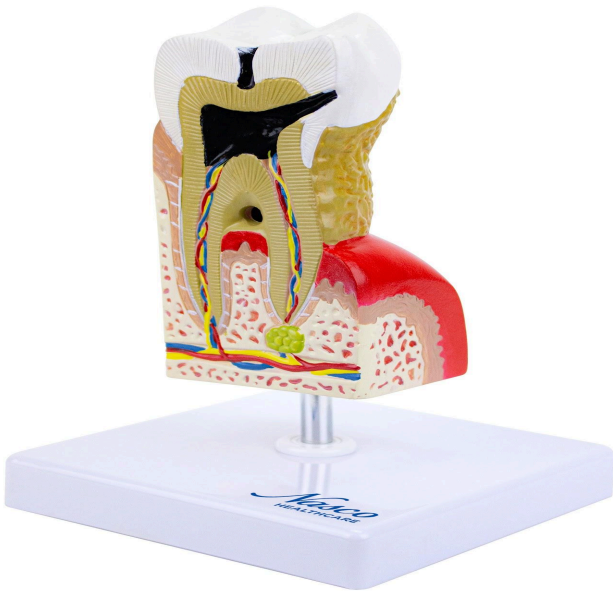

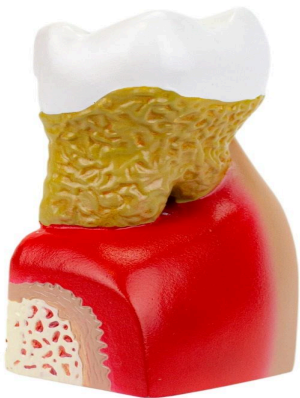


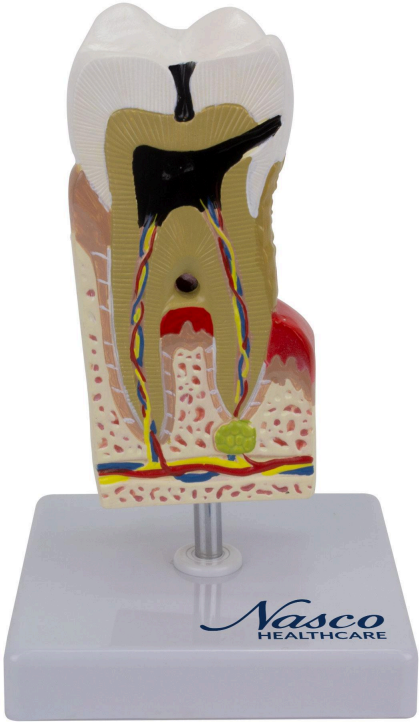**MG22727 | DENTAL DISEASE, 10 TIMES ENLARGED**



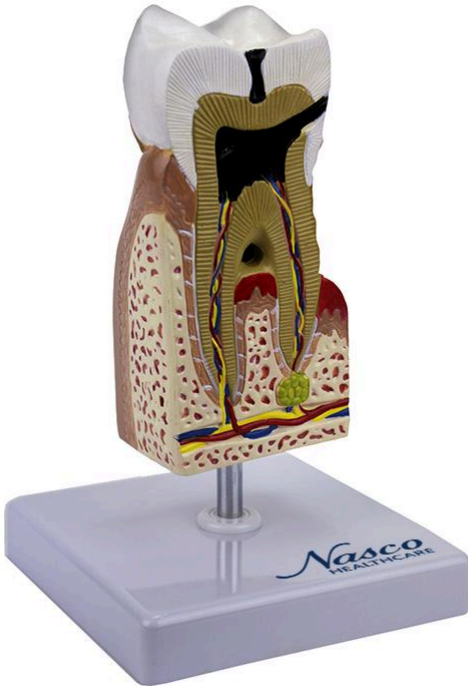
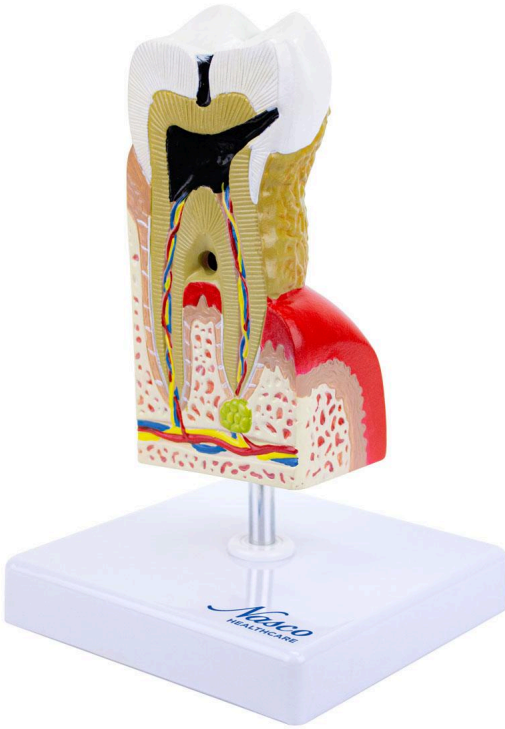*Nasco*  
HEALTHCARE

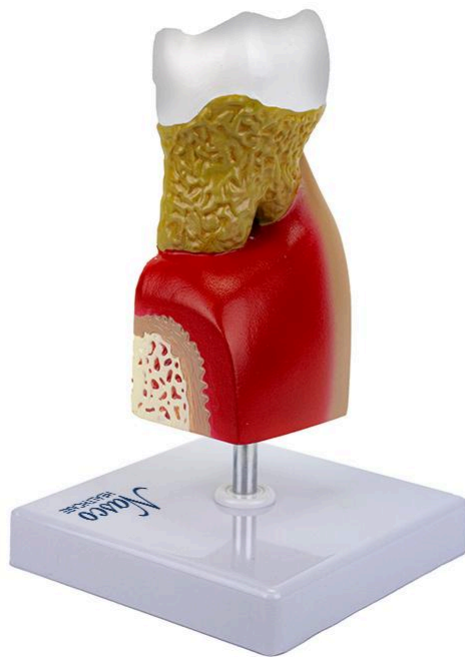

*Nasco*  
HEALTHCARE



*Nasco*  
HEALTHCARE





This model meticulously details major dental pathologies: caries, pulpitis, gingivitis, and periapical periodontitis. It features a high level of detail and is mounted on a polymer base with a metal support and rod, allowing for complete visualization and ease of handling.

#### **Applications:**

This model is ideal for the study of dentistry and orthodontics, oral surgery training, science education, patient education, and demonstration of dental procedures.

#### **Technical Advantages:**

- \* High didactic value;
- \* Created from detailed original molds;
- \* Precise details for learning anatomy;
- \* Hand-painted;
- \* Manufactured from stable synthetic material;
- \* Resin approved in toxicological tests;
- \* High-fidelity natural molding;



\* Precise replicas.

### **3D Technology and Augmented Reality:**

Our anatomical models offer a visual complement through informative cards that activate 3D models viewable in augmented reality (AR). This interactive platform assists the learning process, allowing for comparative analysis of anatomical structures and offering resources for continuing education in anatomy, physiology, and pathophysiology.

### **Technical Specifications:**

\* Scale: 10 times natural size;

\* Material: Resin.

### **Main Structures:**

**Dental Caries:** Dental caries is an infectious disease caused by bacteria that produce acids which demineralize enamel and dentin, leading to the progressive destruction of dental tissues.

**Enamel:** Enamel is the outer layer of the tooth, the most mineralized and resistant in the human body. Its main function is to protect the inner structures of the tooth against masticatory forces and external agents.

**Dentin:** Dentin is a mineralized connective tissue that forms the majority of the tooth structure, located beneath the enamel. It is more porous than enamel, making it less resistant to caries.

**Infected Pulp:** The dental pulp, a soft connective tissue rich in blood vessels and nerves, when infected, undergoes inflammation (pulpitis) which can cause intense pain. The infection can progress to pulpal necrosis.

**Cementum:** Cementum is a mineralized tissue that covers the root of the tooth, anchoring it to the alveolar bone. Its function is to anchor the tooth to the periodontal ligament.

**Gingivitis:** Gingivitis is an inflammation of the gums, usually caused by bacterial plaque. It is characterized by redness, swelling, and bleeding gums.

**Periodontitis:** Periodontitis is a chronic infection that affects the tissues supporting the teeth (periodontal ligament, alveolar bone, and cementum), and can lead to tooth loss.



**Alveolar Bone:** The alveolar bone is the bone that forms the dental alveolus, the bony cavity that houses the root of the tooth. Its structure is adapted to receive and withstand masticatory forces.

**Abscess:** An abscess is a localized collection of pus, usually the result of an infection. In dentistry, it can occur in the dental pulp or periodontal tissues.

**Blood Vessels:** The dental pulp and gingiva are richly vascularized, with blood vessels essential for the nutrition and inflammatory response of these tissues. Other structures can be viewed directly on the physical piece or the interactive 3D model.

#### **About the Anatomical Models:**

These are developed with resin replication technology, meeting the demand for anatomical pieces for teaching and research. They present the essential morphological characteristics with excellent cost-benefit, good resistance, hand painting, and numbering for precise identification of structures.

Request information or a demonstration to learn about our anatomical models and provide an enhanced learning experience at your institution.

#### **List of all visible structures:**

- dental caries
- enamel
- dentin
- dental caries
- infected pulp
- cementum
- inflammation
- blood vessels
- periodontitis
- gingivitis
- alveolar bone
- abscess
- blood vessels