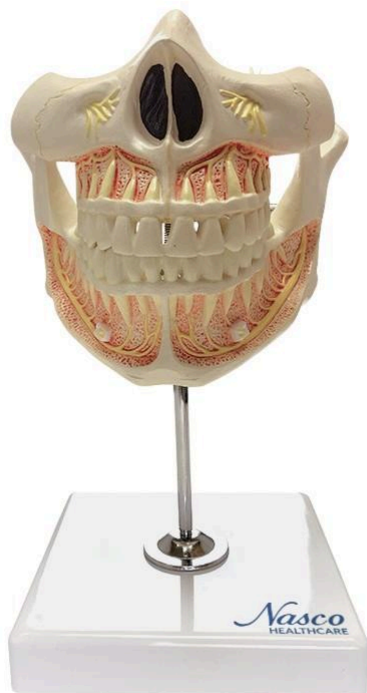
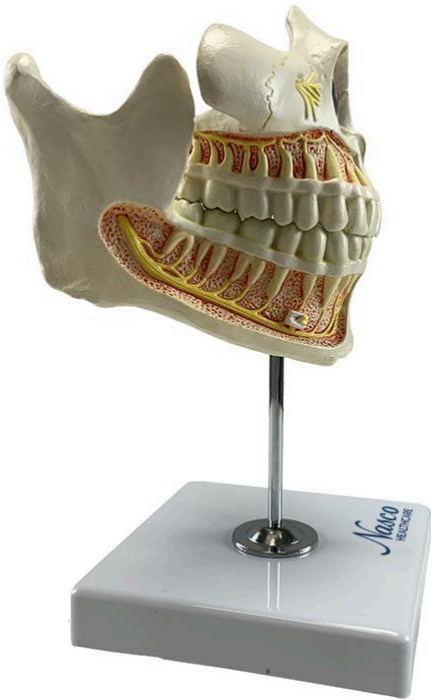
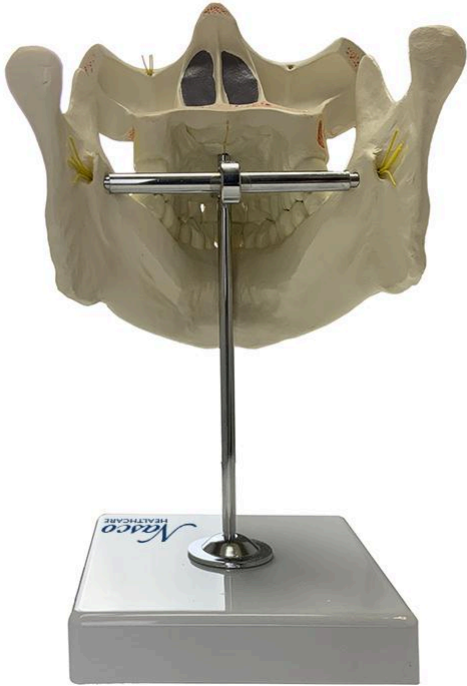


## **MG22594 | ADULT DENTURE MODEL WITH NERVES AND ROOTS**



*Nasco*  
HEALTHCARE





A life-size model demonstrating a complete adult dentition, including a movable upper and lower jaw, allowing for the simulation of mastication. The model details all 32 permanent teeth, with visible roots, fibers, and nerves, numbered and hand-painted for ease of learning.

**Applications:**

Ideal for the study of dentistry in schools and universities, oral surgery training, science education, patient education, and demonstration of dental procedures. Also suitable for dentistry, orthodontics, and general anatomical study.

**Technical Features:**

- \* High didactic level;
- \* Numbered and hand-painted;
- \* High-precision natural molding;
- \* Manufactured from stable and resistant synthetic material;
- \* Detailed replicas;
- \* Includes an information card with related structures;
- \* Polymer base with support and metal rod;
- \* Resin approved in toxicological tests.

**3D Technology and Augmented Reality:**

Our anatomical models offer a visual complement through information cards that activate 3D models viewable in augmented reality (AR). This interactive platform assists learning, allowing for comparative analysis of anatomical structures and offering resources for continuing education in anatomy, physiology, and pathophysiology.

**Technical Specifications:**

- \* Scale: Life-size
- \* Material: Synthetic resin

**Main Structures:**

**Central incisor:** These are the anterior teeth of the dental arch, responsible for the incision of food. Located on the midline of the maxilla and mandible, they are the most prominent teeth in the arch.

**Lateral incisor:** Located laterally to the central incisors, in the maxilla and mandible, these teeth also contribute to the incision of food. They are smaller than the central incisors.

**Canine:** Pointed teeth located laterally to the lateral incisors, in both the maxilla and mandible. Their main function is to lacerate and pierce food.

**First premolar:** The first premolars are the teeth posterior to the canines, in both the maxilla



and mandible. They have two cusps and participate in the process of grinding food.

**Second premolar:** Located posterior to the first premolars, in the maxilla and mandible, the second premolars also contribute to the grinding of food. They have two cusps, similar to the first premolars.

**First molar:** The first molars are the teeth posterior to the premolars, characterized by four cusps, and actively participate in the grinding and milling of food.

**Second molar:** Located posterior to the first molars, in the maxilla and mandible, these teeth are also important for the grinding and milling of food.

**Third molar (Wisdom tooth):** The third molars, also known as wisdom teeth, are the last molars to erupt in the dental arch. Their eruption can be variable, and they often cause impaction problems.

**Maxilla:** The bone that forms the hard palate, the upper part of the dental arch, and part of the eye socket. Its complex structure houses the dental alveoli and maxillary sinuses.

**Mandible:** The movable bone of the lower dental arch, articulating with the temporal bone through the temporomandibular joint (TMJ). Its structure is robust and houses the lower dental alveoli. Other structures can be verified directly on the physical piece or the interactive 3D model.

#### **About the Anatomical Models:**

They are developed with resin replication technology, supplying the scarcity of natural anatomical pieces for teaching and research. They present the essential morphological characteristics with excellent cost-benefit, good resistance, manual painting, and numbering for precise identification of structures.

#### **List of all visible structures:**

- Zygomatic bone
- Infraorbital foramen
- Nasal bone
- Nasal septum
- Maxilla
- Condyle process
- Coronoid process
- Mandibular incisure
- Canine
- Lateral incisor



- Body of the mandible
- Mandibular angle
- Mandible
- Mental tubercle
- Mental foramen
- Inferior alveolar nerve
- Third molar
- Second molar
- First molar
- Second premolar
- First premolar
- Central incisor
- Infraorbital nerve
- Posterior superior alveolar nerves