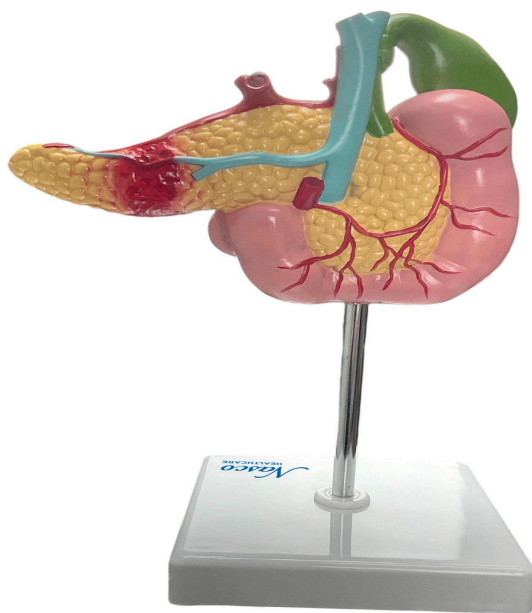
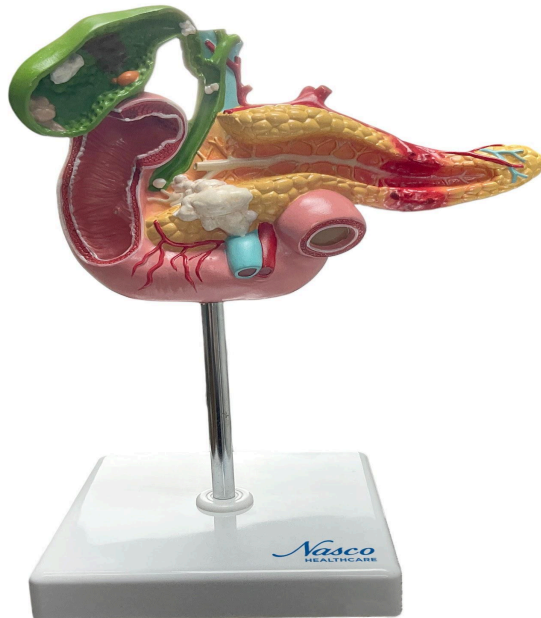



## **MG30031 | HUMAN PANCREAS, DUODENUM AND GALLBLADDER WITH PATHOLOGY**





This life-size anatomical model presents a detailed representation of the pancreas, duodenum, and gallbladder, including important pathologies. The gallbladder, partially opened, shows gallstones, cholecystitis, polyps, and an example of carcinoma. The pancreas demonstrates a representation of pancreatitis in the tail and cancer in the head. A section of the duodenum displays a duodenal ulcer. The model is mounted on a polymer base with a metal support and rod, and comes with references and markings to facilitate study.

#### **Applications:**

Ideal for the study of anatomy in schools and universities; surgical dissection training; assisting in patient explanations; demonstrations in medical and scientific contexts; use in clinics; classrooms; patient education and procedure demonstration; study of the digestive system and anatomical study.

#### **Technical Characteristics:**

- \* Detailed representation of anatomical structures and pathologies;
- \* High fidelity in manufacturing;



- \* Quality natural molding;
- \* Hand-painted;
- \* Manufactured from stable synthetic material and resin with toxicological test approval;
- \* Precise replicas;
- \* Includes an information card with an interactive 3D model in augmented reality.

### **3D Technology and Augmented Reality:**

Our anatomical models offer a visual complement through information cards that activate 3D models viewable in augmented reality (AR). This interactive platform assists learning, allowing for comparative analysis of anatomical structures and offering resources for continuing education in anatomy, physiology, and pathophysiology.

### **Technical Specifications:**

- \* Scale: Life-size
- \* Material: Synthetic resin
- \* Numbered references and markings

### **Main Structures:**

**Duodenum:** The initial portion of the small intestine, C-shaped, which receives chyme from the stomach, as well as secretions from the pancreas and gallbladder. It has four parts: superior, descending, horizontal, and ascending.

**Pancreatic duct:** Duct that transports digestive enzymes produced by the pancreas to the duodenum. It joins the common bile duct to form the ampulla of Vater, which empties into the duodenum.

**Biliary duct:** Canal that transports bile produced in the liver to the gallbladder for storage and concentration, or directly to the duodenum.

**Gallbladder:** Pear-shaped organ located under the liver, responsible for the storage and concentration of bile.

**Carcinoma:** Malignant tumor originating in epithelial cells. In this model, an example of gallbladder carcinoma is represented.

**Gallstone:** Concretions that form in the gallbladder or bile ducts, composed mainly of cholesterol, bilirubin, or calcium salts.



**Polyps:** Small protrusions that develop on the gallbladder wall, which can be benign or malignant.

**Pancreatitis:** Inflammation of the pancreas, which can be acute or chronic. In this model, pancreatitis in the tail of the pancreas is represented.

**Cancer:** Disease characterized by the uncontrolled growth of abnormal cells. In this model, an example of pancreatic head cancer is represented.

**Common Bile Duct:** Canal formed by the union of the common hepatic duct and the cystic duct, which transports bile from the liver and gallbladder to the duodenum.

Other structures can be verified directly on the physical piece or on the interactive 3D model.

#### **About Anatomical Models:**

They are developed with resin replication technology, offering an alternative for teaching and research. They present the main morphological characteristics with a good cost-benefit ratio, resistance, hand painting, and numbering for precise identification of structures.

#### **List of all visible structures:**

- - Metastasis on the liver
- - Carcinoma on the gallbladder
- - Gallstone within the gallbladder
- - Polyps on the inner lining of the duodenum
- - Duodenal Ulcer on the outer surface of the duodenum
- - Pancreatitis on the head and body of the pancreas
- - Cancer on the tail of the pancreas