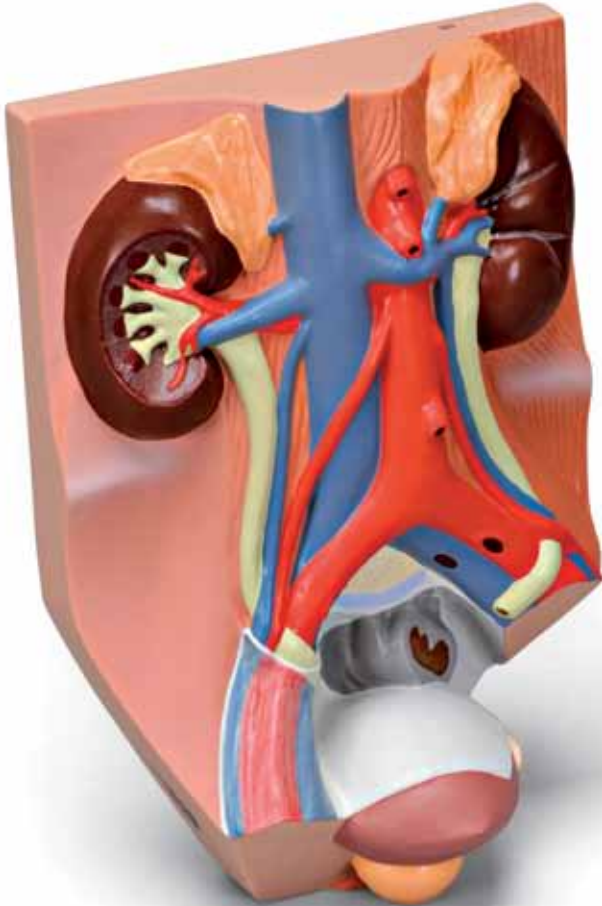




...going one step further



VF325

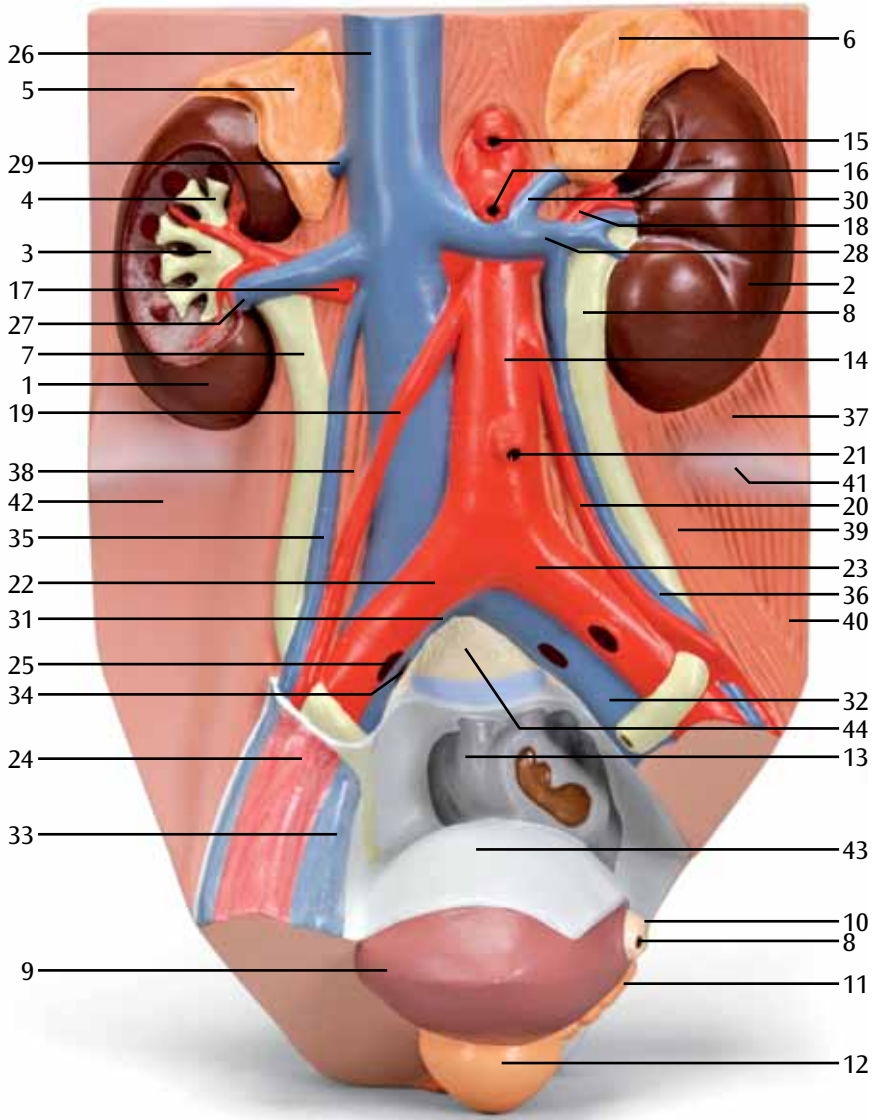
(1008551)

Male urinary tract

English

- 1 Right kidney
- 2 Left kidney
- 3 Renal pelvis
- 4 Renal calyces
- 5 Suprarenal gland, right
- 6 Suprarenal gland, left
- 7 Right ureter
- 8 Left ureter
- 9 Urinary bladder
- 10 Left spermatic duct
- 11 Left seminal vesicle
- 12 Prostate
- 13 Sigmoid
- 14 Abdominal aorta
- 15 Celiac artery
- 16 Superior mesenteric artery
- 17 Right renal artery
- 18 Left renal artery
- 19 Right testicular artery
- 20 Left testicular artery
- 21 Inferior mesenteric artery
- 22 Right common iliac artery
- 23 Left common iliac artery
- 24 Right external iliac artery
- 25 Right internal iliac artery
- 26 Vena cava inferior
- 27 Right renal vein
- 28 Left renal vein
- 29 Right suprarenal vein
- 30 Left suprarenal vein
- 31 Right common iliac vein
- 32 Left common iliac vein
- 33 Right external iliac vein
- 34 Right internal iliac vein
- 35 Right testicular vein
- 36 Left testicular vein
- 37 Left quadratus lumborum muscle
- 38 Right psoas major muscle
- 39 Left psoas major muscle
- 40 Left iliac muscle
- 41 Left iliac crest
- 42 Iliac fascia
- 43 Peritoneum
- 44 5th lumbar vertebra







3B SCIENTIFIC® PRODUCTS