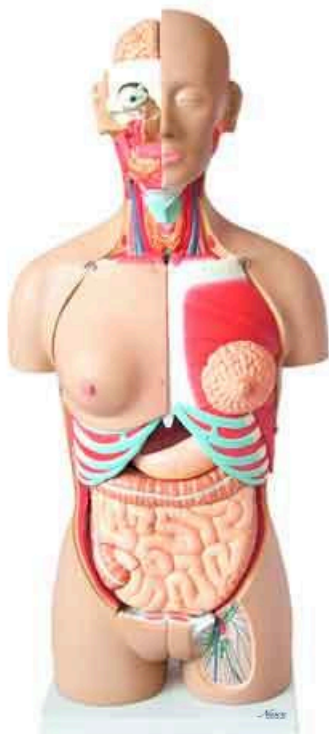
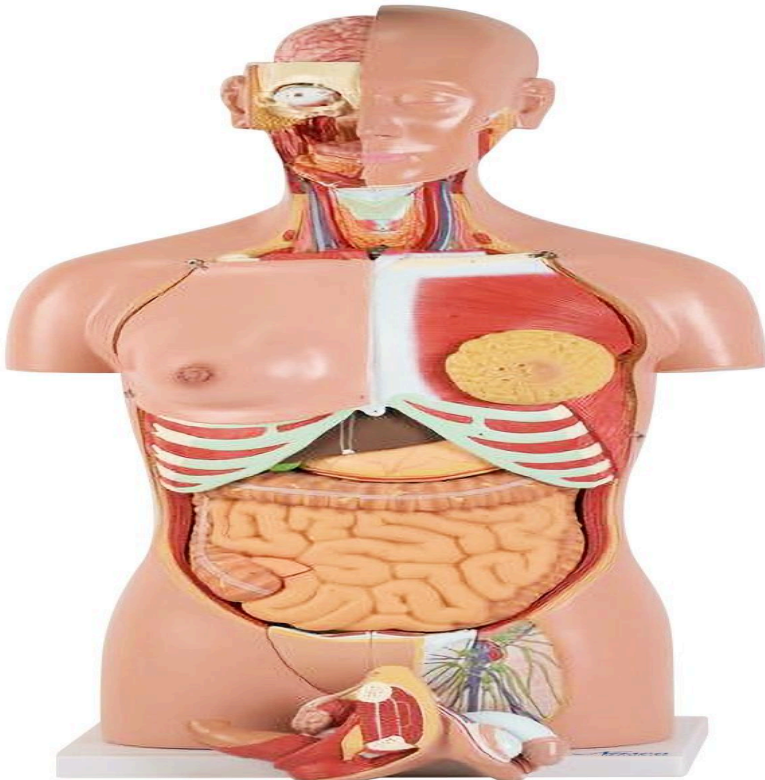
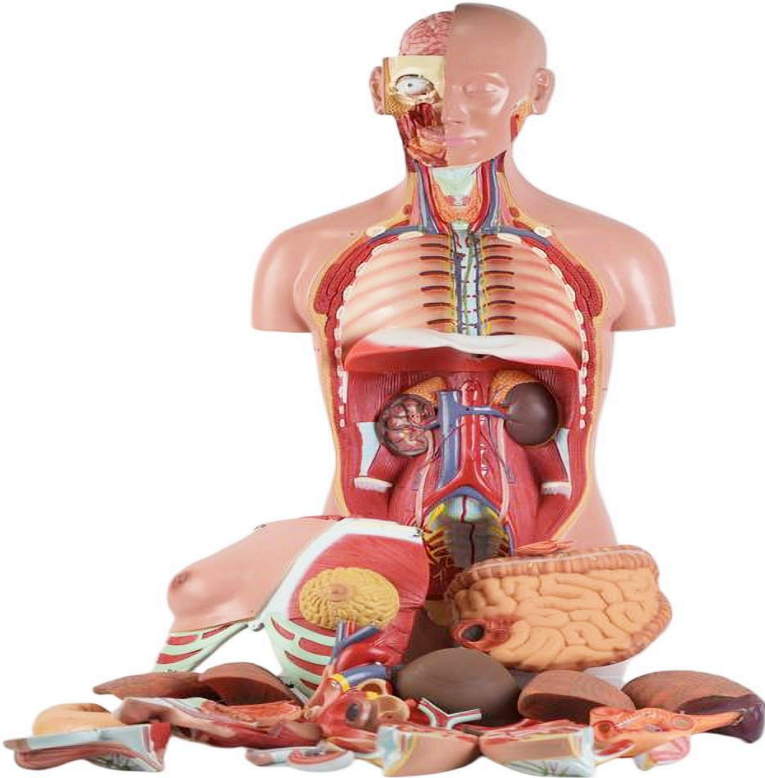



**MG31999 | CLASSIC DUAL-SEX HUMAN
TORSO WITH OPENED NECK AND BACK, 28
PARTS**



Nasco
HEALTHCARE





Life-size human body anatomical model, 28-part representation, realistic and detailed reproduction of anatomical structures. Designed with an open back, it exposes the muscle layers, vertebral column, and associated nerve branches, while the head opens to reveal the fully exposed brain on one side. The neck is dissected to display musculature, neural, vascular, and glandular structures, and the male and female urogenital systems are detachable and interchangeable, providing a comprehensive view of all body systems with full accessibility.

Applications:

This model is an invaluable addition to any biology or anatomy course, serving as an essential tool for in-depth study of the human body. It is ideal for educational institutions, research laboratories, and healthcare professionals seeking to enhance anatomical, physiological, and pathophysiological understanding through comparative structure analysis and continuing education.

Technical Differentiators:

- * Life-size representation with 28 removable and interchangeable parts.
- * Realistic and detailed reproduction of all anatomical structures.
- * Open back design, exposing muscle layers, vertebral column, and nerve branches.
- * Head with opening for detailed brain exposure.
- * Dissected neck, revealing musculature, neural, vascular, and glandular structures.
- * Detachable and interchangeable male and female urogenital systems.
- * Significant structures numbered and referenced in an explanatory leaflet.
- * Inclusion of various removable structures for in-depth study, such as: Eye with optic nerve and extraocular muscles; Half of the brain (with internal structures and blood vessels); Trachea; Descending thoracic aorta and esophagus; Right and left lungs (2 pieces each), with bronchial tree and vasculature; Liver with gallbladder; Half of a kidney in frontal section; Heart in 2 parts (with description of atria, ventricles, valves, and wall); Stomach dissected in 2 parts; Pancreas, stomach, duodenum, and spleen with vessels and ducts; Small and large intestines with removable cover over the cecum portion; Male and female urogenital systems (4 parts each), sectioned; Thoracic vertebra (T12) with removable spinal cord; Female thoracic wall.

3D Technology and Augmented Reality:

Our anatomical models offer an innovative visual complement through informative cards that activate 3D models viewable in augmented reality (AR). This exclusive interactive platform stimulates learning, allowing for comparative analysis of anatomical structures and offering opportunities for continuing education in anatomy, physiology, and pathophysiology.

Technical Specifications:

- * Scale: Life-size
- * Number of parts: 28



Main Structures:

Cecum: The cecum is the first portion of the large intestine, located in the lower right quadrant of the abdomen. It acts as a reservoir for chyme passing from the small intestine, initiating the process of water and electrolyte absorption and stool formation. The vermiform appendix is attached to the cecum.

Ileum: The ileum is the final portion of the small intestine, following the jejunum and ending at the ileocecal junction. Its main function is the absorption of nutrients not absorbed in the previous parts of the small intestine, especially vitamin B12 and bile salts.

Intestine: The intestine is a vital part of the digestive system, divided into the small intestine (duodenum, jejunum, and ileum) and the large intestine (cecum, colon, and rectum). The small intestine is responsible for most of the digestion and absorption of nutrients, while the large intestine handles water and electrolyte absorption and stool formation and elimination.

Jejunum: The jejunum is the middle portion of the a small intestine, located between the duodenum and ileum. It is the main region for the absorption of carbohydrates, proteins, and fats, due to its large surface area and rich vascularization.

Transverse colon: The transverse colon is the part of the large intestine that extends horizontally across the upper abdominal cavity, connecting the ascending colon to the descending colon. It is responsible for the continuous absorption of water and electrolytes from the chyme, consolidating the feces.

Descending colon: The descending colon is the portion of the large intestine that extends downward on the left side of the abdomen, from the transverse colon to the sigmoid colon. Its main function is to store formed feces before their elimination, continuing the absorption of water and compaction of fecal material.

Ascending colon: The ascending colon is the first part of the large intestine, extending upward from the cecum on the right side of the abdomen. Its main function is to absorb the remaining water and other digested nutrients from the semi-liquid food material arriving from the small intestine, transforming it into semi-solid feces.

Internal oblique muscle of the abdomen: The internal oblique muscle of the abdomen is one of the muscle layers of the anterolateral abdominal wall, located deep to the external oblique. It contributes to trunk rotation and flexion, in addition to assisting in the compression of abdominal viscera and forced exhalation.

Transverse abdominal muscle: The transverse abdominal muscle is the deepest layer of the abdominal musculature, with horizontally oriented fibers. Its main function is to compress



the abdominal viscera, increasing intra-abdominal pressure, which is crucial for activities such as coughing, sneezing, defecation, and childbirth.

Pyloric antrum: The pyloric antrum is the most distal portion of the stomach, located before the pylorus. It acts as a mixing chamber where food is crushed and mixed with gastric juices before being gradually released into the duodenum through the pyloric sphincter.

Round ligament of the liver: The round ligament of the liver is a fibrous remnant of the fetal umbilical vein, which extends from the umbilical scar to the inferior surface of the liver. Although it has no function in the adult, it is an important anatomical structure for orientation and may be relevant in certain clinical conditions.

Other structures can be verified directly on the physical piece or in the interactive 3D model.

Customizable Skin Tones:

This anatomical model offers the option of choosing between three skin tones to better represent human diversity and meet different educational and clinical needs. It is possible to choose between light skin, medium tone, and dark skin, providing greater realism and inclusion during training and demonstrations.

Smart Tags:

Designed to provide comprehensive training in the healthcare field, with interactive simulations covering Retina, Ear, Throat, Pulse, Heart, Lung, and Abdominal exams. This solution assists in the development of diagnostic skills in different clinical scenarios, allowing professionals and students to explore and enhance their skills with greater safety and accuracy.

Heart sound recognition: Recognize 23 unique heart sounds with different patient postures and tools.

- Apex, Normal S1 S2, Supine, Bell
- Apex, Split S1, Supine, Bell
- Apex, S4, LLD, Bell
- Apex, Mid Systolic Click, Supine, Bell
- Apex, S3, LLD, Bell
- Apex, Early Systolic Murmur, Supine, Bell
- Apex, Mid Systolic Murmur, Supine, Bell
- Apex, Late Systolic Murmur, Supine, Bell
- Apex, Holosystolic Murmur, Supine, Bell
- Apex, Systolic Click & Late Systolic Murmur, LLD, Bell
- Apex, S4 & Mid Systolic Murmur, LLD, Bell
- Apex, S3 & Holosystolic Murmur, LLD, Bell
- Apex, OS & Diastolic Murmur, LLD, Bell
- Aortic, Normal S1 S2, Sitting, Bell



- Aortic, Systolic Murmur & Absent S2, Sitting, Bell
- Aortic, Early Diastolic Murmur, Sitting, Bell
- Aortic, Systolic & Diastolic Murmur, Sitting, Bell
- Pulmonary, Single S2, Supine, Diaphragm
- Pulmonary, Split S2 Persistent, Supine, Diaphragm
- Pulmonary, Split S2 Transient, Supine, Diaphragm
- Pulmonary, Ejection Systolic Murmur & Transient Split S2, Supine, Diaphragm
- Pulmonary, Split S2 & Ejection Systolic Murmur, Supine, Diaphragm
- Pulmonary, Ejection Systolic Murmur & Single S2 & Ejection Click, Supine, Diaphragm

Retinal exams: Simulate 39 retinal conditions, from normal and diabetic retinopathy (various stages) to rare diseases like retinitis pigmentosa and macular degeneration.

- Normal
- Tessellated Fundus
- Large Optic Disc Cupping
- DR1 (Diabetic Retinopathy - Stage 1)
- DR2 (Diabetic Retinopathy - Stage 2)
- DR3 (Diabetic Retinopathy - Stage 3)
- Branch Retinal Vein Occlusion (BRVO)
- Central Retinal Vein Occlusion (CRVO)
- Retinal Artery Occlusion (RAO)
- Rhegmatogenous Retinal Detachment
- Central Serous Chorioretinopathy (CSCR)
- Vogt-Koyanagi-Harada Disease (VKH)
- Maculopathy
- Epiretinal Membrane (ERM)
- Macular Hole (MH)
- Pathological Myopia
- Possible Glaucoma
- Optic Atrophy
- Severe Hypertensive Retinopathy
- Optic Disc Swelling and Elevation
- Displaced Optic Disc
- Congenital Optic Disc Anomaly
- Retinitis Pigmentosa
- Bietti's Crystalline Dystrophy
- Peripheral Retinal Degeneration and Tear
- Myelinated Nerve Fibers
- Particles in Vitreous
- Fundus Neoplasia
- Massive Hard Exudates
- Yellowish-White Spots (Flecks)
- Cotton Wool Spots



- Vessel Tortuosity
- Chorioretinal Atrophy - Coloboma
- Preretinal Hemorrhage
- Fibrosis
- Laser Marks
- Silicone Oil in Eye
- Blurred Fundus Without PDR (Proliferative Diabetic Retinopathy)
- Blurred Fundus With Suspected PDR (Proliferative Diabetic Retinopathy)

Ear exams: Conduct 9 realistic diagnostic exams.

- AOM
- Chronic
- Ear Ventilation
- Earwax
- Foreign Object
- Normal
- Otitis Externa
- Pseudomembrane
- Tympanosclerosis

Throat exams: Conduct 6 realistic diagnostic exams.

- Normal
- Oral Cancer (Benign)
- Oral Cancer (Malignant)
- Oral Dysplasia
- Pharyngitis
- Tonsillitis

Lung sound recognition: Recognize 15 lung sounds and breathing pattern analysis.

- Agonal Breathing
- Asthma Wheezing
- Bronchial
- Bronchovesicular
- Crackles - Coarse
- Crackles - Fine
- Crackles - Pulmonary Edema
- Crackles - Bronchiectasis
- Death Rattle
- Inspiratory Stridor
- Pleural Rubs
- Rhonchi - Low-Pitched Wheezes
- Vesicular - Normal
- Wheeze



- Wheeze-COPD

Abdominal sound diagnostics:

- Normal
- Normal Borborygmi
- Normal Gurgling
- Diarrhea
- Hyperactive
- Hypoactive
- Obstruction
- Absent

Virtual Patient Monitor: Provides an immersive and realistic training environment for healthcare students. It allows instructors to customize parameters for various vital signs, empowering students to interpret signals, develop critical thinking, and enhance their clinical reasoning skills through realistic scenarios.

Customizable Vital Signs

- Blood Pressure
- SpO2
- Heart Rate

ECG Interpretation: Train on 18 diverse ECG scenarios, including: Atrial Fibrillation, Ventricular Tachycardia and Heart Blocks. The monitor also simulates synchronized pulses with ECG for truly realistic cardiology training.

ECG Patterns

- Sinus Rhythm
- Atrial Extrasystole
- Atrial Flutter
- Atrial Fibrillation
- Paroxysmal Supraventricular Tachycardia (PSVT)
- Ventricular Extrasystole
- Ventricular Tachycardia (VT)
- Ventricular Fibrillation (VF)
- First-Degree Atrioventricular Block (AVB)
- Second-Degree Atrioventricular Block
- Third-Degree Atrioventricular Block (Complete Block)
- Long QT Syndrome
- ST Segment Elevation
- ST Segment Depression
- T Wave Inversion
- Left Ventricular Hypertrophy (LVH)
- Right Ventricular Hypertrophy (RVH)



- Wolff-Parkinson-White Syndrome (WPW)

Breathing Patterns

- Normal
- Dyspnea
- Apnea
- Cheyne-Stokes
- Biot
- Kussmaul

About Anatomical Models:

They are developed with resin replication technology, addressing the scarcity of natural anatomical pieces for teaching and research. They present all the essential morphological characteristics with excellent cost-benefit, resistance, manual painting, and numbering for precise identification of structures.

List of all visible structures:

- cecum
- ileum
- intestine
- jejunum
- transverse colon
- descending colon
- ascending colon
- internal oblique muscle
- transversus abdominis muscle
- pyloric antrum
- round ligament of the liver