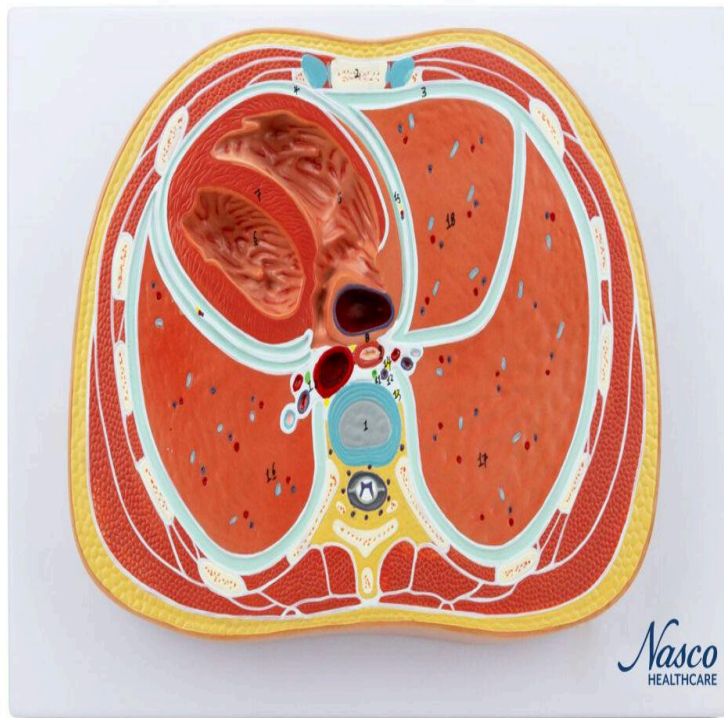
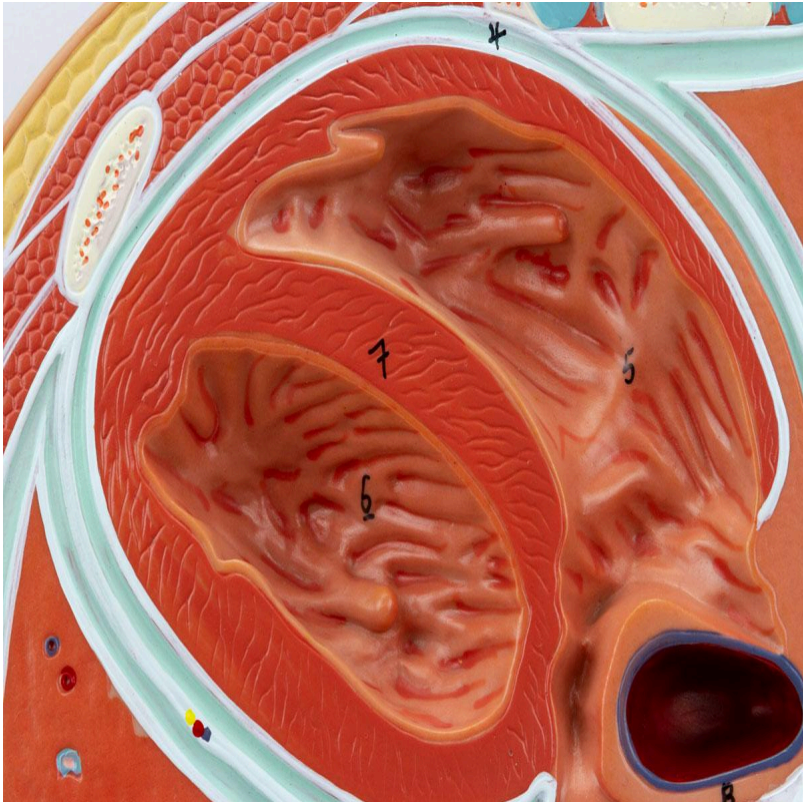
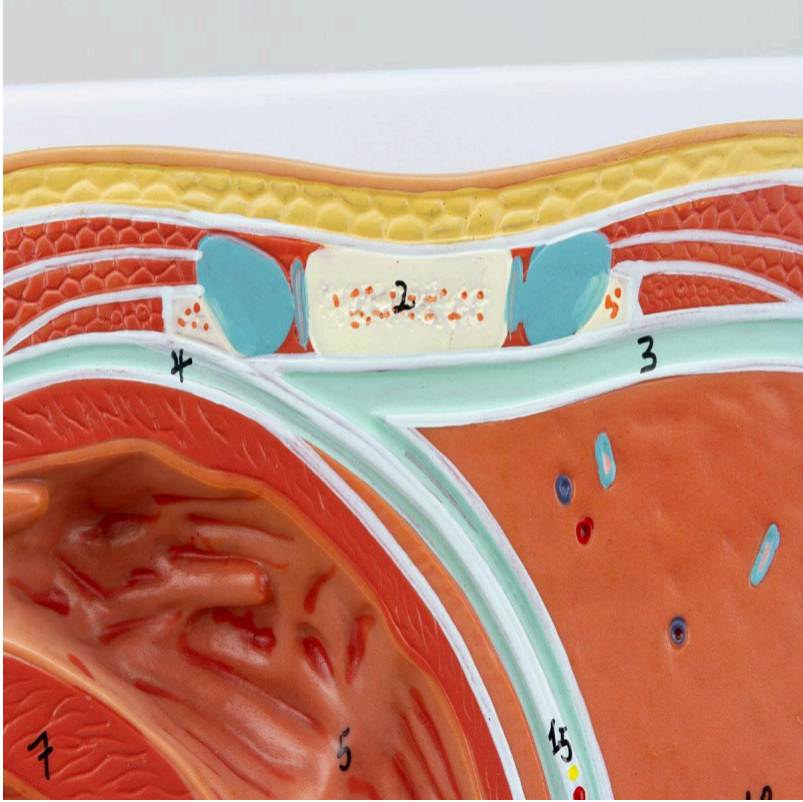
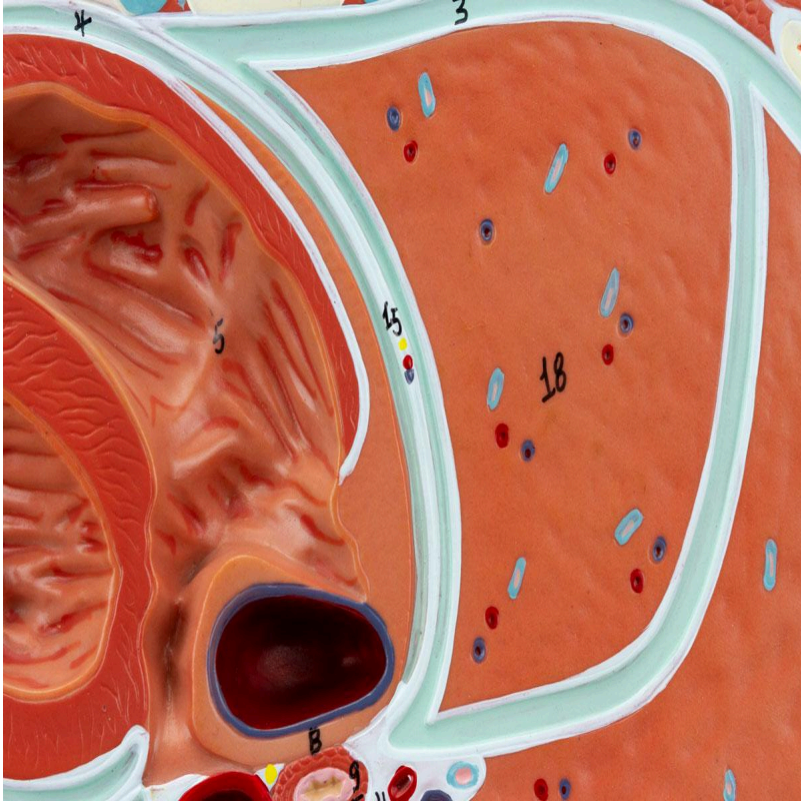
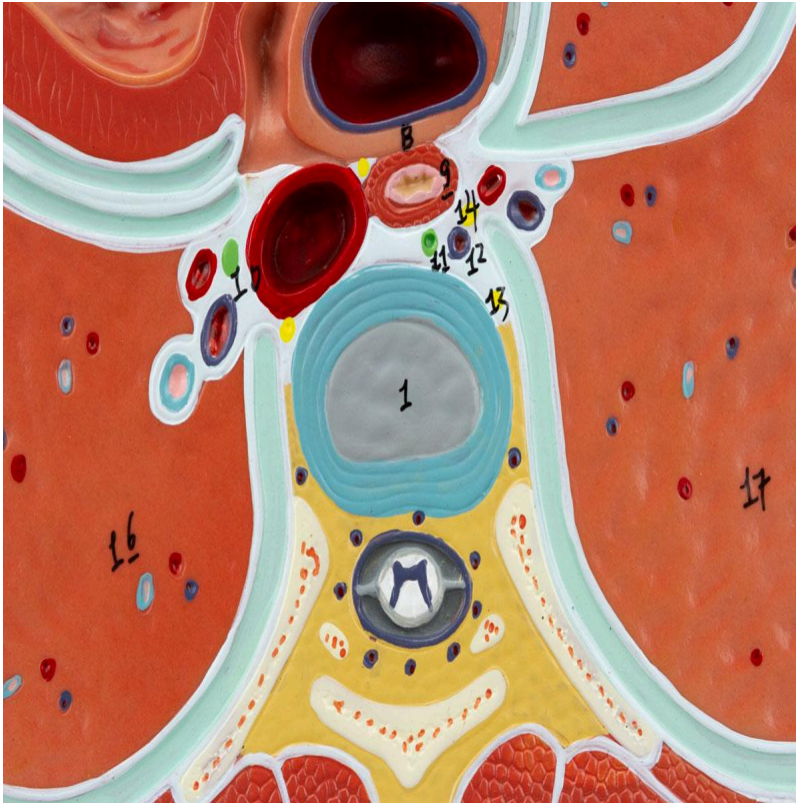


MG31113 | CROSS SECTION OF TORAX









Life-size model featuring an axial (cross-sectional) view of the thorax at the level of the T6 vertebra, allowing visualization of the heart, lungs, veins, arteries, and other thoracic structures in a horizontal section.

Applications:

Ideal for studying thoracic anatomy, allowing detailed observation of the internal structures of the thorax, including the heart, lungs, blood vessels, and other relevant structures. Support tool for learning and continuing education in anatomy, physiology, and pathophysiology.

Technical Differentiators:

- * Detailed representation of the anatomical structures of the thorax.
- * Life-size model for better visualization and understanding.
- * Horizontal section for studying sectional anatomy.

3D Technology and Augmented Reality:

Our anatomical models offer an innovative visual complement through informative cards that activate 3D models viewable in augmented reality (AR). This exclusive interactive platform stimulates learning, allowing comparative analysis of anatomical structures and offering opportunities for continuing education in anatomy, physiology, and pathophysiology.

Technical Specifications:



* Scale: Life-size

* Material: Resin

Main Structures:

1. Thoracic Vertebra (T8): Located in the middle back region, the T8 thoracic vertebra is one of the twelve vertebrae that form the thoracic spine. It articulates with the ribs, protecting vital organs and allowing trunk flexibility.

2. Body of the Sternum: The main and central portion of the sternum, the body of the sternum is a flat bone that articulates with the ribs through the costal cartilages. It provides protection to the anterior part of the thorax and serves as an attachment point for important muscles.

3. Pleural Cavity: The space between the parietal and visceral pleurae, which surround each lung. The pleural cavity contains a small amount of pleural fluid, which facilitates the sliding of the lungs during breathing and maintains negative intrapleural pressure, essential for lung expansion.

4. Pericardial Cavity: The space between the layers of the pericardium (membrane that surrounds the heart), containing a small amount of pericardial fluid. This fluid reduces friction between the heart and adjacent structures during heartbeats.

5. Right Atrium: One of the four chambers of the heart, the right atrium receives venous blood (poor in oxygen) from the body through the superior and inferior vena cavae. It contracts to propel blood into the right ventricle.

6. Left Ventricle: The most powerful cardiac chamber, the left ventricle receives oxygenated blood from the left atrium and pumps it into the aorta, which distributes blood throughout the body. Its vigorous contraction ensures systemic circulation.

7. Interventricular Septum: The wall that separates the right and left ventricles of the heart. The interventricular septum is essential for preventing the mixing of oxygenated and deoxygenated blood, ensuring the efficiency of blood circulation.

8. Inferior Vena Cava: A large vein that carries deoxygenated blood from the lower part of the body (lower limbs, abdomen, and pelvis) back to the right atrium of the heart. It is an essential blood vessel for venous return.

9. Esophagus: A muscular tube that transports food from the pharynx to the stomach. It passes through the thorax and abdomen, propelling the food bolus through peristaltic contractions.



10. Thoracic Aorta (Descending): The continuation of the aorta after the aortic arch, descending through the thorax and providing branches to the thoracic structures. It carries oxygenated blood from the heart to the lower part of the body.

11. Thoracic Duct: The largest lymphatic vessel in the body, responsible for collecting lymph from most of the body (except the upper right quadrant) and draining it into the venous system, near the junction of the left internal jugular and left subclavian veins.

12. Azygos Vein: A vein that runs along the right side of the vertebral column and drains blood from the thoracic and abdominal walls into the superior vena cava. It serves as an alternative route of venous drainage.

13. Right Sympathetic Trunk: A chain of nerve ganglia that is part of the sympathetic nervous system, responsible for regulating various automatic functions of the body, such as heart rate, blood pressure, and sweating.

14. Right Greater Splanchnic Nerve: A nerve that originates from the thoracic sympathetic trunk and projects to the abdomen, where it innervates visceral organs, such as the stomach, liver, and pancreas, regulating their functions.

15. Right Phrenic Nerve and Pericardiophrenic Artery and Vein: The right phrenic nerve innervates the diaphragm, the main muscle of respiration, and the pericardiophrenic artery and vein accompany it, irrigating and draining the pericardium.

16. Lower Lobe of the Left Lung: The lower portion of the left lung, responsible for a significant part of gas exchange. Its anatomy is adapted to maximize the surface area of contact with blood capillaries.

17. Lower Lobe of the Right Lung: The lower portion of the right lung, responsible for a significant part of gas exchange. Its anatomy is adapted to maximize the surface area of contact with blood capillaries.

18. Middle Lobe of the Right Lung: Present only in the right lung, the middle lobe is one of the three main divisions. It contributes to gas exchange and has a unique anatomy compared to the other lobes.

Other structures can be verified directly on the physical piece or in the interactive 3D model.

Customizable Skin Tones:

This anatomical model offers the option of choosing between three skin tones to better represent human diversity and meet different educational and clinical needs. You can choose between light skin, intermediate tone, and dark skin, providing greater realism and inclusion during training and demonstrations.



About Anatomical Models:

They are developed with resin replication technology, addressing the shortage of natural anatomical pieces for teaching and research. They present all the essential morphological characteristics with excellent cost-benefit, resistance, manual painting, and numbering for precise identification of structures.

List of all visible structures:

- 1. Thoracic Vertebrae (T8)
- 2. Body of Sternum
- 3. Pleural Cavity
- 4. Pericardial Cavity
- 5. Right Atrium
- 6. Left Ventricle
- 7. Interventricular Septum
- 8. Inferior Vena Cava
- 9. Esophagus
- 10. Thoracic Aorta (Descending)
- 11. Thoracic Duct
- 12. Azygos Vein
- 13. Right Sympathetic Trunk
- 14. Right Greater Splanchnic Nerve
- 15. Right Phrenic Nerve and Pericardiophrenic Artery and Vein
- 16. Inferior Lobe of Left Lung
- 17. Inferior Lobe of Right Lung
- 18. Middle Lobe of Right Lung