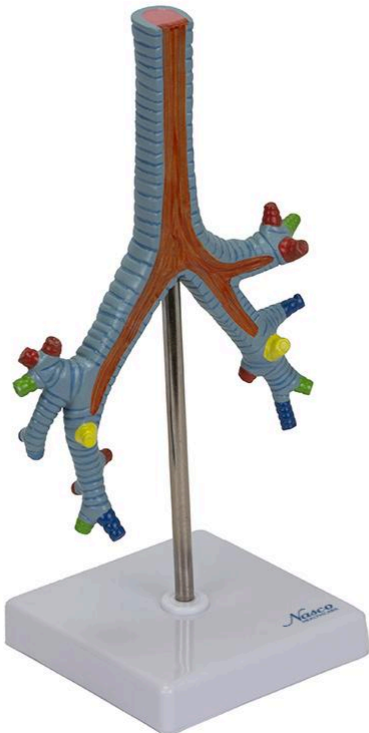
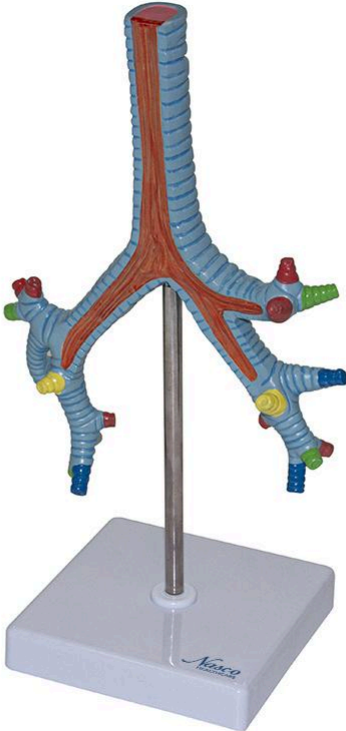




## MG29764 | BRONCHICAL TREE



*Nasco*  
HEALTHCARE





Life-size Bronchial Tree Model, showing the bifurcation of the trachea and its subdivisions down to the bronchopulmonary segments. Structures are numbered, and segments and subdivisions are indicated in didactic colors for easier understanding. The model is mounted on a polymer base with a metal support and rod, and includes an information card with related structures.

**Applications:**

Ideal for anatomy studies in schools and universities; indicated for training, medical and scientific information.

**Technical Characteristics:**

- \* High didactic level;
- \* Numbered and hand-painted;
- \* Precise details for better learning;
- \* High-quality natural molding;
- \* Made of resistant synthetic material;
- \* Precise replicas;
- \* Includes an information card with related structures;
- \* Resin approved in toxicological tests;
- \* Comes with references and markings.

**3D Technology and Augmented Reality:**

Our anatomical models offer a visual complement through information cards that activate 3D models viewable in augmented reality (AR). This interactive platform assists learning, allowing for comparative analysis of anatomical structures and offering resources for continuing education in anatomy, physiology, and pathophysiology.

**Technical Specifications:**

- \* Scale: Life-size
- \* Material: Synthetic resin

**Main Structures:**

**intercartilaginous ligaments:** These are fibrous structures that connect the tracheal cartilages, providing flexibility and stability to the trachea.

**excised connective tissue lining:** The connective tissue, excised in the model, represents the adventitia that surrounds the bronchial tree, providing support and connecting it to adjacent tissues.



**mucosa:** The bronchial mucosa is the inner lining of the bronchi, composed of pseudostratified ciliated columnar epithelium and lamina propria, which plays important roles in humidifying and cleaning the inspired air.

**left main bronchus:** One of the two main bronchi, originating from the bifurcation of the trachea and entering the left lung, subsequently branching into lobar bronchi.

**left secondary bronchi:** These are the lobar bronchi that originate from the left main bronchus, one for the superior lobe and another for the inferior lobe of the left lung.

**tracheal bifurcation:** This is the point where the trachea divides into two main bronchi, right and left, marking the beginning of the bronchial tree.

**tertiary or segmental bronchi:** These are branches of the secondary bronchi, each supplying a specific bronchopulmonary segment.

**Bronchioles:** These are small terminal branches of the bronchial tree, conducting air to the pulmonary alveoli. Their wall is thinner than that of the bronchi, without cartilage.

**eparterial bronchus:** Refers to the branch of the right superior lobar bronchus that passes superiorly to the pulmonary artery.

**right secondary bronchi:** These are the lobar bronchi that originate from the right main bronchus, one for the superior lobe, one for the middle lobe, and one for the inferior lobe of the right lung.

Other structures can be verified directly on the physical piece or on the interactive 3D model.

#### **About the Anatomical Models:**

Developed with resin replication technology, supplying the scarcity of natural anatomical pieces for teaching and research. They present the essential morphological characteristics with excellent cost-benefit, good resistance, hand painting, and numbering for precise identification of structures.

Request information and a demonstration of our anatomical model and provide an innovative and interactive learning experience at your institution. Contact us to

#### **List of all visible structures:**

- intercartilaginous ligaments
- sheath of the cut connective tissue
- mucosa



- left main bronchus
- left secondary bronchi
- tracheal bifurcation
- tertiary or segmental bronchi
- Bronchioles
- eparterial bronchus
- right secondary bronchi
- tertiary or segmental bronchi
- bronchioles
- right main bronchus