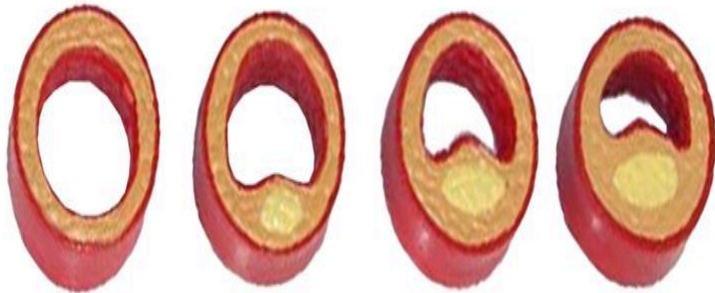
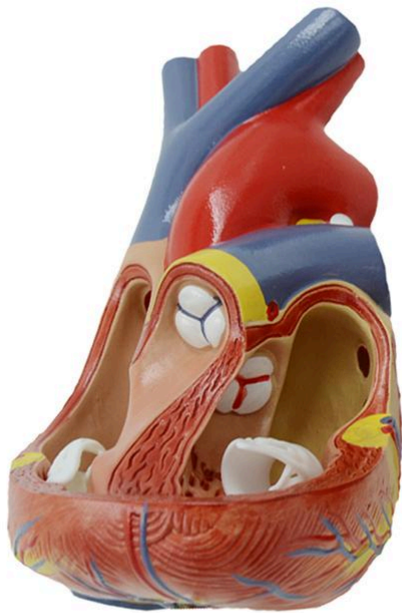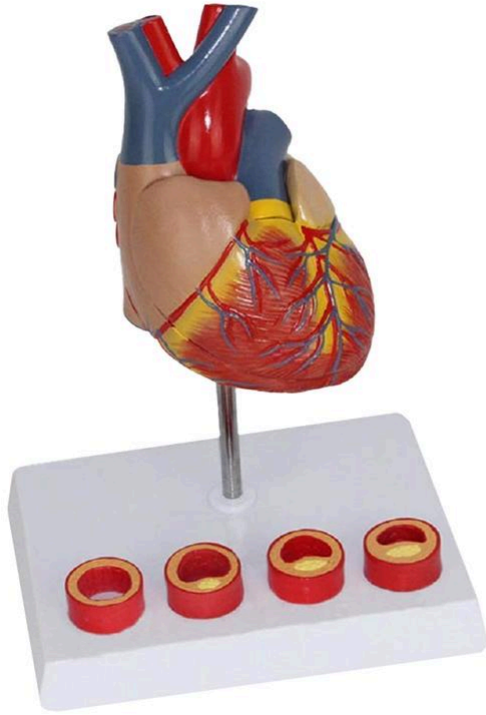




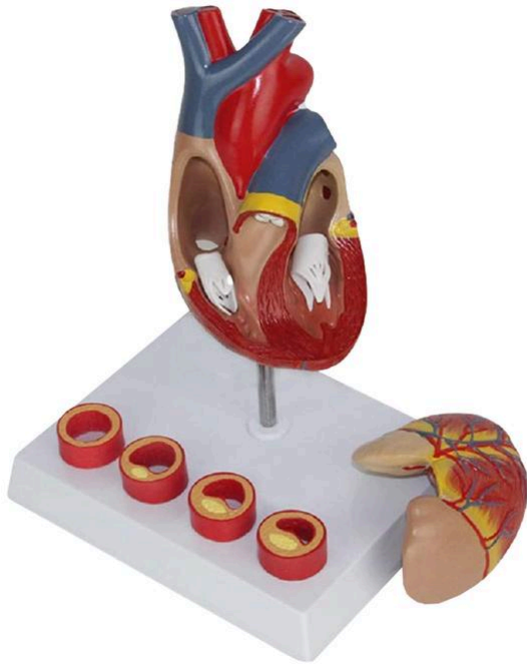MG35530 | HEART WITH CROSS SECTION OF ARTERIOSCLEROSIS ARTERY, 2 PARTS



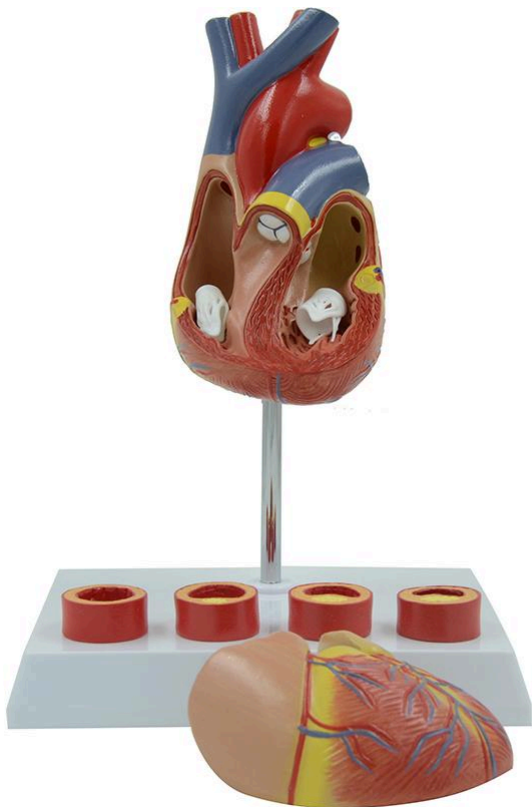
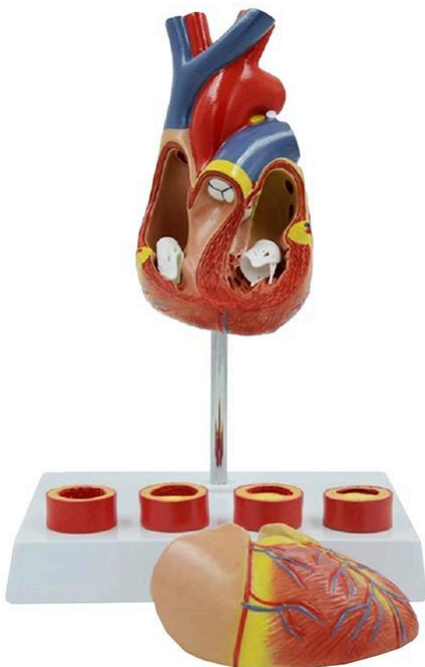Nasco
HEALTHCARE



Nasco
HEALTHCARE



Nasco
HEALTHCARE





Life-size anatomical model of the heart, ideal for studying the stages of the vascular atherosclerosis process and other cardiovascular events. Comes with an interactive 3D anatomical model with augmented reality for a complete and interactive learning experience.

Applications:

Ideal for studying the heart, the stages of vascular atherosclerosis, and for comparative analysis of anatomical models. Used for continuing education in anatomy, physiology, and pathophysiology.

Technical Differentiators:

Detailed representation of cardiovascular events related to atherosclerosis. Interactive 3D model with augmented reality for in-depth visualization.

3D Technology and Augmented Reality:

Our anatomical models offer an innovative visual complement through informative cards that activate 3D models viewable in augmented reality (AR). This exclusive interactive platform stimulates learning, allowing comparative analysis of anatomical structures and offering opportunities for continuing education in anatomy, physiology, and pathophysiology.

Technical Specifications:

* Scale: Life-size

Main Structures:

left subclavian artery: The left subclavian artery is an important blood vessel that originates from the aortic arch. It supplies blood to the left arm, neck, and part of the brain. After passing through the first rib, it becomes the axillary artery.

left common carotid artery: The left common carotid artery is a major blood vessel that originates directly from the aortic arch. It supplies oxygenated blood to the left side of the head and neck. At the level of the thyroid cartilage, it divides into the internal and external carotid arteries.

brachiocephalic trunk: The brachiocephalic trunk is the largest artery that originates from the aortic arch. It divides into two main arteries: the right subclavian artery and the right common carotid artery, supplying blood to the right arm and the right side of the head and neck.

aortic arch: The aortic arch is the continuation of the ascending aorta and curves over the heart. Three major vessels originate from it: the brachiocephalic trunk, the left common carotid artery, and the left subclavian artery, which supply the upper part of the body.



left pulmonary artery: The left pulmonary artery carries deoxygenated blood from the right ventricle of the heart to the left lung, where gas exchange occurs. It is a branch of the main pulmonary artery.

ligamentum arteriosum: The ligamentum arteriosum is a fibrous remnant of the ductus arteriosus, a fetal structure that allowed blood to bypass the non-functional lungs to the aorta. It connects the left pulmonary artery to the descending aorta.

left auricle: The left auricle is a pouch-like extension of the left atrium of the heart. Its main function is to increase the capacity of the left atrium, allowing it to receive more blood from the lungs through the pulmonary veins.

great cardiac vein: The great cardiac vein is the largest vein of the heart. It runs along the anterior interventricular groove and collects deoxygenated blood from the left ventricle and the left atrium, draining it into the coronary sinus.

left ventricle: The left ventricle is one of the four chambers of the heart and is responsible for pumping oxygenated blood into the aorta, which distributes it throughout the body. It has thicker walls than the right ventricle due to the higher pressure required for systemic circulation.

anterior interventricular artery: The anterior interventricular artery, also known as the left anterior descending (LAD) artery, is a branch of the left coronary artery. It runs along the anterior interventricular groove and supplies blood to the anterior wall of the left ventricle and the interventricular septum.

Other structures can be verified directly on the physical piece or in the interactive 3D model.

Smart Tags:

Designed to provide comprehensive training in the healthcare field, with interactive simulations covering Heart exams. This solution assists in the development of diagnostic skills in different clinical scenarios, allowing professionals and students to explore and improve their skills with greater safety and accuracy.

Heart sound recognition: Recognize 23 unique heart sounds with different patient postures and tools.

- Apex, Normal S1 S2, Supine, Bell
- Apex, Split S1, Supine, Bell
- Apex, S4, LLD, Bell
- Apex, Mid Systolic Click, Supine, Bell
- Apex, S3, LLD, Bell
- Apex, Early Systolic Murmur, Supine, Bell
- Apex, Mid Systolic Murmur, Supine, Bell



- Apex, Late Systolic Murmur, Supine, Bell
- Apex, Holosystolic Murmur, Supine, Bell
- Apex, Systolic Click & Late Systolic Murmur, LLD, Bell
- Apex, S4 & Mid Systolic Murmur, LLD, Bell
- Apex, S3 & Holosystolic Murmur, LLD, Bell
- Apex, OS & Diastolic Murmur, LLD, Bell
- Aortic, Normal S1 S2, Sitting, Bell
- Aortic, Systolic Murmur & Absent S2, Sitting, Bell
- Aortic, Early Diastolic Murmur, Sitting, Bell
- Aortic, Systolic & Diastolic Murmur, Sitting, Bell
- Pulmonary, Single S2, Supine, Diaphragm
- Pulmonary, Split S2 Persistent, Supine, Diaphragm
- Pulmonary, Split S2 Transient, Supine, Diaphragm
- Pulmonary, Ejection Systolic Murmur & Transient Split S2, Supine, Diaphragm
- Pulmonary, Split S2 & Ejection Systolic Murmur, Supine, Diaphragm
- Pulmonary, Ejection Systolic Murmur & Single S2 & Ejection Click, Supine, Diaphragm

Virtual Patient Monitor: Provides an immersive and realistic training environment for healthcare students. It allows instructors to customize parameters for various vital signs, empowering students to interpret signals, develop critical thinking, and enhance their clinical reasoning skills through realistic scenarios.

Customizable Vital Signs

- Blood Pressure
- SpO2
- Heart Rate

ECG Interpretation: Train on 18 diverse ECG scenarios, including: Atrial Fibrillation, Ventricular Tachycardia and Heart Blocks. The monitor also simulates synchronized pulses with ECG for truly realistic cardiology training.

ECG Patterns

- Sinus Rhythm
- Atrial Extrasystole
- Atrial Flutter
- Atrial Fibrillation
- Paroxysmal Supraventricular Tachycardia (PSVT)
- Ventricular Extrasystole
- Ventricular Tachycardia (VT)
- Ventricular Fibrillation (VF)
- First-Degree Atrioventricular Block (AVB)
- Second-Degree Atrioventricular Block
- Third-Degree Atrioventricular Block (Complete Block)
- Long QT Syndrome



- ST Segment Elevation
- ST Segment Depression
- T Wave Inversion
- Left Ventricular Hypertrophy (LVH)
- Right Ventricular Hypertrophy (RVH)
- Wolff-Parkinson-White Syndrome (WPW)

Breathing Patterns

- Normal
- Dyspnea
- Apnea
- Cheyne-Stokes
- Biot
- Kussmaul

About the Anatomical Models:

They are developed with resin replication technology, addressing the scarcity of natural anatomical pieces for teaching and research. They present all the essential morphological characteristics with excellent cost-benefit, resistance, manual painting, and numbering for precise identification of structures.

List of all visible structures:

- left subclavian artery
- left common carotid artery
- brachiocephalic trunk
- aortic arch
- left pulmonary artery
- ligamentum arteriosum
- left auricle
- great cardiac vein
- left ventricle
- anterior interventricular artery
- cardiac muscle
- right ventricle
- right coronary artery
- right auricle
- superior vena cava
- ascending aorta
- pulmonary trunk
- normal artery



- fatty streak
- atheroma
- arterial blockage