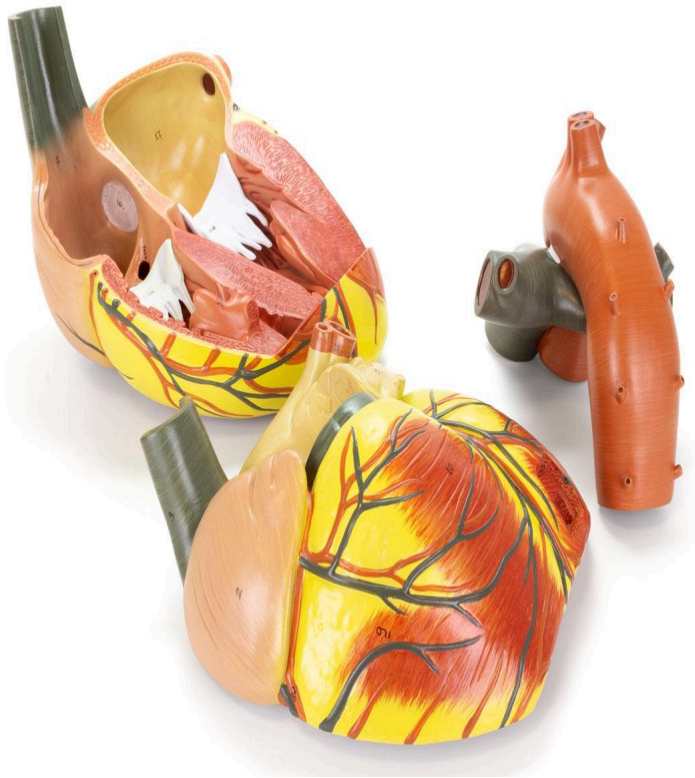
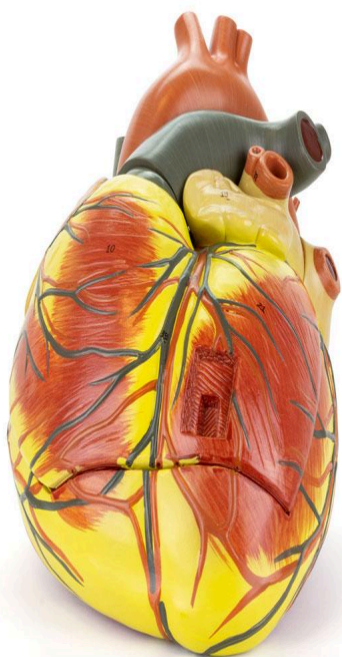


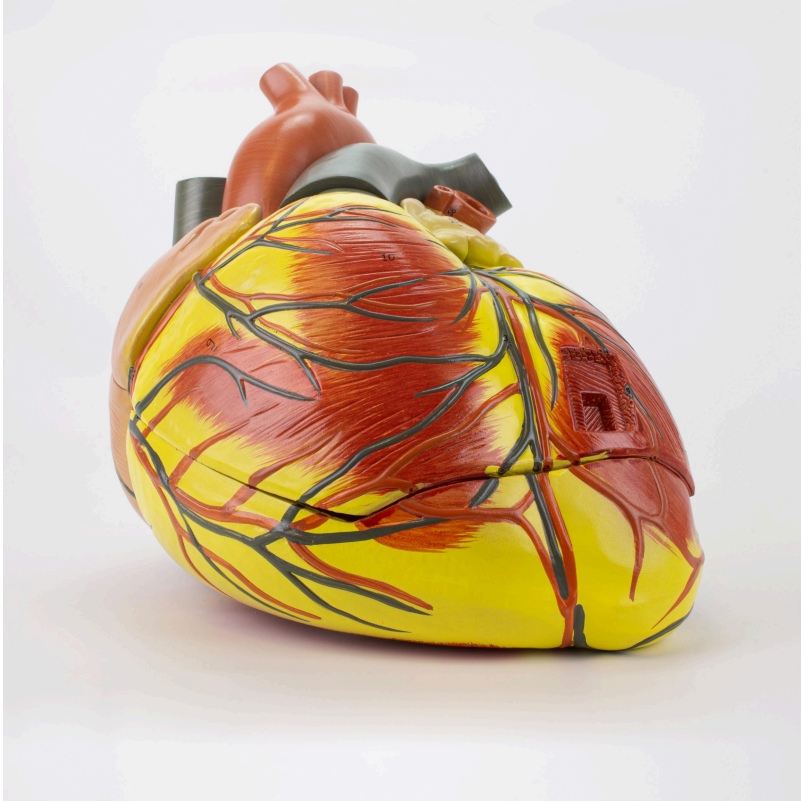

**MG22272 | HUMAN HEART 3 TIMES  
ENLARGED, 3 PARTS**

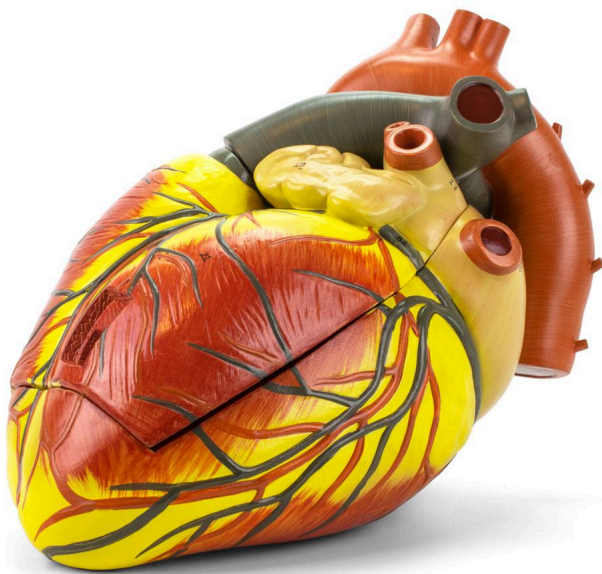
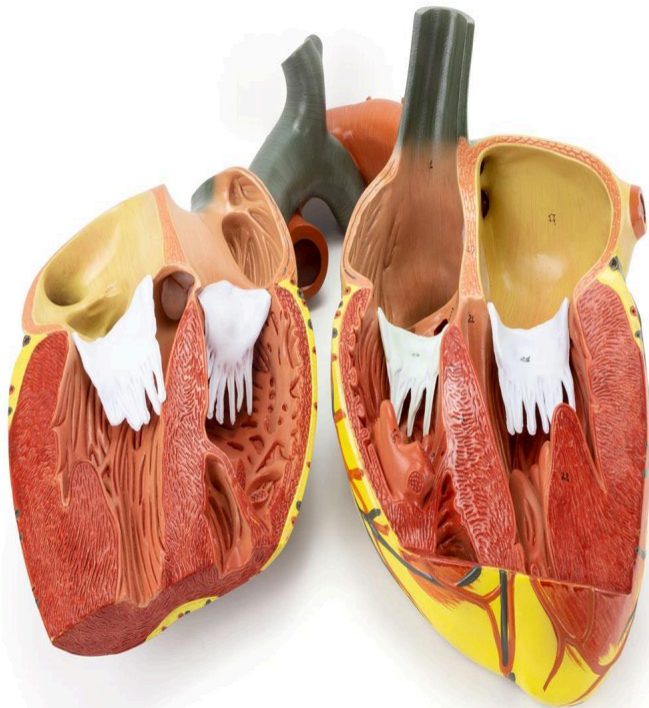


*Nasco*  
HEALTHCARE





*Nasco*  
HEALTHCARE







Anatomical heart model in 3 parts, magnified 3 times natural size and sectioned in the anterior plane for detailed visualization of the internal structure, including heart valves and the comparative morphology of the ventricles. The right atrium is removable, allowing for further study.

**Applications:**

Ideal for the study of cardiac anatomy, training of healthcare professionals, and as a learning support tool in anatomy, physiology, and pathophysiology.

**Technical Differentiators:**

- \* 3x magnification for better visualization.
- \* Sectioned in the anterior plane for exposure of the internal structure.
- \* Removable right atrium for detailed study.
- \* Hand-assembled.
- \* Durable synthetic material.

**3D Technology and Augmented Reality:**

Our anatomical models offer an innovative visual complement through information cards that activate 3D models viewable in augmented reality (A.R.). This exclusive interactive platform stimulates learning, allowing comparative analysis of anatomical structures and offering opportunities for continuing education in anatomy, physiology, and pathophysiology.

**Technical Specifications:**

- \* Scale: 3 times natural size
- \* Material: Durable synthetic
- \* Number of parts: 3

**Main Structures:**

**pulmonary trunk:** The pulmonary trunk is a large artery that originates from the right ventricle of the heart and divides into the right and left pulmonary arteries, responsible for carrying deoxygenated blood to the lungs for gas exchange.

**right atrium:** The right atrium is one of the four chambers of the heart, receiving deoxygenated blood from the superior and inferior vena cava, as well as the coronary sinus. It pumps blood into the right ventricle through the tricuspid valve.

**aorta:** The aorta is the largest artery in the human body, originating from the left ventricle of the heart. It transports oxygenated blood to the systemic circulation, irrigating all organs and tissues of the body.

**right coronary artery:** The right coronary artery is a blood vessel that originates from the ascending aorta and irrigates the right side of the heart, including the right atrium, right ventricle, and part of the left ventricle, as well as the sinoatrial and atrioventricular node in many individuals.

**pulmonary vein:** The pulmonary veins are blood vessels that carry oxygenated blood from the lungs back to the left atrium of the heart. There are typically four pulmonary veins: two from the right lung and two from the left lung.

**left pulmonary artery:** The left pulmonary artery is a branch of the pulmonary trunk that carries deoxygenated blood from the right ventricle of the heart to the left lung, where gas exchange occurs.

**ligamentum arteriosum:** The ligamentum arteriosum is a fibrous remnant of the ductus arteriosus, a fetal structure that connects the pulmonary artery to the aorta. After birth, the ductus arteriosus closes and becomes the ligamentum arteriosum.

**left atrium:** The left atrium is one of the four chambers of the heart, receiving oxygenated blood from the pulmonary veins. It pumps blood into the left ventricle through the mitral valve.

**left coronary artery:** The left coronary artery is a blood vessel that originates from the ascending aorta and irrigates the left side of the heart, including the left atrium, the left



ventricle, and part of the right ventricle.

**circumflex branch:** The circumflex branch is one of the two main branches of the left coronary artery. It circles the heart in the coronary sulcus, irrigating the left atrium and the posterior part of the left ventricle.

Other structures can be verified directly on the physical piece or in the interactive 3D model.

### **Smart Tags:**

Designed to provide comprehensive training in the healthcare field, with interactive simulations covering Heart exams. This solution assists in developing diagnostic skills in different clinical scenarios, allowing professionals and students to explore and enhance their skills with greater safety and accuracy.

**Heart sound recognition:** Recognize 23 unique heart sounds with different patient postures and tools.

- Apex, Normal S1 S2, Supine, Bell
- Apex, Split S1, Supine, Bell
- Apex, S4, LLD, Bell
- Apex, Mid Systolic Click, Supine, Bell
- Apex, S3, LLD, Bell
- Apex, Early Systolic Murmur, Supine, Bell
- Apex, Mid Systolic Murmur, Supine, Bell
- Apex, Late Systolic Murmur, Supine, Bell
- Apex, Holosystolic Murmur, Supine, Bell
- Apex, Systolic Click & Late Systolic Murmur, LLD, Bell
- Apex, S4 & Mid Systolic Murmur, LLD, Bell
- Apex, S3 & Holosystolic Murmur, LLD, Bell
- Apex, OS & Diastolic Murmur, LLD, Bell
- Aortic, Normal S1 S2, Sitting, Bell
- Aortic, Systolic Murmur & Absent S2, Sitting, Bell
- Aortic, Early Diastolic Murmur, Sitting, Bell
- Aortic, Systolic & Diastolic Murmur, Sitting, Bell
- Pulmonary, Single S2, Supine, Diaphragm
- Pulmonary, Split S2 Persistent, Supine, Diaphragm
- Pulmonary, Split S2 Transient, Supine, Diaphragm
- Pulmonary, Ejection Systolic Murmur & Transient Split S2, Supine, Diaphragm
- Pulmonary, Split S2 & Ejection Systolic Murmur, Supine, Diaphragm
- Pulmonary, Ejection Systolic Murmur & Single S2 & Ejection Click, Supine, Diaphragm

**Virtual Patient Monitor:** Provides an immersive and realistic training environment for healthcare students. It allows instructors to customize parameters for various vital signs, empowering students to interpret signals, develop critical thinking, and enhance their clinical



reasoning skills through realistic scenarios.

### **Customizable Vital Signs**

- Blood Pressure
- SpO2
- Heart Rate

**ECG Interpretation:** Train on 18 diverse ECG scenarios, including: Atrial Fibrillation, Ventricular Tachycardia and Heart Blocks. The monitor also simulates synchronized pulses with ECG for truly realistic cardiology training.

### **ECG Patterns**

- Sinus Rhythm
- Atrial Extrasystole
- Atrial Flutter
- Atrial Fibrillation
- Paroxysmal Supraventricular Tachycardia (PSVT)
- Ventricular Extrasystole
- Ventricular Tachycardia (VT)
- Ventricular Fibrillation (VF)
- First-Degree Atrioventricular Block (AVB)
- Second-Degree Atrioventricular Block
- Third-Degree Atrioventricular Block (Complete Block)
- Long QT Syndrome
- ST Segment Elevation
- ST Segment Depression
- T Wave Inversion
- Left Ventricular Hypertrophy (LVH)
- Right Ventricular Hypertrophy (RVH)
- Wolff-Parkinson-White Syndrome (WPW)

### **Breathing Patterns**

- Normal
- Dyspnea
- Apnea
- Cheyne-Stokes
- Biot
- Kussmaul

### **About Anatomical Models:**

They are developed with resin replication technology, addressing the shortage of natural anatomical pieces for teaching and research. They present all the essential morphological



characteristics with excellent cost-benefit, resistance, manual painting, and numbering for precise identification of structures.

**List of all visible structures:**

- pulmonary trunk
- right atrium
- aorta
- right coronary artery
- right atrium
- pulmonary vein
- left pulmonary artery
- ligamentum arteriosum
- pulmonary vein
- left atrium
- left coronary artery
- circumflex branch
- left ventricle
- conus arteriosus
- right ventricle
- right marginal branch
- inferior vena cava
- coronary sinus
- anterior interventricular branch
- right pulmonary artery
- posterior interventricular branch
- small cardiac vein
- middle cardiac vein
- great cardiac vein