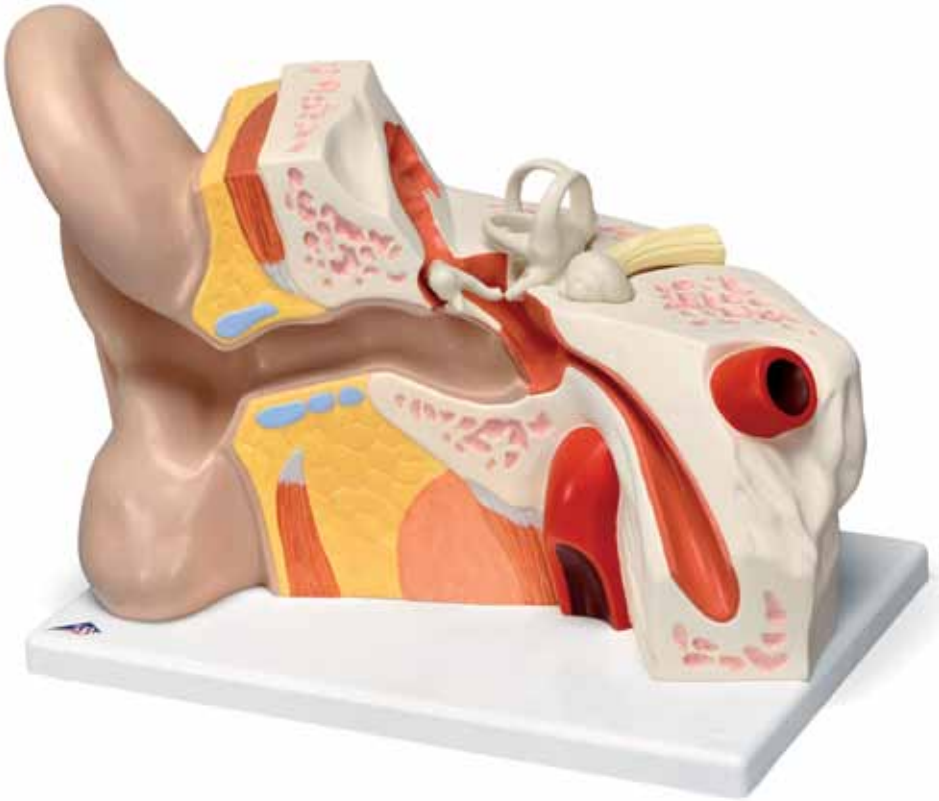




...going one step further



VJ513

(1008553)

Organ of hearing

English

A External Ear

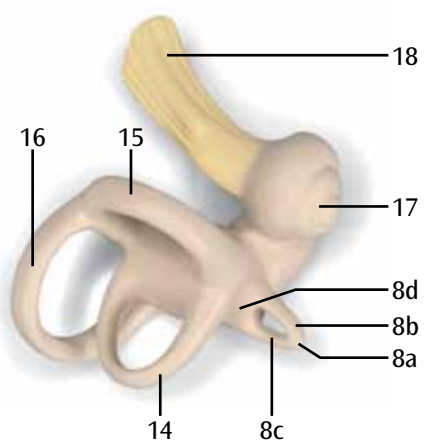
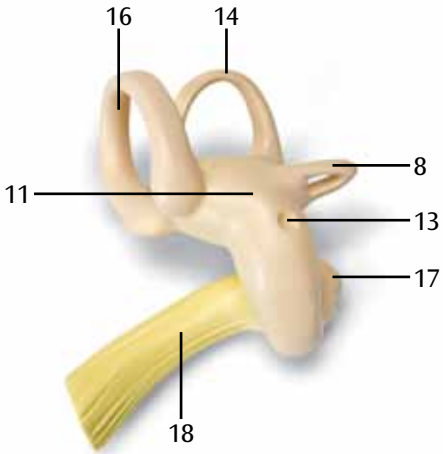
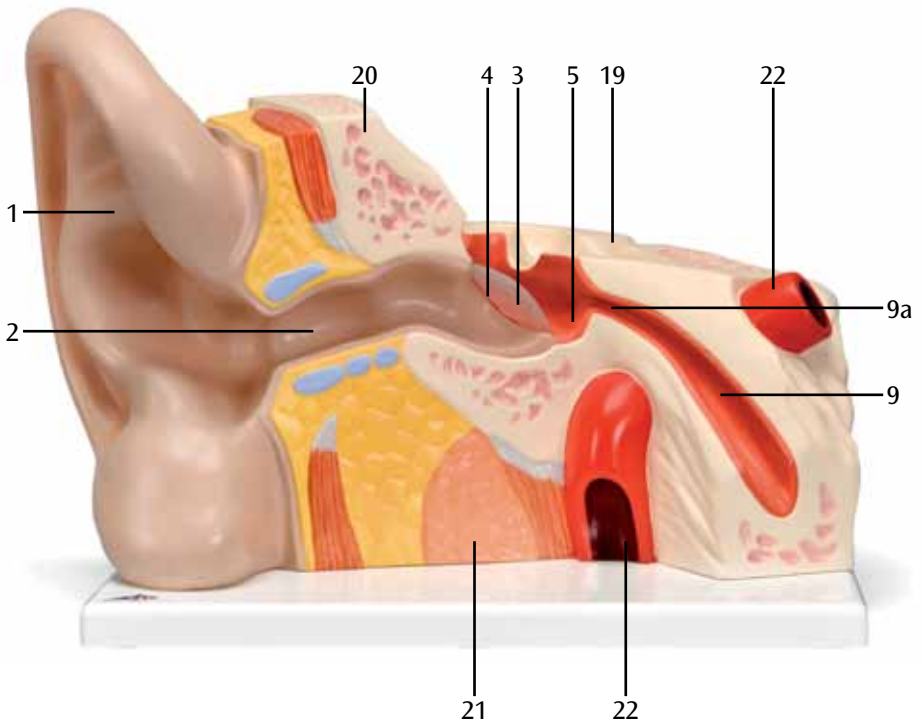
- 1 Auricle
- 2 External acoustic meatus
- 3 Tympanic membrane
- 4 Fibrocartilaginous ring

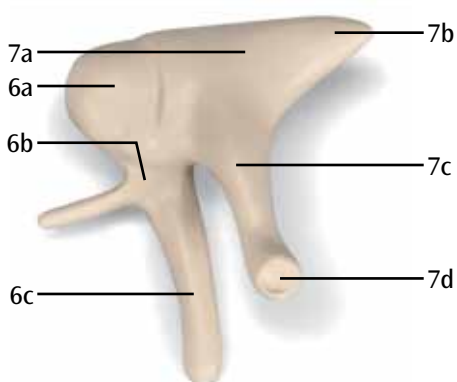
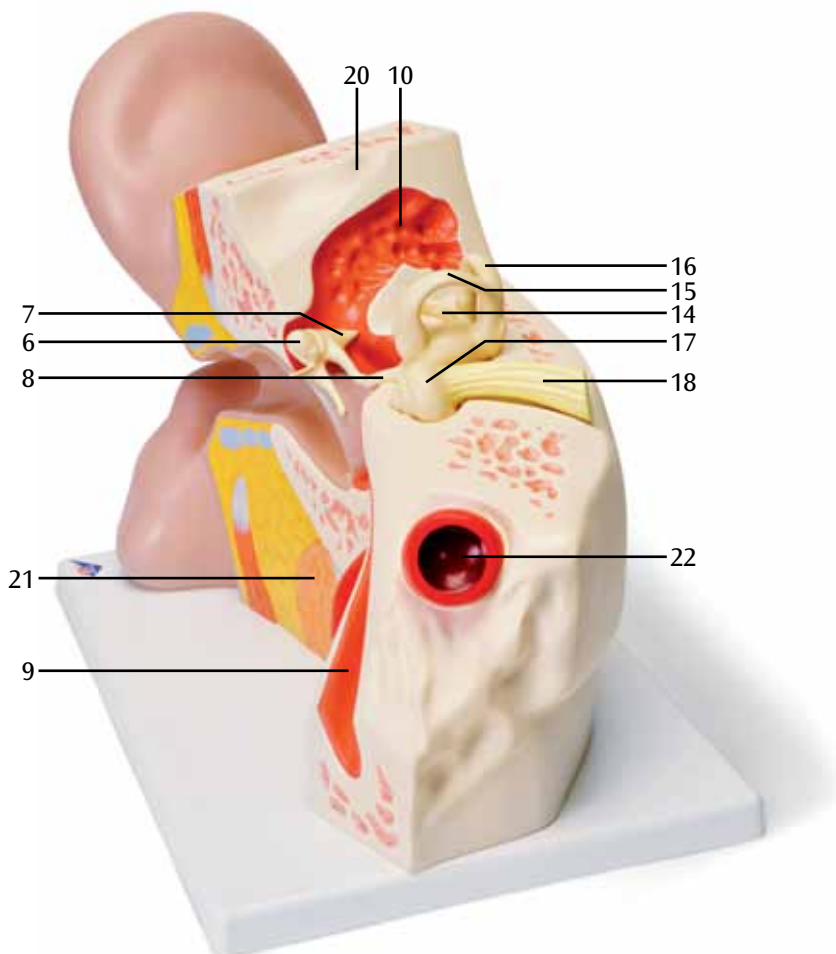
B Middle Ear

- 5 Tympanic cavity
- 6 Malleus
 - a Head of malleus
 - b Neck of malleus
 - c Handle of malleus
- 7 Incus
 - a Body of incus
 - b Short limb
 - c Long limb
 - d Lenticular process
- 8 Stapes
 - a Head of stapes
 - b Anterior limb
 - c Posterior limb
 - d Base of stapes
- 9 Pharyngotympanic tube
 - a Tympanic opening
- 10 Epitympanic recess

C Internal Ear

- 11 Vestibule
- 12 Oval window
- 13 Round window
- 14 Lateral semicircular canal
- 15 Anterior semicircular canal
- 16 Posterior semicircular canal
- 17 Cochlea
- 18 Vestibulocochlear nerve [VIII]
- 19 Internal acoustic meatus
- 20 Temporale bone
- 21 Parotid gland
- 22 Internal carotid artery





3B Scientific



© Copyright 2011 / 2012 for instruction manual and design of product:
3B Scientific GmbH, Germany