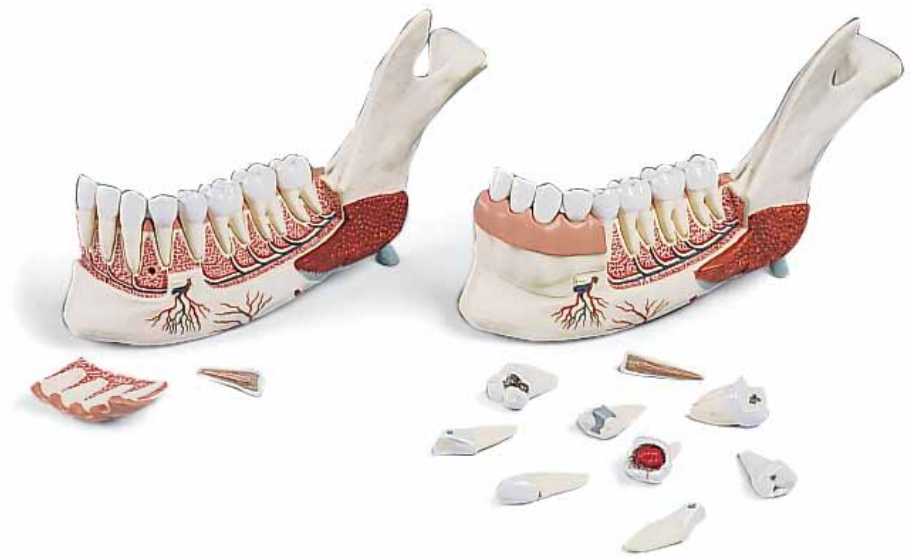



...going one step further



VE287

VE290

(1001249/1001250)

VE287/VE290

English

(1001249/1001250)

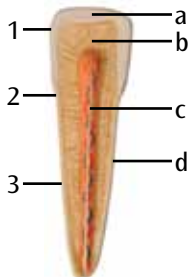
Half of the mandible about tri pie natural size, 11 parts. One part of the anterior bone wall including marginal gingiva may be taken off. Every tooth may be taken out of the alveoli. In addition around incisor tooth in longitudinal section is also delivered. Only VE290: with extra set of bad teeth

- 1 Condylloid process
- 2 Coronoid process of mandible
- 3 Ramus of the mandible
- 4 Mandibular angle
- 5 Mental tubercle
- 6 Mandible protuberance
- 7 Body of the mandible
- 8 Gum
- 9 Medius pterygoid muscle
- 10 Mylohyoid muscle
- 11 Digastric muscle
- 12 Masseter
- 13 Sublingual gland
- 14 Submandibular gland
- 15 Inferior dental nerve
- 16 Lingual nerve
- 17 Mylohyoid nerve
- 18 Mental nerve
- 19 Facial artery
- 20 Submental artery
- 21 Mylohyoid artery
- 22 Inferior alveolar artery
- 23 Mental artery
- 24 Mental vein
- 25 Inferior alveolar vein
- 26 Mental foramen

- A Central incisor (only VE290/1001250) with approximal caries
- B Lateral incisor (only VE290/1001250) with approximal caries
- C Canine (only VE290/1001250) with caries in the neck of the tooth
- D First premolar (only VE290/1001250) with caries
- E Second premolar (only VE290/1001250) with fissure caries
- F First molar (only VE290/1001250) with caries profunda
- G Second molar (only VE290/1001250) with caries profunda complicata
- H Third molar (only VE290/1001250) with pulp polyp

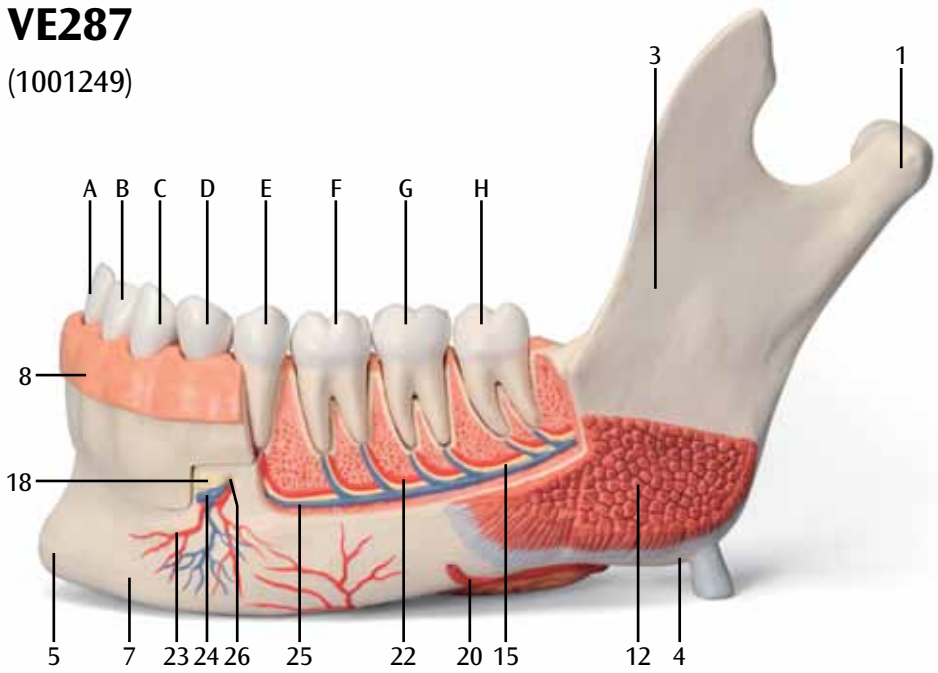
Additional incisor tooth

- 1 Crown of tooth
- 2 Neck of tooth
- 3 Root of tooth
- a Dental enamel
- b Dentin
- c Dental pulp
- d Cement



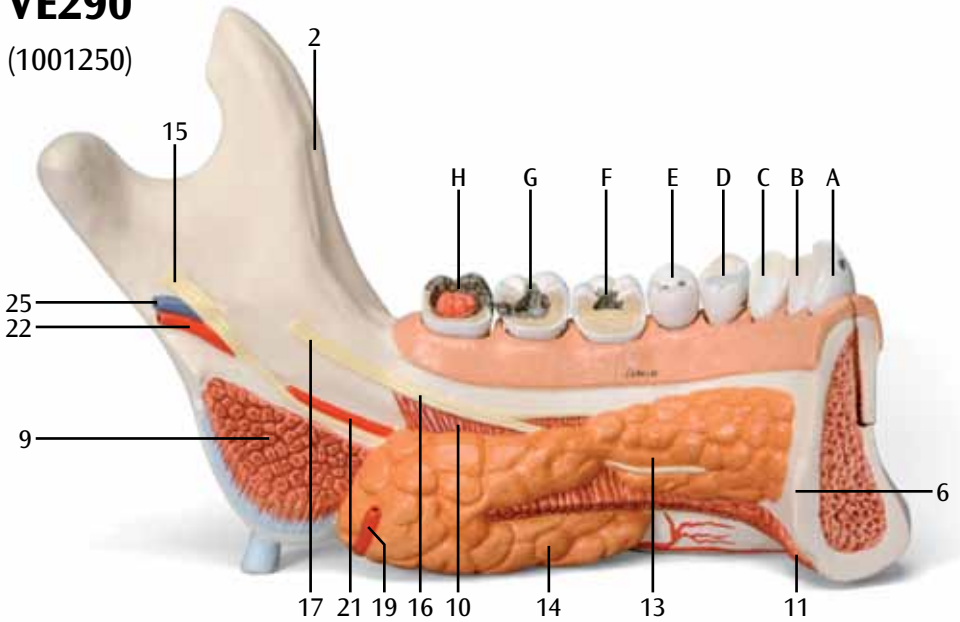
VE287

(1001249)



VE290

(1001250)





3B SCIENTIFIC® PRODUCTS