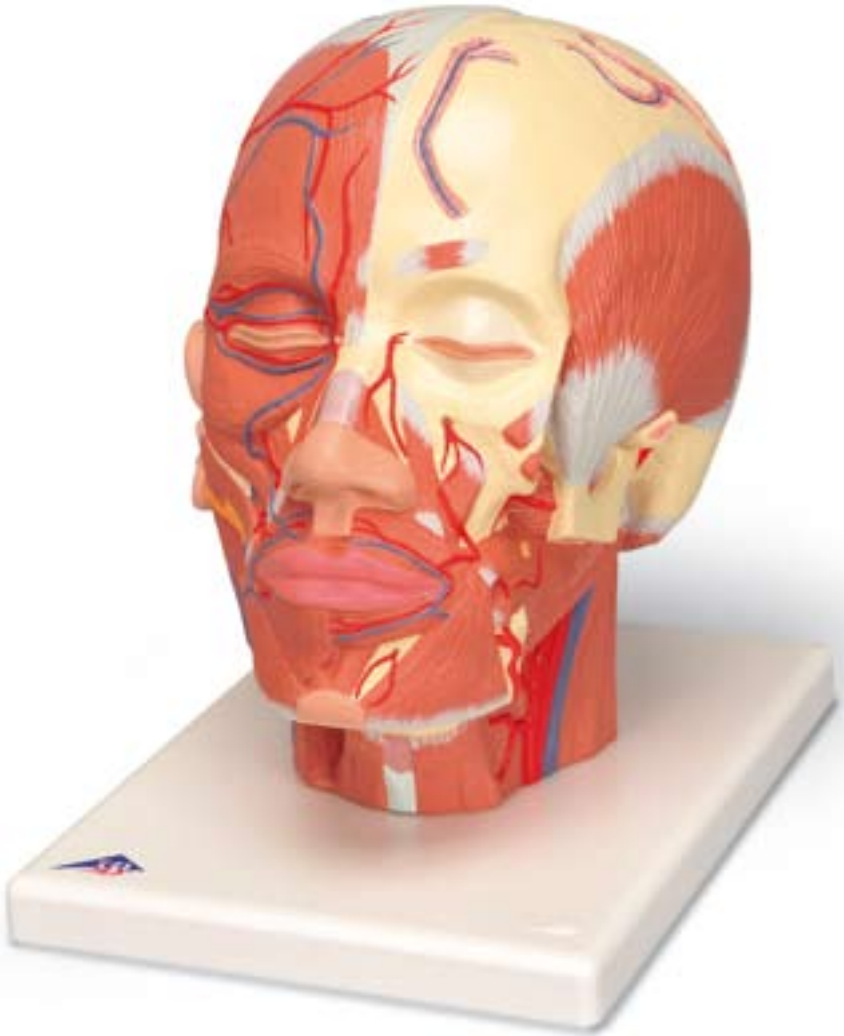




...going one step further



VB128

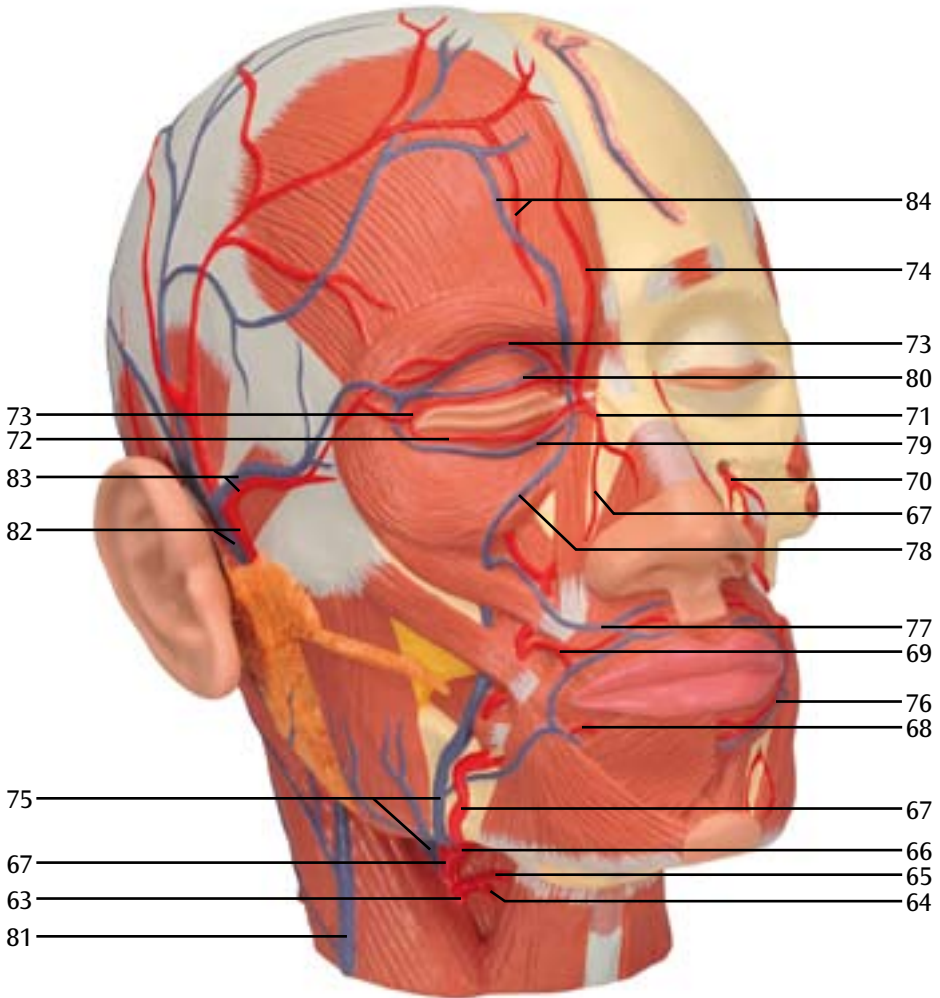
Head Musculature with Nerves

English

- 1 Occipitofrontalis muscle, frontal belly
- 2 Orbicularis oculi muscle
(sphincter muscle around the eye)
orbital part of frontal bone palpebral part
- 3 Procerus muscle (muscle of aggression)
- 4 Levator labii superioris alaeque nasi muscle
(elevator muscle of upper lip and wing of nose)
- 5 Transverse part of nasalis muscle
- 6 Levator labii superioris muscle (upper lip raiser)
- 7 Zygomaticus minor muscle
- 8 Zygomaticus major muscle
- 9 Risorius muscle
- 10 Orbicularis oris muscle
(sphincter muscle around the mouth)
- 11 Labii inferioris depressor muscle
(lower lip depressor)
- 12 Anguli oris depressor muscle
(lip corner depressor)
- 13 Chin muscle (chin raiser)
- 14 Buccinator muscle (dimpler)
- 15 Anterior auricular muscle
- 16 Superior auricular muscle
- 17 Posterior auricular muscle
- 18 Masseter muscle
- 19 Sternocleidomastoid muscle
- 20 Sternohyoideus muscle
- 21 Omohyoid muscle, superior belly
- 22 Mandible (lower jaw)
- 23 Parotid gland
- 24 Parotid duct
- 25 Levator anguli oris muscle (cheek puffer)
- 26 Corrugator supercilii muscle (frowning muscle)
- 27 Temporal muscle
- 28 Lateral pterygoid muscle
- 29 Medial pterygoid muscle
- 30 Splenius capitis muscle
- 31 Levator scapulae muscle
- 32 Posterior scalene muscle
- 33 Middle scalene muscles
- 34 Digastric muscle, posterior belly
- 35 Superior tarsal muscle
- 36 Inferior tarsal muscle
- 37 Medial palpebral ligament
- 38 Frontal bone
- 39 Parietal bone
- 40 Coronal suture
- 41 Infraorbital foramen
- 42 Mastoid process
- 43 External acoustic meatus
- 44 Zygomatic process
- 45 Stylohyoid muscle
- 46 Styloglossus muscle
- 47 Anterior scalene muscle
- 48 Mylohyoid muscle
- 49 Hyoglossus muscle
- 50 Digastric muscle, anterior belly
- 51 Hyoid bone
- 52 Thyroid cartilage
- 53 Thyrohyoid membrane
- 54 Submandibular gland
- 55 Auricle
- 56 Occipitofrontalis muscle, occipital belly
- 57 Trapezius muscle
- 58 Semispinalis capitis muscle
- 59 Galea aponeurotica (epicranial aponeurosis)
- 60 Occipital bone
- 61 Lambdoid suture
- 62 Sagittal suture
- 63 External carotid artery
- 64 Superior thyroid artery
- 65 Superior laryngeal artery
- 66 Lingual artery
- 67 Facial artery
- 68 Inferior labial artery
- 69 Superior labial artery
- 70 Infraorbital artery
- 71 Angular artery
- 72 Inferior palpebral arch
- 73 Superior palpebral arch
4 Supratrochlear artery
- 75 Facial vein
- 76 Inferior labial vein
- 77 Superior labial vein
- 78 Angular vein
- 79 Inferior palpebral vein
- 80 Superior palpebral vein
- 81 External jugular vein
- 82 Superficial temporal artery and vein
- 83 Transverse facial artery and vein
- 84 Supraorbital artery and vein
- 85 Common carotid artery
- 86 Internal carotid artery
- 87 Internal jugular vein
- 88 Superficial temporal artery
- 89 Maxillary artery
- 90 Buccal artery
- 91 Posterior superior alveolar artery
- 92 Inferior alveolar artery, mental branch
- 93 Frontal diploic vein
- 94 Submental artery
- 95 Sphenopalatine artery
- 96 Posterior auricular vein
- 97 Occipital artery
- 98 Occipital vein
- 99 Occipital diploic vein
- 100 Posterior temporal diploic vein

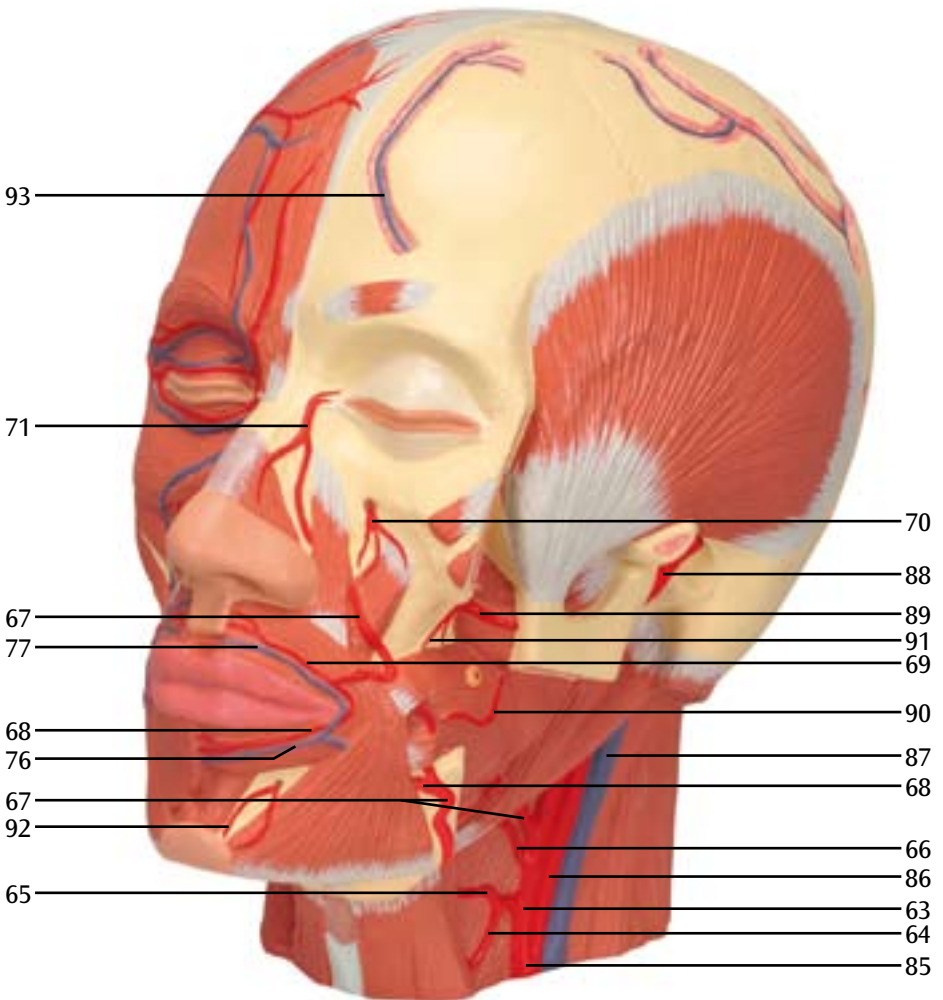
E

Blood vessels of the head, frontal view (right)
Blutgefäße des Kopfes, Ansicht von vorne rechts
Vasos sanguíneos de la cabeza, vista frontal derecha
Vaisseaux sanguins de la tête, vue avant droit
Vasos sanguíneos da cabeça, visão frontal direita
Vasi sanguigni del capo, visione anteriore destra
頭部の血管, 前面 (右側)
Кровеносные сосуды головы, вид спереди (справа)
头部血管, 前面观 (右側)



Blood vessels of the head, frontal view (left)
Blutgefäße des Kopfes, Ansicht von vorne links
Vasos sanguíneos de la cabeza, vista frontal izquierda
Vaisseaux sanguins de la tête, vue avant gauche
Vasos sanguíneos da cabeça, visão frontal esquerda
Vasi sanguigni del capo, visione anteriore sinistra
頭部の血管, 前面 (左側)

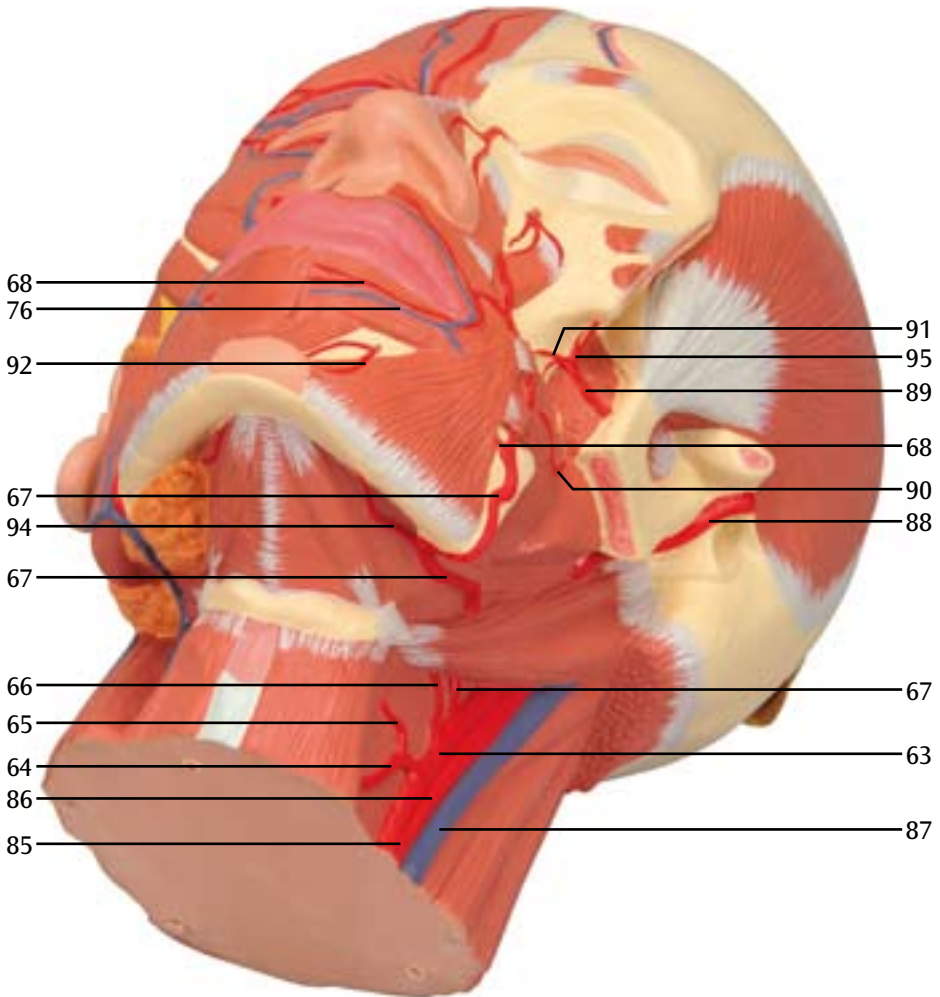
Кровеносные сосуды головы, вид спереди (слева)
 头部血管, 前面观 (左側)



G

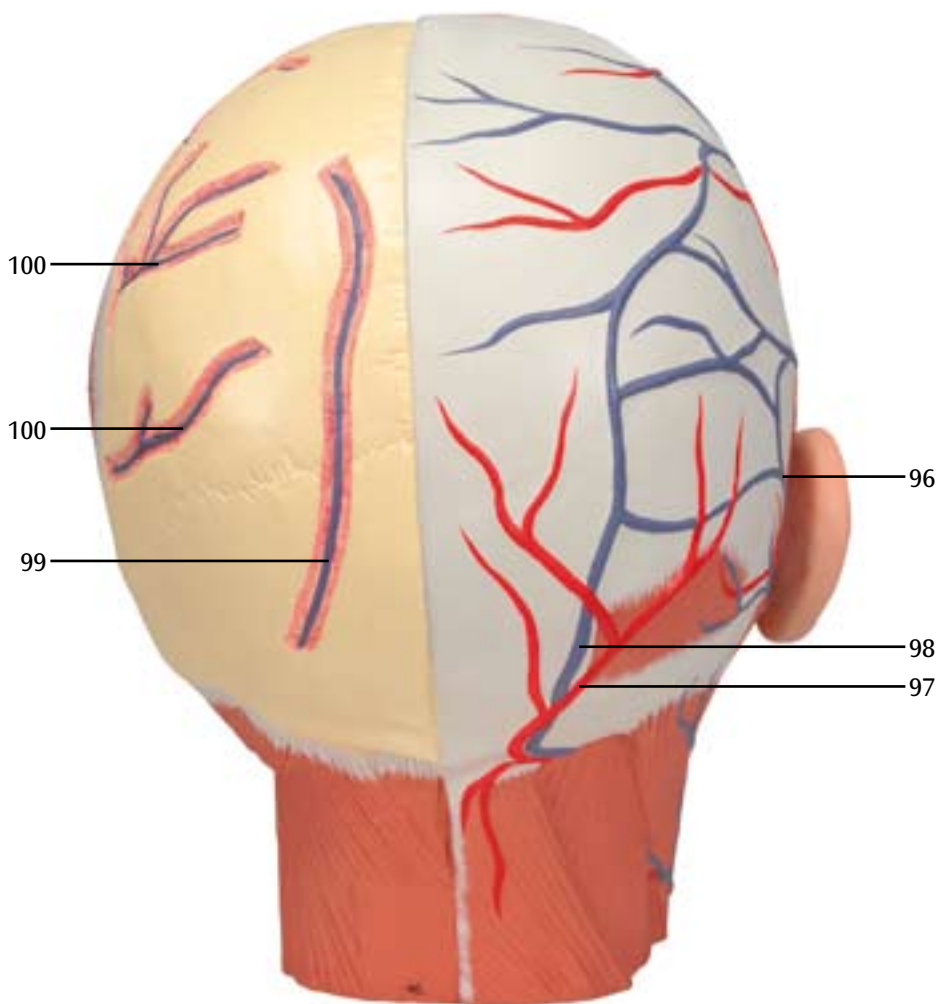
Blood vessels of the head, oblique view from below (left)
Blutgefäße des Kopfes, Ansicht von schräg unten links
Vasos sanguíneos de la cabeza, vista oblicua inferior izquierda
Vaisseaux sanguins de la tête, vue en biais en bas à gauche
Vasos sanguíneos da cabeça, visão transversal inferior esquerda
Vasi sanguigni del capo, visione trasversale inferiore sinistra
頭部の血管, 斜め下から (左側)

Кровеносные сосуды головы, вид сбоку и снизу (слева)
头部肌肉, 从下面的斜面观 (左侧)



Blood vessels of the head, rear view
Blutgefäße des Kopfes, Ansicht von hinten
Vasos sanguíneos de la cabeza, vista posterior
Vaisseaux sanguins de la tête, vue arrière
Vasos sanguíneos da cabeça, visão posterior
Vasi sanguigni del capo, visione posteriore
頭部の血管, 後面

Кровеносные сосуды головы, вид сзади
头部血管, 后面观





3B SCIENTIFIC® PRODUCTS